



# Factors Affecting the Outcome after Surgical Clipping of Ruptured Distal Anterior Cerebral Artery (DACA) Aneurysms

Gopal Raman Sharma<sup>1</sup> Prasanna Karki<sup>1</sup> Sumit Joshi<sup>1</sup> Prakash Paudel<sup>1</sup> Damber Bikram Shah<sup>1</sup>  
Pokharel Baburam<sup>1</sup> Gyawali Bidhan<sup>1</sup>

<sup>1</sup>Department of Neurosciences, Nepal Medicit Hospital, Lalitpur, Nepal

Address for correspondence Prasanna Karki, MD, PhD, Department of Neurosciences, Nepal Medicit Hospital, 44600, Sainbu, Lalitpur, Nepal (e-mail: prasannakarki7@gmail.com).

Asian J Neurosurg 2023;18:557–566.

## Abstract

**Objective** The purpose of this study is to assess demographic, clinical, and unique morphological characteristics of distal anterior cerebral artery (DACA) aneurysm. The relation of outcome included Glasgow Outcome Scale (GOS) using various independent variables, Hunt and Hess clinical grade (H&H), Miller Fischer grade, intraoperative rupture, and comparison of outcomes at discharge and last follow-up.

**Methods** Demographic data, aneurysm characteristics, and treatment outcomes were evaluated in 28 ruptured DACA aneurysms operated over a period of 13 years. Association between independent variables and dependent variables (GOS) at discharge and at last follow-up (13 years) was analyzed, and the interrelationship between these factors and outcome was evaluated. GOS was used to assess functional outcomes.

**Results** Over a period of 13 years, 500 patients harboring ruptured intracranial aneurysms were surgically clipped, and out of them 28 patients (5.6%) had ruptured DACA aneurysms. In this series, 20 (71.4%) patients had low grade and 8 (28.6%) had high grade H&H. Out of the 28 patients, 19 (67.8%) had good recovery, 6 (21.5%) were severely disabled, and 3 (10.7%) died at the time of discharge. On the last follow-up (13 years), smoking (*p*-value 0.03) and use of temporary clip (*p*-value 0.00) were significant predictors for unfavorable outcome.

**Conclusion** The results of our case series show that even with ruptured aneurysm excellent overall outcome after microsurgical clipping can be achieved, even though among cerebral aneurysms, DACA aneurysm is considered to have less favorable outcome. Alcohol consumption and use of temporary clip were the predictors for unfavorable outcome at the time of discharge. On the last follow-up, smoking and use of temporary clip were found to be the risk factors for unfavorable outcome. Although the small sample size of this study is a limitation, smoking and use of temporary clip play an important role on the overall outcome. The aim of this study was to analyze data to determine factors which may influence outcome after surgical clipping of ruptured DACA aneurysms.

## Keywords

- ▶ anterior circulation
- ▶ cerebral aneurysm
- ▶ microsurgical clipping
- ▶ Hunt and Hess grade
- ▶ functional outcome

article published online  
September 22, 2023

DOI <https://doi.org/10.1055/s-0043-1771371>.  
ISSN 2248-9614.

© 2023. Asian Congress of Neurological Surgeons. All rights reserved.

This is an open access article published by Thieme under the terms of the Creative Commons Attribution-NonDerivative-NonCommercial-License, permitting copying and reproduction so long as the original work is given appropriate credit. Contents may not be used for commercial purposes, or adapted, remixed, transformed or built upon. (<https://creativecommons.org/licenses/by-nc-nd/4.0/>)

Thieme Medical and Scientific Publishers Pvt. Ltd., A-12, 2nd Floor, Sector 2, Noida-201301 UP, India

## Introduction

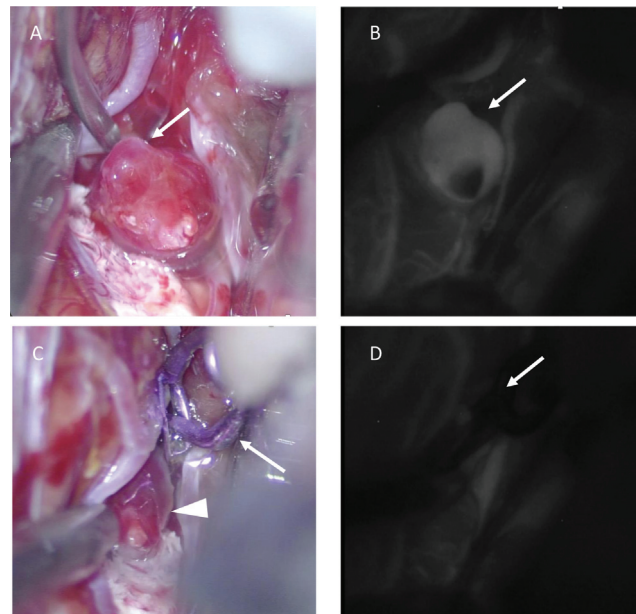
Intracranial aneurysm originating from the A2 to A5 segments of the anterior cerebral artery (ACA) and their peripheral branches is regarded as distal ACA (DACA) aneurysm. These aneurysms are rare as compared with other anterior circulation aneurysms. The incidence is estimated to be approximately 1 to 9% of all intracranial aneurysms.<sup>1-6</sup> DACA aneurysms are unique in terms of their incidence, clinical presentation, location, morphology, and treatment outcome.<sup>7,8</sup>

There are two modalities of treatment of ruptured DACA aneurysm and they are surgical clipping or endovascular procedure and occasionally combination of both. Surgery is considered to be the best treatment for ruptured DACA aneurysms due to the peripheral location of aneurysm, small size of the fundus, broad base neck of the aneurysm, and mostly associated with intraparenchymal hematoma.<sup>2,9-11</sup> However, treatment paradigm has been gradually shifting to endovascular procedure due to its rapid technological advancement and skill development.<sup>6,12-18</sup> Whatever treatment we choose for ruptured DACA aneurysms, outcome after intervention is less favorable than outcome of other anterior circulation aneurysms.<sup>1,7,11</sup> The aim of this study is to analyze the data and to determine factors which may influence outcome after surgical clipping of ruptured DACA aneurysms.

## Material and Methods

This was a prospectively collected retrospective study of 28 patients harboring ruptured DACA aneurysms and operated over a period of 13 years (from January 2007 to April 2020) at different institutes. Unruptured DACA aneurysms, aneurysms of other location, and defaulters were excluded from this study. Some of the example cases are illustrated in ►Figs. 1A-B, 2A-D, and 3A-C.

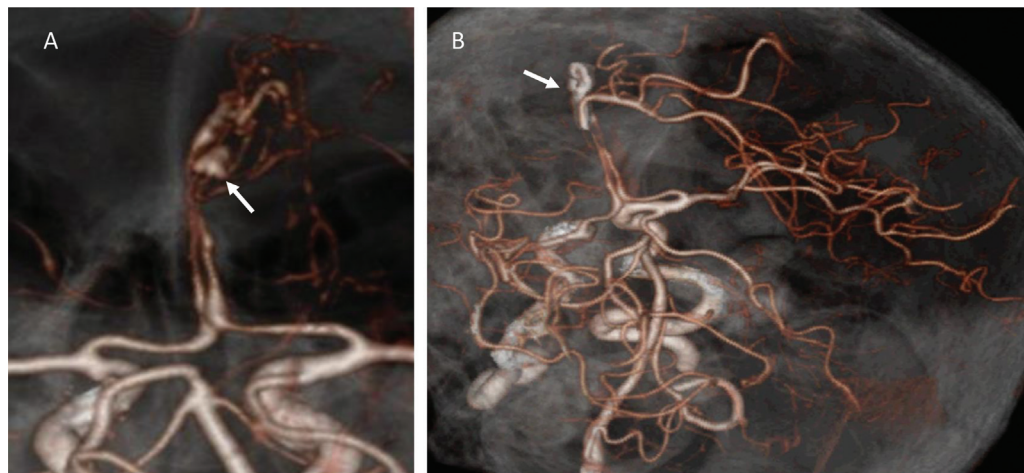
Patients' demography, clinical and radiological information, surgical notes, and follow-up information were



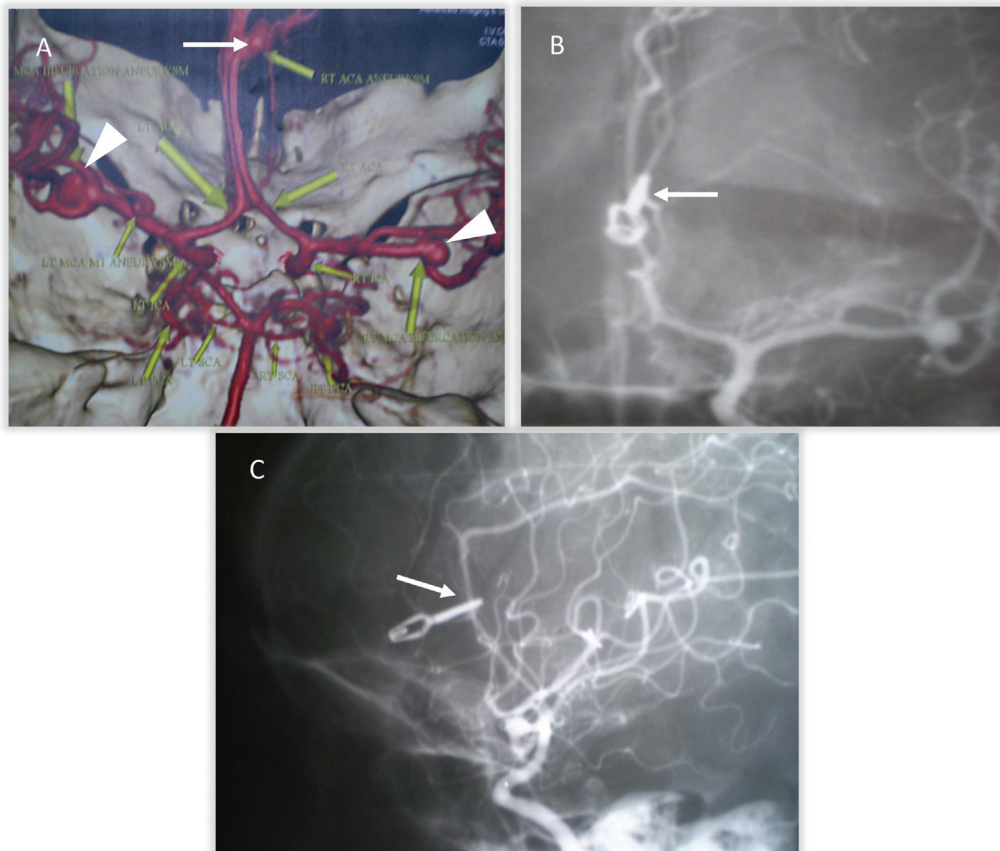
**Fig. 2** (A) Intraoperative images of pericallosal aneurysm dome (arrow) after exposure by interhemispheric approach. (B) An image after intraoperative injection of indocyanine green (ICG), the dome of an aneurysm glowing (arrow). (C) Postaneurysm clipping, the clip is visible indicated by an arrow and dome indicated by an arrowhead. (D) Postclipping indocyanine green (ICG) demonstrating absence of blood flow to the dome of an aneurysm (arrow).

retrieved from the outpatient department and inpatient department registers after receiving consent from the Institutional Review Committee and was conducted in accordance with the institutional ethics guidelines.

In this study, independent variables including age, sex, race, hypertension (HTN), diabetes mellitus (DM), smoking, alcohol consumption, size of the aneurysm, size of the neck, Hunt and Hess clinical grade (H&H), Miller Fischer grade (MFG), types of surgery, use of temporary clip, use of brain refractor, and intraoperative rupture (IOR) were identified and analyzed. H&H clinical grade was dichotomized into low



**Fig. 1** (A) Preoperative computed tomography angiogram (CTA) showing ruptured left pericallosal aneurysm (arrow). (B) Postoperative computed tomography angiogram (CTA) showing aneurysm clip (arrow) completely obliterating the aneurysm neck with no residual sac.



**Fig. 3** (A) Preoperative computed tomography angiogram (CTA) showing multiple unruptured incidental aneurysms at bifurcation of right and left middle cerebral arteries (*white arrowheads*) and ruptured right pericallosal aneurysm (*white arrow*). (B) Postoperative digital subtraction angiogram (DSA) anteroposterior view showing aneurysm clip (*arrow*) completely obliterating the aneurysm neck with no residual sac. (C) Postoperative digital subtraction angiogram (DSA) lateral view showing aneurysm clip (*arrow*) completely obliterating the aneurysm neck with no residual sac.

grade (1–3) and high grade (4–5). Likewise, MFG was categorized into low grade (0–2) and high grade (3–4) and GOS into favorable (4–5) and unfavorable (1–3) outcome, respectively.

Association between independent variables and dependent variables (GOS) at discharge and at last follow-up (13 years) was analyzed and tried to discover whether there was any interrelationship between these factors and outcome. Intraoperative indocyanine green and transcranial Doppler (TCD) were used in all cases. Postoperative cerebral computed tomography (CT) angiography or digital subtraction angiogram were performed in all cases to identify the degree of neck occlusion and vasospasm. Follow-up period ranged from 3 to 13 years. Statistical analysis was executed applying SPSS (25) for Windows using the chi-square test. The type I error was set as *p*-value 0.05.

## Results

Over a period of 13 years 500 patients harboring ruptured intracranial aneurysms were surgically clipped, and out of them 28 patients (5.6%) had ruptured DACA aneurysms. These 28 patients were subject of this retrospective study as shown in ►Table 1.

## Patients' Characteristics

Out of the 28 patients, 22 (78.6%) were Aryan and 6 (21.4%) were Mongol. There were 21 (75%) females and 7 (25%) males. Age distribution was categorized into less than 40 and more than 40 years, and this study revealed that 2 patients (7.1%) were below 40 years and 26 (92.9%) were above 40 years. Mean age was  $54.75 \pm 11.74$  years. Comorbidities like HTN, DM, smoking, and alcohol consumption were identified and analyzed. Twenty-two (78%) patients were hypertensive, 6 (21.5%) were diabetic, 9 (32.1%) were smokers, and 4 (14.3%) were alcohol consumers (►Table 1).

## Clinical Demography

Common clinical presentations were severe headache, vomiting, altered level of consciousness, focal deficits, and seizure. In this series, 20 (71.4%) patients had low-grade and 8 (28.6%) had high-grade H&H (►Table 1).

## CT Scan Findings

CT scan of the brain of these patients showed that 2 (7.1%) had normal findings, 25 (89.3%) had subarachnoid hemorrhage, 16 (57.1%) had intracerebral hematomas (ICHs), 3 (10.7%) had intraventricular hemorrhage (IVH), and 3 (10.7%) had hydrocephalus. In this series, 6 (21.4%) had low and 22 (78.6%) high MFG (►Tables 1 and 2).

**Table 1** Demographic, clinical, and radiological characteristics of 28 patients who underwent of DACA aneurysms surgery

Variables		Number	Percentage
DACA aneurysms	Total no. of ruptured DACA aneurysms	28	5.6
	Total no. of ruptured cerebral aneurysms	500	
Race	Aryan	22	78.6
	Mongol	6	21.4
	Total	28	100
Age	40 and above	26	92.9
	Below 40	2	7.1
	Total	28	100
Mean age	54.75 (standard deviation 11.74 years)		
Sex	Male	7	25
	Female	21	75
	Total	28	100
Hypertension	Yes	22	78
	No	6	22
	Total	28	100
Diabetes	Yes	6	21.4
	No	22	78.6
	Total	28	100
Alcohol	Yes	4	14.3
	No	24	85.7
	Total	28	100
Smoking	Yes	9	32.1
	No	19	67.9
	Total	28	100
Hunt and Hess clinical grade	1–3 (low grade)	20	71.4
	4–5 (high grade)	8	28.6
	Total	28	100
Miller Fischer grade	0–2 (low grade)	6	21.4
	3–4 (high grade)	22	78.6
	Total	28	100
Aneurysm size	> 3 mm	5	17.9
	3–10 mm	20	71.4
	< 10 mm	3	10.7
	Total	28	100
Neck size	> 3 mm	21	75
	< 3 mm	7	25
	Total	28	100
Types of surgery	Emergency	14	50
	Elective	14	50
	Total	28	100

Abbreviation: DACA, distal anterior cerebral artery.

**Aneurysm Characteristics**

All DACA aneurysms were saccular and 25 aneurysms (90%) were located at the pericallosal–callosomarginal junction

and only 3 aneurysms (10%) were located distal (A4–5) to it. There were 3 (10%) associated aneurysms in other locations. Regarding the size of the fundus, 5 (17.9%) aneurysms



**Table 2** Findings of CT scan of brain

Findings	Number	Percentage
SAH	25	89.3
ICH	16	57.1
IVH	3	10.7
Hydrocephalus	4	14.3
Vasospasm	7	25
Normal	2	7.1

Abbreviations: CT, computed tomography; ICH, intracerebral hematoma; IVH, intraventricular hemorrhage; SAH, subarachnoid hemorrhage.

were less than 3 mm, 20 (71.4%) aneurysms were 3 to 10 mm, and 3 (10.7%) aneurysms were greater than 10 mm in size. Size of the neck was grouped into less than 3 mm and greater than 3 mm; 21 (75%) aneurysms had a neck size of less than 3 mm and 7 (25%) had greater than 3 mm (►Table 1).

**Surgery**

Emergency surgery was performed on 14 (50%) patients who had compromised Glasgow Coma Score (GCS) with ICH on CT scan and underwent clipping of aneurysms and evacuation of hematoma at the same sitting. Elective clipping was performed on 14 (50%) patients who had full GCS.

Bicoronal skin incision with right frontal craniotomy and anterior interhemispheric approach was opted in all the cases except three patients who had aneurysms at the A4–5 segment of ACA. These three patients were approached via frontal parasagittal craniotomy and interhemispheric trajectory.

Brain retractor was used in 22 (78.6%) and not used in 6 (21.4%) cases. Temporary clips were applied in 6 cases (21.4%) during neck dissection and/or permanent clip application and the clipping time was 3 to 5 minutes. IOR occurred in 2 (7.1%) patients; one had sac tear during clipping and other one had neck tear during fundus dissection (►Table 3).

**Postoperative Complications**

Surgery-related complications were diabetes insipidus in 9 (32.1%), delayed ischemic neurological deficit (DIND) in 5

(17.9%), pseudomeningocele in 1 (3.6%), hydrocephalus in 1 (3.6%), ICH in 5 (17.8%), and chest infection in 1 (3.6%) (►Table 4).

**Surgical Outcome**

Out of 28 patients, 19 (67.8%) had good recovery, 6 (21.5%) were severely disabled, and 3 (10.7%) died at the time of discharge. On the last follow-up (13 years), 24 (85.7%) patients had favorable outcome and 4 (14.3%) patients had unfavorable outcome (►Tables 3 and 5).

On the first follow-up, statistical analysis did not reveal association between GOS and age, sex, race, HTN, smoking, size of the fundus, neck size, H&H grade, MFG, type of surgery, IOR, and use of brain retractor. However, alcohol consumption (*p*-value 0.04) and use of temporary clip (*p*-value 0.00) had unfavorable outcome, which were statistically significant (►Table 3). However, on the last follow-up (13 years), smoking (*p*-value 0.03) and use of temporary clip (*p*-value 0.00) were significant predictors for unfavorable outcome (►Table 5).

**Discussion**

DACA aneurysms are those aneurysms which originate at the A2 to A5 segments of ACA and their distal branches. A2 segment starts from the anterior communicating artery. Majority of DACA aneurysms are located at the pericallosal and callosomarginal junction and the remaining few aneurysms are located at the frontopolar origin and/or distal (A4–A5) to the pericallosal and callosomarginal junction.<sup>1,2,8,9,19</sup> DACA aneurysms are comparatively rarer than other anterior circulation aneurysms and its incidence has been recorded as 1 to 9% in the literature.<sup>1–6</sup> Incidence of DACA aneurysms in our series was 5.6% which is indistinguishable with the findings of other published case series. DACA aneurysm has some peculiarities than other anterior circulation aneurysm, which are being fragile, small size dome, wide neck, broad-based origin, peripheral, and interhemispheric location.<sup>7,8</sup>

Treatment for ruptured DACA aneurysm is either microsurgical clipping or endovascular procedure. Sugar and

**Table 3** Association of independent variables with dependent variables (GOS) at the time of discharge

Independent variables	GOS (dependent variable)			<i>p</i> -Value
	1–3	4–5	Total	
Age	< 40	1	1	0.575
	> 40	8	18	
	Total	9	19	
Sex	Male	3	4	0.483
	Female	6	15	
	Total	9	19	
Race	Aryan	6	16	0.29
	Mongol	3	3	
	Total	9	19	

(Continued)

**Table 3** (Continued)

Independent variables		GOS (dependent variable)			p-Value
		1-3	4-5	Total	0.575
Comorbidities					
HTN	Yes	8	14	22	0.36
	No	1	5	6	
	Total	9	19	28	
DM	Yes	1	5	6	0.36
	No	8	14	22	
	Total	9	19	28	
Alcohol	Yes	3	1	4	0.04
	No	6	18	24	
	Total	9	19	28	
Smoking	Yes	6	3	9	0.07
	No	3	16	19	
	Total	9	19	28	
Association of aneurysm					
Size of aneurysm	< 3 (mm)	1	4	5	0.80
	> 3-10 (mm)	7	13	20	
	> 10 (mm)	1	2	3	
	Total	9	19	28	
Size of aneurysm neck	< 3 (mm)	5	16	21	0.16
	> 3 (mm)	4	3	7	
	Total	9	19	28	
Hunt and Hess grade	1-3	5	15	20	0.20
	4-5	4	4	8	
	Total	9	19	28	
MF grading	0-2	1	5	6	0.35
	3-4	8	14	22	
	Total	9	19	28	
Types of surgery	Elective	4	10	14	0.50
	Emergency	5	9	14	
	Total	9	19	28	
Use of temporary clip	Yes	5	1	6	0.00
	No	4	18	22	
	Total	9	19	28	
Duration of temporary clip application	< 4 min	2	1	3	0.07
	> 4 min	3	0	3	
	Not applied	4	18	22	
	Total	9	19	28	
Use of retractor	Yes	9	13	22	0.072
	No	0	6	6	
	Total	9	19	28	
IOR	Yes	2	0	2	0.95
	No	7	19	26	
	Total	9	19	28	

Abbreviations: DM, diabetes mellitus; GOS, Glasgow Outcome Scale; HTN, hypertension; IOR, intraoperative rupture; MF, Miller Fischer.

**Table 4** Postoperative complications

Complications	Number	Percentage
Diabetes insipidus (DI)	9	32.1
Delayed ischemic neurological deficit (DIND)	5	17.9
Chest infection	1	3.6
Pseudomeningocele	5	17.8
Hydrocephalus	1	3.6
Total	21	75

Tinsley<sup>20</sup> were given credit for first direct clipping of DACA aneurysm in 1948, and then in 1974, Yasargil and Carter<sup>21</sup> reported on DACA aneurysm surgery in detail.<sup>8</sup>

Microsurgical clipping of DACA aneurysm is an old, time-tested, reliable procedure having a good result; however, results are not as favorable as anterior circulation aneurysm surgery.<sup>1,4,7,14</sup> These days endovascular technique, which has been flourishing day by day, is equally effective for the treatment of ruptured DACA aneurysm.<sup>12-14,16-18,22</sup> Truly speaking, DACA aneurysms are difficult to treat either by surgery or endovascular procedures due to their fragility, small-sized dome, wide neck, broad-based origin, and peripheral location. Many recent studies have shown similar results of both procedures.<sup>1,11,14,23,24</sup>

**Table 5** Association of independent variables with dependent variables (GOS) at last follow-up (13 years)

Independent variables		Dependent variable (GOS)			p-Value
		1-3	4-5	Total	
Age	< 40	0	4	4	0.50
	> 40	4	20	24	
	Total	4	24	28	
Sex	Male	2	4	6	0.398
	Female	2	20	22	
	Total	4	24	28	
Race	Aryan	4	21	25	0.28
	Mongol	0	3	3	
	Total	4	24	28	
Comorbidities					
HTN	Yes	3	19	22	0.35
	No	1	5	6	
	Total	4	24	28	
DM	Yes	0	6	6	0.35
	No	4	19	22	
	Total	4	24	28	
Alcohol	Yes	2	2	4	0.08
	No	2	22	24	
	Total	4	24	28	
Smoking	Yes	3	6	9	0.03
	No	1	18	19	
	Total	4	24	28	
Association of aneurysm					
Size of aneurysm	< 3 (mm)	0	5	5	0.8
	> 3-10 (mm)	2	18	20	
	> 10 (mm)	2	1	3	
	Total	4	24	28	
Size of aneurysm neck	< 3 (mm)	2	19	21	0.12
	> 3 (mm)	2	5	7	
	Total	4	24	28	

(Continued)

**Table 5** (Continued)

Independent variables		Dependent variable (GOS)			p-Value
		1-3	4-5	Total	
Hunt and Hess grade	1-3	2	18	20	0.20
	4-5	2	6	8	
	Total	4	24	28	
MF grading	0-2	1	5	6	0.35
	3-4	3	19	22	
	Total	9	24	28	
Types of surgery	Elective	1	13	14	0.50
	Emergency	3	11	14	
	Total	4	24	28	
Use of temporary clip	Yes	4	2	6	0.00
	No	0	22	22	
	Total	4	24	28	
Duration of temporary clip application	< 4 min	1	1	2	0.07
	> 4 min	2	6	8	
	Not applied	1	17	18	
	Total	4	24	28	
Use of retractor	Yes	4	18	22	0.357
	No	0	6	6	
	Total	4	24	28	
IOR	Yes	2	0	2	0.016
	No	2	24	26	
	Total	4	24	28	

Abbreviations: DM, diabetes mellitus; GOS, Glasgow Outcome Scale; HTN, hypertension; IOR, intraoperative rupture; MF, Miller Fischer.

The incidence of ICH-related DACA aneurysms are approximately 40 to 70%,<sup>1,5,7-9</sup> and those DACA aneurysms are best treated by surgical evacuation of ICH and clipping of aneurysms at the same sitting. In our study, ruptured DACA aneurysm was associated with 57.1% ICH. We clipped most of the DACA aneurysms via right-sided frontal craniotomy and interhemispheric approach; however, bifrontal basal interhemispheric and minianterior interhemispheric approaches have been described in the literature.<sup>7,23</sup> Rarely, pterional approach for A2 segment and unilateral frontal parasagittal approach for A4-5 segment DACA aneurysm is adopted.<sup>2,9</sup>

There are many known factors which affect the outcome of DACA aneurysms after surgical intervention, but there is sparsity of publication on these issues.<sup>1,2,4,9,16,25</sup> High H&H and MF grades, ICH, IVH, hydrocephalus, IOR, timing of surgery, and advanced age have been attributed for poor outcome after intervention.<sup>1,9,10,25</sup> Furtado et al found poor clinical grade on admission and initial ICH as a risk factor for poor prognosis.<sup>1</sup> Similarly, Lee et al and Miyazawa et al had correlated poor prognosis of their patients to preoperative H&H clinical grade.<sup>10,25</sup> Miyazawa et al also revealed that the timing of surgery and ICH of more than 3 cm were risk factors for unfavorable outcome<sup>10</sup>; however, in our series there was no link between these two factors (H&H clinical grade and ICH)

and outcomes of our patients. In a series of 59 patients Steven et al found ICH in 28% patients and all of them carried a poor prognosis.<sup>4</sup>

In 2008, Lehecka et al published the largest series of 277 patients of DACA aneurysm surgery and identified that advanced age, poor clinical grade, ICH, IVH, hydrocephalus, and rebleeding before treatment as factors predicting unfavorable outcome.<sup>9</sup> Arslan and Istemen experienced similar experience with their 20 cases of DACA aneurysm surgery.<sup>19</sup>

In this study, we were focused to find out the association of independent variables such as age, sex, race, HTN, DM, alcohol consumption, smoking, size of the fundus, size of the neck, H&H grade, MFG, types of surgery, use of temporary, duration of temporary clip application, use of brain retractor, and IOR to GOS (dependent variable) and to determine whether these independent variables have any impact on outcome after DACA aneurysm clipping at the time of discharge and as well as at last follow-up (13 years). Our study showed that at the time of discharge GOS was influenced by alcohol consumption (*p*-value 0.04) and use of temporary clip (*p*-value 0.00) and their outcome were unfavorable; however, at last the follow-up (13 years) smoking (*p*-value 0.03) and use of temporary clip (*p*-value 0.00) were risk factors for poor outcome which were statistically



significant. Other factors like age, sex, race, DM, size of the fundus, neck size, H&H grade, surgery time, duration of temporary clip application, IOR, and use of brain retractor did not change the outcome course of patients after intervention. Presence of ICH also did not influence outcome and there was no statically significant difference between these two groups. In our series, there were three cases with IVH with four hydrocephalus among which only one symptomatic patient required ventriculoperitoneal shunt.

Predicting factors such as the use of temporary clip, alcohol consumption, and smoking in relation to outcome (GOS) of DACA aneurysm surgery were not studied before. However, one study has demonstrated an increase in rupture risk of small intracranial aneurysm of anterior circulation (< 7 mm) in patient taking alcohol, further explaining the cause to be an ethanol-induced endothelial damage causing inflammation and rupture.<sup>26</sup> It has also been reported that smoking induces an inflammatory response and proinflammatory phenotypic modulation of vascular smooth muscle cells and subsequently increases the degeneration of the extracellular matrix, and affects aneurysm formation.<sup>27,28</sup> This extent of damage in our hypothesis might play an important role in relation between unfavorable outcome with alcohol use and smoking. Outcome of microsurgical clipping of DACA aneurysms is not as favorable as clipping of other anterior circulation aneurysms. Favorable outcome of DACA aneurysm surgery ranged from 65 to 94%.<sup>1,3,9,24</sup> Lee et al with a case series of 20 DACA aneurysms had 85% favorable outcome,<sup>3</sup> and in Otani et al's series of 20 cases only 70% had favorable outcome.<sup>24</sup> In Lee et al's series of 126 cases, 94% had favorable outcome.<sup>25</sup> In Lehecka et al's series of 277 cases, favorable outcome was achieved in 74%.<sup>9</sup>

In our series, only 19 patients (67.8%) had favorable outcome, 6 patients (21.5%) were severely disabled, and 3 patients (10.7%) died. Though our results are comparable with the outcome of others published series, this outcome was not up to the desired level and this could be attributed to that all patients in our series had ruptured aneurysms and most of the published reports had series of ruptured and unruptured DACA aneurysms. Our study has shown increasing trend of improvement on outcome at subsequent follow-up. On the last follow-up (13 years), 24 patients (86%) had favorable outcome and 4 patients (14%) had unfavorable outcome which were comparable with outcome of previously published series.

## Limitations

This study has many limitations. This is a retrospective, observational, single-centered study and the studied population was small. Though randomized controlled trial is not possible in such type of study, a multicenter large cohort population study with meta-analysis is recommended in the future to acquire more accurate information.

## Conclusion

Outcome of ruptured DACA aneurysm surgery was less favorable than other anterior circulation aneurysm surgery. How-

ever, there was increasing trend of improvement on outcome at subsequent follow-up. Alcohol consumption and use of temporary clip were the predictors for unfavorable outcome at the time of discharge. On the last follow-up, smoking and use of temporary clip were the risk factors for unfavorable outcome.

## Conflict of Interest

None declared.

## References

- Furtado SV, Jayakumar D, Perikal PJ, Mohan D. Contemporary management of distal anterior cerebral artery aneurysm; a dual-trained neurosurgeon's perspective. *J Neurosci Rural Pract* 2021; 12(04):711-717
- Shukla D, Bhat DI, Srinivas D, et al. Microsurgical treatment of distal anterior cerebral artery aneurysms: a 25 year institutional experience. *Neurol India* 2016;64(06):1204-1209
- Lee JW, Lee KC, Kim YB, Huh SK. Surgery for distal anterior cerebral artery aneurysms. *Surg Neurol* 2008;70(02):153-159, discussion 159
- Steven DA, Lownie SP, Ferguson GG. Aneurysms of the distal anterior cerebral artery: results in 59 consecutively managed patients. *Neurosurgery* 2007;60(02):227-233, discussion 234
- Proust F, Toussaint P, Hannequin D, Rabenenoïna C, Le Gars D, Fréger P. Outcome in 43 patients with distal anterior cerebral artery aneurysms. *Stroke* 1997;28(12):2405-2409
- Bonadio LE, Mello LRG, Boer VHT, et al. Pericallosal aneurysms: effectiveness of endovascular management. *Arg Bras Neurocir* 2017;36:7-13
- Orz Y. Surgical strategies and outcomes for distal anterior cerebral arteries aneurysms. *Asian J Neurosurg* 2011;6(01):13-17
- Narang S, Dil JS, Raja A. Distal anterior cerebral artery aneurysms: a brief review. *J Cerebrovasc Sci* 2022;10:35-40
- Lehecka M, Lehto H, Niemelä M, et al. Distal anterior cerebral artery aneurysms: treatment and outcome analysis of 501 patients. *Neurosurgery* 2008;62(03):590-601, discussion 590-601
- Miyazawa N, Nukui H, Yagi S, et al. Statistical analysis of factors affecting the outcome of patients with ruptured distal anterior cerebral artery aneurysms. *Acta Neurochir (Wien)* 2000;142(11):1241-1246(Wien)
- Pandey A, Rosenwasser RH, Veznedaroglu E. Management of distal anterior cerebral artery aneurysms: a single institution retrospective analysis (1997-2005). *Neurosurgery* 2007;61(05):909-916, discussion 916-917
- Liao L, Derelle AL, Merlot I, et al. Endovascular treatment of distal anterior cerebral artery aneurysms: long-term results. *J Neuro-radiol* 2020;47(01):33-37
- Vora N, Thomas AJ, Gupta R, et al. Endovascular treatment of distal anterior cerebral artery aneurysms: technical results and review of the literature. *J Neuroimaging* 2010;20(01):70-73
- Sturiale CL, Brinjikji W, Murad MH, Cloft HJ, Kallmes DF, Lanzino G. Endovascular treatment of distal anterior cerebral artery aneurysms: single-center experience and a systematic review. *AJNR Am J Neuroradiol* 2013;34(12):2317-2320
- Menovsky T, van Rooij WJ, Sluzewski M, Wijndal D. Coiling of ruptured pericallosal artery aneurysms. *Neurosurgery* 2002;50(01):11-14, discussion 14-15
- Ko JK, Kim HS, Choi HJ, Lee TH, Yun EY, Choi CH. Endovascular treatment of ruptured pericallosal artery aneurysm. *J Korean Neurosurg Soc* 2015;58(03):197-204
- Suzuki K, Yatomi K, Yamamoto M, et al. Endovascular therapy of distal anterior cerebral artery aneurysms: single institute clinical experience with 47 patients (49 aneurysms). *J Neuroendovasc Therapy* 2019;13:329-335

- 18 Husain S, Andhitara Y, Jena SP, Padilla J, Aritonang S, Letsoin I. Endovascular management of ruptured distal anterior cerebral artery aneurysm; a retrospective review study. *World Neurosurg* 2017;107:588–596
- 19 Arslan A, Istemen I. Surgical strategies of distal anterior cerebral artery aneurysms. *Haydarpasa Numune Med J* 2020;62(03):248–252
- 20 Sugar O, Tinsley M. Aneurysm of terminal portion of anterior cerebral artery. *Arch Neuropsych* 1948;60(01):81–85
- 21 Yaşargil MG, Carter LP. Saccular aneurysms of the distal anterior cerebral artery. *Journal of Neurosurgery* 1974;40(02):218–223
- 22 Porto GBF, Al Kasab S, Sattur MG, et al. Endovascular management of distal anterior cerebral artery aneurysms: a multicenter retrospective review. *World Neurosurg* 2021;154:e421–e427
- 23 Monroy-Sosa A, Nathal E, Rhoton AL Jr. Operative management of distal anterior cerebral artery aneurysms through a mini anterior interhemispheric approach. *World Neurosurg* 2017;108:519–528
- 24 Otani N, Takasato Y, Masaoka H, et al. Clinical features and surgical outcomes of ruptured distal anterior cerebral artery aneurysms in 20 consecutively managed patients. *J Clin Neurosci* 2009;16(06):802–806
- 25 Lee JY, Kim MK, Cho BM, Park SH, Oh SM. Surgical experience of the ruptured distal anterior cerebral artery aneurysms. *J Korean Neurosurg Soc* 2007;42(04):281–285
- 26 Dinger TF, Peschke J, Chihi M, et al. Small intracranial aneurysms of the anterior circulation: a negligible risk? *Eur J Neurol* 2023;30(02):389–398
- 27 Chalouhi N, Ali MS, Starke RM, et al. Cigarette smoke and inflammation: role in cerebral aneurysm formation and rupture. *Mediators Inflamm* 2012;27:1582
- 28 Aoki T, Kataoka H, Shimamura M, et al. NF-kappaB is a key mediator of cerebral aneurysm formation. *Circulation* 2007;116(24):2830–2840