




# Anatomical Justification of Extradural Resection of the Anterior Clinoid Process

Albert A. Sufianov<sup>1,2,3,4</sup>  Iurii A. Iakimov<sup>2</sup> Nargiza A. Garifullina<sup>1</sup> Rinat A. Sufianov<sup>1</sup>  
Roman V. Kovalenko<sup>2</sup> Idrisdzhoni A. Kosimzoda<sup>2</sup>

<sup>1</sup>Department of Nerosurgery, I.M. Sechenov, First Moscow State Medical University (Sechenov University), Moscow, Russian Federation

<sup>2</sup>Department of Neurosurgery, Federal Centre of Neurosurgery, Ministry of Health of the Russian Federation, City of Tyumen, Russian Federation

<sup>3</sup>Department of Neurosurgery, Peoples' Friendship University of Russia (RUDN University), Moscow, Russian Federation

Address for correspondence Albert A. Sufianov, DSc (Med), Department of Neurosurgery, Federal Centre of Neurosurgery of the Ministry of Health of the Russian Federation, 4 km Chervishevskogo Trakta Street, Building 5, Tyumen, 625032, Russia (e-mail: sufianov@gmail.com).

<sup>4</sup>Department of Neurosurgery, King Edward Medical University (KEMU), Lahore, Pakistan

Asian J Neurosurg 2023;18:573–580.

## Abstract

**Objective** The study aimed to provide neuroanatomical justification of the extradural resection of the anterior clinoid process (ACP).

**Material and Method** Using a cross-sectional study design, 47 cranial computed tomography (CT) scans were examined. There were 31 (65.96%) females aged 28 to 79 years. The measured dimensions were ACP length and width, and optic strut (OS) width. Index ( $i_{acp}$ ) was measured as the ratio of ACP width to ACP length. The ACP volume and working operating field (WOF) volume were measured using Syngo.via Siemens program. The percentage expansion of WOF after removal of the ACP was estimated on 5 fixed human cadaver heads with the exoscope VITOM 3D. The possibilities of the combined approach were demonstrated in a clinical case.

**Results** The mean ACP lengths were  $11.31 \pm 2.76$  and  $11.54 \pm 2.86$  mm, on the right and left, respectively. The mean ACP widths were  $7.70 \pm 1.66$  and  $7.64 \pm 1.67$  mm, on the right and left, respectively. Average  $i_{acp}$  was 0.67 (minimum 0.45; maximum 0.90). The width of the OS varied in the range from 1.37 to 4.75 mm. The average volume of right ACP was  $0.71 \pm 0.16 \text{ cm}^3$ , right WOF was  $3.26 \pm 0.74 \text{ cm}^3$ , left ACP was  $0.71 \pm 0.15 \text{ cm}^3$ , left and WOF was  $3.20 \pm 0.76 \text{ cm}^3$ . Removal of the right ACP expanded the right WOF by  $22.21 \pm 3.88\%$ , and left ACP by  $22.78 \pm 5.50\%$ . There was an approximately 25% increase in the WOF from the cadaveric dissections. Taking into account the variability of the ACP and OS, we proposed our own surgical classification of complicated ( $i_{acp} \geq 0.67$ ; medium OS  $2.5 \text{ mm} \leq 4.0 \text{ mm}$ ; wide OS  $\geq 4.0 \text{ mm}$ ; ACP with pneumatization) and uncomplicated ACP ( $i_{acp} 0.45 \leq 0.67$  mm;  $i_{acp} \leq 0.45$ ; narrow OS  $\leq 2.5 \text{ mm}$ ; ACP without pneumatization). Using this classification, we developed an algorithm for ACP dissection and removal. This was piloted in a clinical case of microsurgical clipping of a left internal carotid artery-posterior communicating artery aneurysm via the left minipterional approach.

## Keywords

- ▶ anterior clinoid process
- ▶ optic strut
- ▶ clinoidectomy
- ▶ keyhole approach
- ▶ aneurysm

article published online  
September 27, 2023

DOI <https://doi.org/10.1055/s-0043-1771373>.  
ISSN 2248-9614.

© 2023. Asian Congress of Neurological Surgeons. All rights reserved.

This is an open access article published by Thieme under the terms of the Creative Commons Attribution-NonDerivative-NonCommercial-License, permitting copying and reproduction so long as the original work is given appropriate credit. Contents may not be used for commercial purposes, or adapted, remixed, transformed or built upon. (<https://creativecommons.org/licenses/by-nc-nd/4.0/>)

Thieme Medical and Scientific Publishers Pvt. Ltd., A-12, 2nd Floor, Sector 2, Noida-201301 UP, India

**Conclusion** Extradural removal of ACP expands the WOF by approximately 25%, it helps neurosurgeons to improve proximal vascular control and avoid complications, and expands the range of indications for neurosurgical interventions in the skull base area.

## Introduction

Modification of a classic pterional approach into the keyhole approach with craniotomy sizes from 3 to 5 cm has been developed to address craniometric volume challenges brought up by the classic pterional approach. However, the tight skull-base operating corridor still poses a formidable challenge in terms of mobility, and proximal vascular control for the neurosurgeon.

The combination of a minipterional approach with an extradural resection of the anterior clinoid process (ACP) makes it possible to expand the volume of the working operating field (WOF) on the skull base area.

The ACP represents the terminal portion of the lesser wing of the sphenoid bone and forms the anterior aspect of the lateral wall of the optic canal. Anatomically, the ACP is attached to the wing of the sphenoid bone by three bony structures (pillars): a lateral pillar, which is formed by a wedge-shaped ridge and is bounded from below by the superior orbital fissure, the medial pillar that forms the roof of the optic canal, and the inferior pillar (or optic strut [OS]), which separates the supraclinoid portion of the internal carotid artery (ICA) inferolaterally from the superior medial optic nerve.<sup>1</sup>

As ACP covers the roof of the cavernous sinus and the paraclinoid segment of the ICA, anterior clinoidectomy becomes mandatory in approaching cavernous sinus, and in optic canal decompression.<sup>2</sup>

Thus, ACP is a key access to the sellar/parasellar area, anterior and anterolateral circle of Willis, middle cerebral artery, upper basilar artery, and anterior cranial fossa. Removal of the ACP allows to reach all these regions and expands the range of indications for neurosurgical interventions in the skull base area, particularly at keyhole approaches, where every cubic millimeter of freed space has a crucial role for neurosurgeons.<sup>2</sup>

The technique of removing the ACP and OS has practical importance for a neurosurgeon. In our clinic, we use sequential drilling of the lateral and medial pillar, with further breaking, drilling, and cutting off the OS. The option of removing the OS depends on its morphometric parameters.<sup>1</sup>

Therefore, in this article, we decided to carry out a morphometry of ACP and OS and offer our own surgical classification of the OS to choose the appropriate method for removing it, and evaluate the percentage of the expansion of the volume of the WOF after the ACP removal.

## Material and Method

The present cross-sectional observational study was done in the Department of Neurosurgery, of the Federal

State-Financed Institution “Federal Centre of Neurosurgery” of the Ministry of Health of the Russian Federation (Tyumen). The study was conducted on 47 computed tomography (CT) of the patient’s head, included 31 females (65.96%) and 16 male adults (34.04%) whose age ranged between 28 and 79 years, all heads were measured bilaterally.


The CT measurements of length and width of ACP and OS was made with a Canon medical system Aquilion One 640 multislice CT scanner with 0.5 mm thick on CT RadiAnt DICOM Viewer (ver. 2020.1.1). The average basal width shows the distance between the lateral margin of the optic canal and the lateral edge of the ACP, the average basal length shows the distance from the middle of the base of the ACP to the apex of the ACP, and the average basal width of the inferior pillar (OS) shows the distance from anterior to posterior edge of the OS, all heads were measured bilaterally.

The CT measurements of the ACP volume and volume of WOF were conducted by three-dimensional (3D) reconstruction in the Syngo.via Siemens program. The ACP volume and the volume of the WOF were measured by tracing the points in different slices of 0.5 mm thick. The volume of the WOF was a polygonal figure limited by the lines connecting the following anatomical landmarks: the middle of the sulcus chiasmatis, the middle of the dorsum sella, the posterior clinoid process, the trigeminal depression of the pyramid of the temporal bone, the lateral edge of the base of the ACP, the base of the ACP, and the medial edge of the base of the ACP (► Fig. 1).

Determination of the percentage of expansion of the operative field after removal of the ACP was estimated on 5 fixed human cadaver heads. Microsurgical anatomical dissections and measurements were performed by the exoscope VITOM 3D (Karl Storz, Germany), the holding pneumatic arm Mitaka (Japan), the camera system, the cold xenon light source, the control unit (Karl Storz, image1 pilot), and the 3D 4K monitor. Images and video sequences were recorded in 3D and 4K quality with Karl Storz AIDA recorder system.<sup>3</sup> We demonstrated the possibilities of combined approach by using a clinical case and 3D reconstruction of the CT in the Meshmixer 3.5 program (► Fig. 2).

## Results

According to the CT measurements of digital indicators the length of the right ACP was  $11.31 \pm 2.76$  mm, the left ACP was  $11.54 \pm 2.86$  mm, and the width of the right ACP was  $7.70 \pm 1.66$  mm, left ACP was  $7.64 \pm 1.67$  mm. Average index of ratio of ACP width to ACP length ( $i_{acp}$ ) was 0.67, the value of the minimum  $i_{acp}$  in our study was 0.45, the value of the



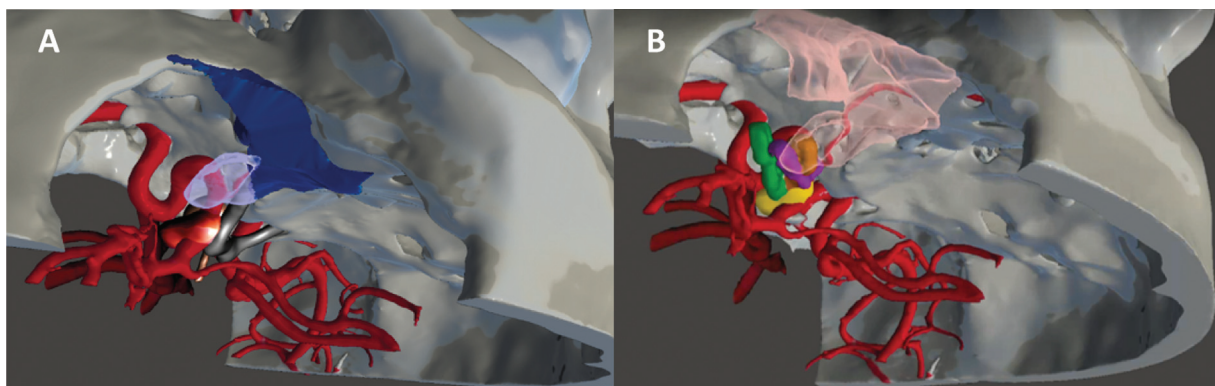
**Fig. 1** The working operating field (WOF). WOF is a polygonal figure limited by the lines connecting the following anatomical landmarks: 1, the middle of the sulcus chiasmatis; 2, the middle of the dorsum sellae; 3, the posterior clinoid process; 4, the trigeminal depression of the pyramid of the temporal bone; 5, the lateral edge of the base of the anterior clinoid process (ACP); 6, the medial edge of the base of the ACP.

maximum  $i_{acp}$  in our study was 0.90. The width of the OS varied in the range from the narrowest OS 1.37 mm to the widest OS 4.75 mm. There was no correlation between the length and width of the ACP and the width of OS due to the variability of the values. The average volume of the right ACP was  $0.71 \pm 0.16 \text{ cm}^3$ , the left ACP was  $0.71 \pm 0.15 \text{ cm}^3$ . The volume of the right WOF was  $3.26 \pm 0.74 \text{ cm}^3$ , the left WOF was  $3.20 \pm 0.76 \text{ cm}^3$ . Removal of the right ACP expanded the right WOF by  $22.21 \pm 3.88\%$ . Removal of the left ACP expanded the left WOF by  $22.78 \pm 5.50\%$  (**→ Figs. 1 and 3**).

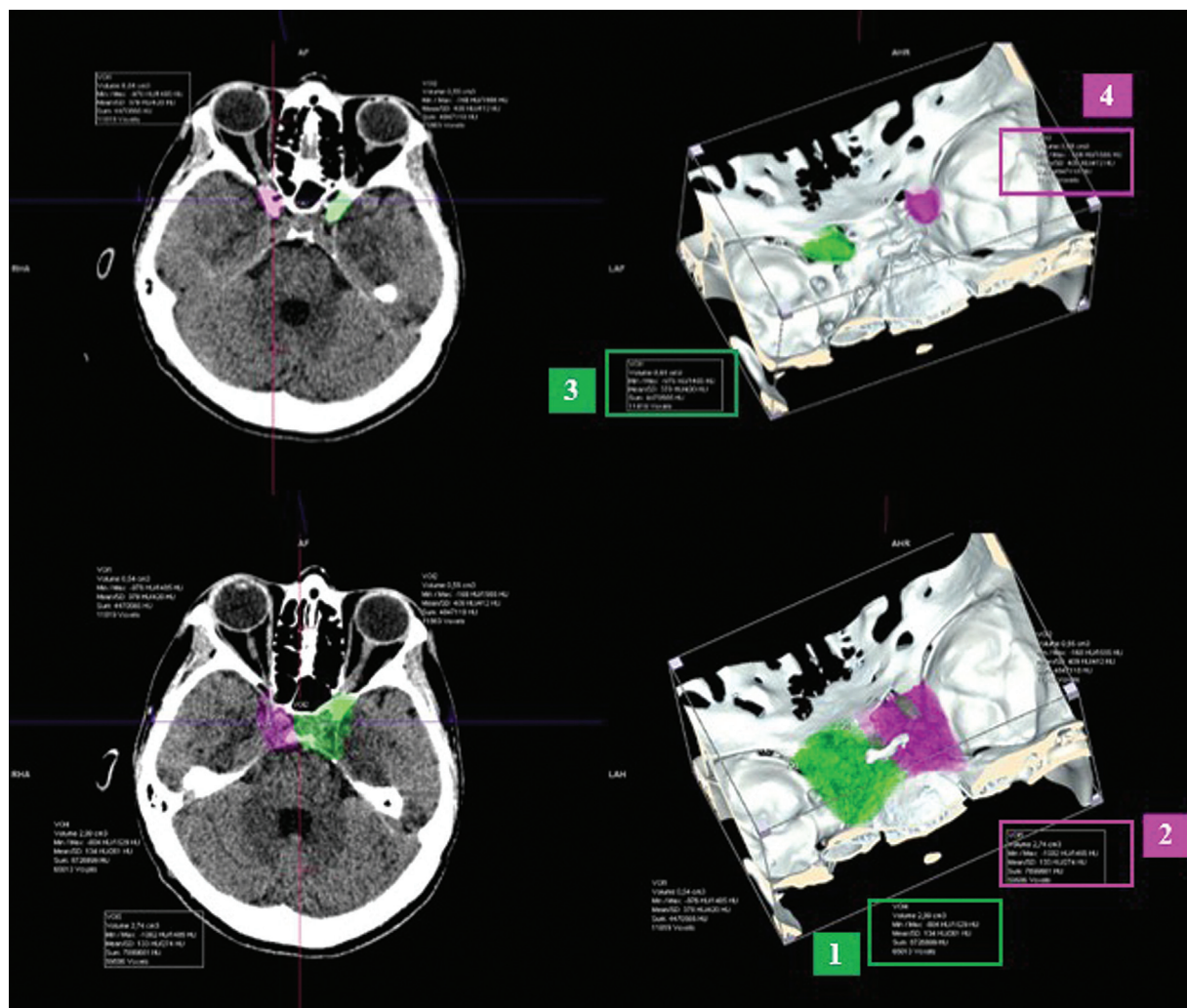
The cadaver dissection using the exoscope VITOM 3D demonstrated sequential removal of the lateral, medial,

and inferior pillar of the ACP. The extradural resection has increased the volume of the operative field by approximately 25% and allowed to visualize previously unidentified structures as the posterior clinoid process, basilar artery, superior cerebellar artery, posterior cerebral artery, and cranial nerve III (**→ Fig. 4**).

During cadaveric dissection and removal of ACP, we assessed the technical difficulties in removing the ACP. The complexity of ACP dissection directly depends on the ratio of width to length of ACP. When the  $i_{acp}$  was more than 0.90, the ACP was short and wide, and there was no problem with dissection of the ACP tip and we used the extradural



**Fig. 2** (A) Reconstruction of the anterior clinoid process (ACP) before aneurysm clipping. (B) Three-dimensional (3D) reconstruction of the ACP after aneurysm clipping.



**Fig. 3** The computed tomography (CT) measurements of the anterior clinoid process (ACP) volume and volume of the working operative field were conducted by three-dimensional (3D) reconstruction in the CT Radiant program. The ACP volume and volume of the operative field (OF) were measured by tracing the points in different slices of 0.5 mm thick. The volume of the operative field was a polygonal figure limited by the lines connecting the following anatomical landmarks: the middle of the sulcus chiasmatis, the middle of the dorsum sella, the posterior clinoid process, the trigeminal depression of the pyramid of the temporal bone, the lateral edge of the base of the ACP, the base of the ACP, and the medial edge of the base of the ACP. 1, The volume of the left operative field = 2.99 cm<sup>3</sup>. 2, The volume of the right operative field = 2.74 cm<sup>3</sup>. 3, The left ACP volume = 0.54 cm<sup>3</sup>. 4, The right ACP volume = 0.55 cm<sup>3</sup>.

technique of removing. When the  $i_{acp}$  was less than 0.45, the ACP was long and narrow, it was difficult to skeletonize the tip and we had to use combine technique (extradural fragmentation with intradural removal of the tip).

Moreover, during cadaver removal of the ACP, we found that mainly technical difficulties arise on stage of OS removal. The inferior pillar is the most significant in neurosurgical operations and requires special neurosurgical equipment. Incomplete OS removal can lead not only to damage the optic nerve or the ICA but decrease the proximal vascular control.

Taking into account the variability of the anatomical variations of  $i_{acp}$  and the width of the bone of OS, we proposed a surgical classification of complicated and uncomplicated ACP in **►Table 1**.

In our morphometric study of 47 CT we found out that there was 63% uncomplicated ACP and 37% complicated ACP

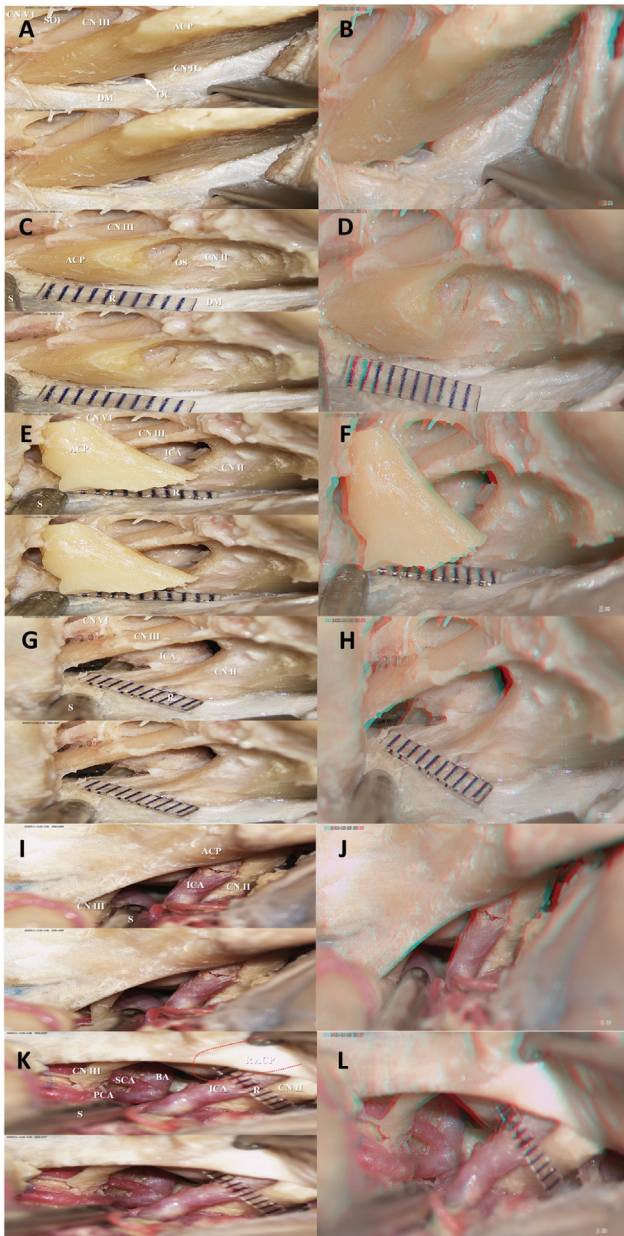
cases. Complicated ACP was associated more with  $i_{acp}$  (66%) than with a wide OS (10%) and pneumatization (17%).

This classification has practical application and can be used by neurosurgeons to choose the method of the dissection and removal of ACP. In obedience to this classification, we have developed our own algorithm of ACP dissection and removal.

The possibilities of the combined approach were demonstrated in a clinical case.

#### **A Clinical Case**

A 44-year-old woman (**►Video 1**) was admitted to the Federal Centre of Neurosurgery in Tyumen, without a history of previous subarachnoid hemorrhage, presented with symptoms of weakness and headaches. Neurological examination did not reveal any neurological pathology. The CT angiography and selective cerebral angiography showed a



**Fig. 4** Cadaver dissection of anterior clinoid process, step by step. (A) Anatomical structures before anterior clinoid process (ACP) removal. (B) Three-dimensional (3D) anatomical structures before ACP removal. (C) Anatomical structures after partial drilling of ACP. (D) 3D anatomical structures after partial drilling of ACP. (E) Removal ACP. (F) 3D image of ACP removal. (G) Operative field after removal of ACP. (H) 3D operative field after removal of ACP. (I) Operative field before ACP removal. (J) 3D operative field before ACP removal. (K) After removal of ACP the posterior clinoid process, basilar artery, superior cerebellar artery, posterior cerebral artery, and CN III are exposed. Red line-opened field after ACP removal. (L) 3D after removal of ACP the posterior clinoid process, basilar artery, superior cerebellar artery, posterior cerebral artery, and CN III are exposed. APC, anterior clinoid process; BA, basilar artery; CN (cranial nerve) II, optic nerve; CN III, oculomotor nerve; CN V1, trigeminal nerve ophthalmic branch; DM, dura mater; ICA, internal carotid artery; OC, optic canal; OS, optic strut; PCA, posterior cerebral artery; R, ruler; RAPC, removal anterior clinoid process; S, suction; SCA, superior cerebellar artery; SOF, superior orbital fissure.

saccular aneurysm of the left ICA-posterior communicating artery (PComMA). Microsurgical clipping of the aneurysm of the left ICA-PComMA via left minipterional craniotomy with

extradural anterior clinoidectomy using the microscope Carl Zeiss OPMI PENTERO 900 was done.

#### Video 1

Extradural part: meningo-orbital band incision; the medial, lateral pillar sawing; optic strut removing with specialized bone rongeurs (Muranaka, Japan), and a drill. Intradural part: microsurgical clipping of the left internal carotid artery-posterior communicating artery (ICA-PComMA) aneurysm with 3 clips; indocyanine green (ICG) control. Online content including video sequences viewable at: <https://www.thieme-connect.com/products/ejournals/html/10.1055/s-0043-1771373>.

Extradural anterior clinoidectomy was performed in this case, step by step after soft tissue dissection and meningo-orbital band coagulation. According to preoperative CT RadiAnt DICOM Viewer measurements the length of the ACP was 10.01 mm, and the width of the ACP was 7.7 mm.  $i_{acp}$  was 0.77, OS was 2.73, without pneumatization;  $i_{acp}$  allowed to make skeletonization without technical difficulties.

The lateral pillar was removed during the resection of the lesser wing of the sphenoid bone and part of the roof of the superior orbital fissure. The medial pillar was removed by drilling with the Stryker system rotary drill.

Removal of the optic septum was performed using specialized bone rongeurs (Muranaka, Japan) and a drill, because according to the preoperative CT RadiAnt DICOM Viewer measurements, the dimension of the OS width was 2.73 mm. In obedience to our classification, this OS was classified as medium OS. After resection of all bone pillars, the ACP becomes mobile and is fixed mainly due to the petroclinoidal and interclinoidal ligaments. A complete dissection of the ACP is performed by sharp dissection of these ligaments with microscissors or a specialized sickle-shaped microdissector (Feather, Japan). The proximal part of the ICA was opened after ACP removal, this condition contributed to improving the proximal vascular control and expanding the operative field. After demobilization of the ICA the microsurgical clipping of the aneurysm of the left ICA-PComMA was performed by three special clips: two straight clips and one curved fenestrated clip. Then a standard closure of wound, and hemostasis was done. Postoperative control was made by CT angiogram. The result was downloaded to the Meshmixer program for 3D reconstruction (► Fig. 5). The patient was discharged 6 days after the operation.

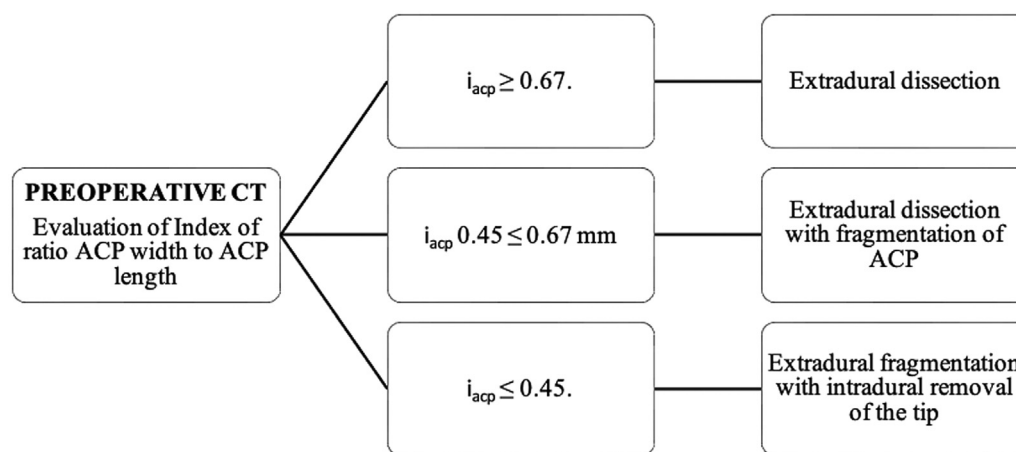
#### Discussion

Since the conception of aneurysm surgery introduced by Norman Dott in 1933, and then developed by Yaşargil et al<sup>4</sup> in 1975, by using the microneurosurgical methods, different approaches for aneurysm clipping have been innovated with good improvement in surgical outcomes. The pterional

**Table 1** Parameters of anterior clinoid process by CT scans and frequency of occurrence of uncomplicated and complicated ACP in our study

Anterior clinoid process	$i_{acp}$	N (%)	OS	N (%)	$P_{neum}$	N (%)
Uncomplicated ACP $n = 30$	$i_{acp} \geq 0.67$	31 (66)	Narrow optic strut $\leq 2.5$ mm	35 (74)	Without pneumatization ACP	39 (83)
Complicated ACP (if one of the parameters is present) $n = 17$	$i_{acp} 0.45 \leq 0.67$ mm	9 (19)	Medium optic strut $2.5$ mm $\leq 4.0$ mm	7 (14)	With pneumatization ACP	8 (17)
	$i_{acp} \leq 0.45$	7 (14)	Wide optic strut $\geq 4.0$ mm	5 (10)		
Total		47 (100)		47 (100)		47 (100)

Abbreviations: ACP, anterior clinoid process; CT, computed tomography;  $i_{acp}$ , index of ratio ACP width to ACP length; OS, optic strut;  $P_{neum}$ , pneumatization.

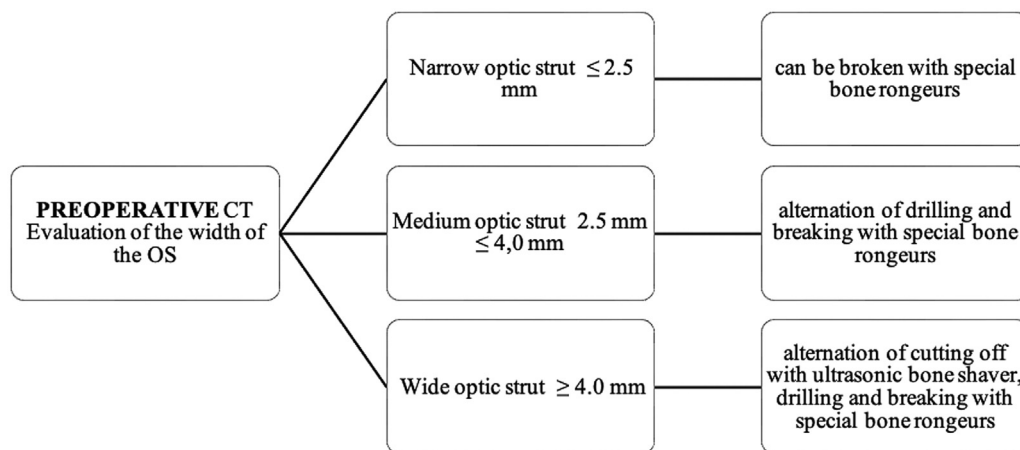
**Fig. 5** Algorithm of anterior clinoid process (ACP) dissection with evaluation of index of ratio ACP width to ACP length ( $i_{acp}$ ).

craniotomy with the frontotemporal Sylvian fissure opening has been the hallmark of these surgeries.<sup>5</sup> However, postoperative complications such as mandibular dysfunction, chronic pain, and alterations in the facial sensory components frequently associated with temporal atrophy and injury of the frontal branch of the facial nerve and trigeminal branches have been reported.<sup>6-8</sup> As a result, constant modifications to the classical pterional approach have been done with the desire to reduce the volume of craniotomy, and also to reduce the traumatism caused during the intraoperative and postoperative complications.

Technological progress, the emergence of operating microscopes, VITOM 3D, endoscopes, and the description of microsurgical techniques have made it possible to reduce the volume of the surgical access to the keyhole approaches. The minipterional keyhole craniotomy has been developed as one of the alternative modalities.<sup>9</sup> However, modification of a classic pterional approach into keyhole with craniotomy sizes from 3 to 5 cm, limits the scope of surgical interventions in the skull base area and has some safety issues, especially when an intraoperative rupture occurs. Achieving the hemostasis within a small corridor poses great challenge for the neurosurgeon.<sup>9-11</sup>

The principle of minimally invasive techniques entails a balance between minimal tissue trauma and maximum anatomic exposure.<sup>12</sup> In this study, the rationale for an extradural anterior clinoidectomy as a keyhole approach was illustrated by morphometry of the ACP. ACP is the key of the access to the sellar and parasellar area, anterior and anterolateral circle of Willis, middle cerebral artery, upper basilar artery, and anterior cranial fossa. In our study, the combination of a minipterional approach with extradural resection of the ACP expanded the volume of the operative field of the skull base by 25%. It is a very important digital indicator, particularly at keyhole approaches, where every millimeter of freed space has a crucial role for neurosurgeons. This extended operative corridor aids neurosurgeons improve proximal vascular control and expands the range of indications for neurosurgical interventions in the skull base area.

In the last decades, there has been an increasing interest and publication in ACP morphometry. In a study done by Dagtekin et al, the average basal width, length, and thickness of the ACP were found to be 7.3, 9.7, and 5.4 mm, respectively.<sup>13</sup> Similar observations were reported in Nepal, Indian, Japan, and Korean skulls, respectively.<sup>14-17</sup> Cecen et al classified ACP



**Fig. 6** Algorithm of anterior clinoid process (ACP) removal.

into three types: type I ACPs short, wide, and wide-angled; type II ACPs long, narrow, and narrow-angled; and type III ACPs.<sup>18</sup>

In our study the length of the right ACP was  $11.31 \pm 2.76$  mm, the left ACP was  $11.54 \pm 2.86$  mm, the width of the right ACP was  $7.70 \pm 1.66$  mm, the left ACP was  $7.64 \pm 1.67$  mm, which means that the length of ACP of skulls is longer and the width is less than the average calculated in other countries.<sup>18</sup> This finding therefore correlated to a type II ACP classification (long, narrow, and narrow-angled) which require more challenging surgical techniques according to Cecen et al.<sup>18</sup> In our study, the average  $i_{acp}$  was 0.67, the value of the minimum  $i_{acp}$  in our study was 0.45, and the value of the maximum  $i_{acp}$  in our study was 0.90. The complexity of ACP dissection directly depends on the ratio of width to length of ACP. According to those parameters we created our own algorithm of ACP dissection, which is shown in **Fig. 5**.

Moreover, during the cadaver removal of the ACP, we found that mainly technical difficulties arise on stage of OS removal. The inferior pillar is the most significant in neurosurgical operations and requires special neurosurgical equipment.

There are a lot of studies devoted to the OS removal during the surgery in the sellar and parasellar regions, as incomplete removal can lead to damage to the optic nerve or the ICA. The objective of the study done by Kapur and Mehić was to quantify dimensions of the OS and ACP, and to determine variations in positions and forms of these structures. They find out that the average width of the OS was 3 mm on the skulls belonging to males, and 2.8 mm on those belonging to females; moreover, the OS was most commonly attached to the anterior two-fifths on the lower side of the ACP.<sup>19</sup> In our study, the width of the OS varied in the range from the narrowest OS 1.37 mm to the widest OS 4.75 mm and there was no correlation between the length and width of the ACP and the width of OS due to the variability of the values.

According to these findings, we created our own algorithm of OS removal, which is shown in **Fig. 6**.

Along with morphometric measurements, the literature describes variants of pneumatized ACP, which can compli-

cate the surgical treatment as a result of unintentional opening of the sphenoid and ethmoid sinus opening during clinoidectomy.<sup>20,21</sup> In our previous study, we proposed our own method of removing the ACP by drilling the lateral, medial pillar with sequential removal of the inferior pillar.<sup>1</sup> We offer a method of removal of OS (inferior pillar) using a special technique described in this article. In our opinion, a thorough study of the anatomy of the ACP with CT will allow to choose the optimal access for sequential removal of ACP, which contributes to performing a gentle surgery without intraoperative complications.

## Conclusion

The knowledge of morphometry of ACP and OS is very important for neurosurgeons for finding the safest technique of extradural anterior clinoidectomy. In our series, removal of the right ACP expanded the right WOF by  $22.21 \pm 3.88\%$ , the left ACP expanded the left WOF by  $22.78 \pm 5.50\%$ . The extradural resection performed on the cadaver specimen increased the volume of the operative field by approximately 25%. The results of cadaver dissection correlated with the results of the real surgery, which we illustrated in our clinical case. Taking into account the variability of the ACP and OS, we would like to propose our own surgical classification of complicated ( $i_{acp} \geq 0.67$ ; medium OS  $2.5 \text{ mm} \leq 4.0 \text{ mm}$ ; wide OS  $\geq 4.0 \text{ mm}$ ; ACP with pneumatization) and uncomplicated ACP ( $i_{acp} 0.45 \leq 0.67 \text{ mm}$ ;  $i_{acp} \leq 0.45$ ; narrow OS  $\leq 2.5 \text{ mm}$ ; ACP without pneumatization). This classification has practical application and can be used by neurosurgeons to choose the optimal method of dissection and removal of the ACP. Basing on the aforementioned classification, we created our own algorithm. Detailed study of ACP anatomy and our neurosurgical technique of extradural resection of ACP will allow surgeons expand the volume of the narrow operative corridor in the skull base area by 25%, it will also help neurosurgeons to improve proximal vascular control, avoid complications, and increase the range of indications for neurosurgical interventions in the skull base area.

**Conflict of Interest**

None declared.

**References**

- 1 Sufianov AA, Markin ES, Sheliagin IS, et al. How I do it: microsurgical clipping of carotid-ophthalmic aneurysms through minipterional approach with extradural resection of the anterior clinoid process. *Sechenov Med J* 2021;12(04):51–63
- 2 Cheng Y, Wang C, Yang F, Duan Y, Zhang S, Wang J. Anterior clinoid process and the surrounding structures. *J Craniofac Surg* 2013;24(06):2098–2102
- 3 Rossini Z, Cardia A, Milani D, Lasio GB, Fornari M, D'Angelo V. Vitom 3d: Preliminary experience in cranial surgery. *World Neurosurg* 2017;107:663–668
- 4 Yasargil MG, Fox JL. The microsurgical approach to intracranial aneurysms. *Surg Neurol* 1975;3(01):7–14
- 5 Welling LC, Figueiredo EG, Wen HT, et al. Prospective randomized study comparing clinical, functional, and aesthetic results of minipterional and classic pterional craniotomies. *J Neurosurg* 2015;122(05):1012–1019
- 6 Figueiredo EG, Welling LC, Preul MC, et al. Surgical experience of minipterional craniotomy with 102 ruptured and unruptured anterior circulation aneurysms. *J Clin Neurosci* 2016;27:34–39
- 7 Madhugiri VS, Ambekar S, Pandey P, et al. The pterional and suprabrow approaches for aneurysm surgery: a systematic review of intraoperative rupture rates in 9488 aneurysms. *World Neurosurg* 2013;80(06):836–844
- 8 Fujii T, Otani N, Takeuchi S, Toyooka T, Wada K, Mori K. Horizontal distance of anterior communicating artery aneurysm neck from anterior clinoid process is critically important to predict postoperative complication in clipping via pterional approach. *Surg Neurol Int* 2017;8:200
- 9 Tra H, Huynh T, Nguyen B. Minipterional and supraorbital keyhole craniotomies for ruptured anterior circulation aneurysms: experience at single center. *World Neurosurg* 2018;109:36–39
- 10 Yu LH, Yao PS, Zheng SF, Kang DZ. Retractorless surgery for anterior circulation aneurysms via a pterional keyhole approach. *World Neurosurg* 2015;84(06):1779–1784
- 11 Yu LB, Huang Z, Ren ZG, et al. Supraorbital keyhole versus pterional craniotomies for ruptured anterior communicating artery aneurysms: a propensity score-matched analysis. *Neurosurg Rev* 2020;43(02):547–554
- 12 Martinez-Perez R, Joswig H, Tsimpas A, et al. The extradural minipterional approach for the treatment of paraclinoid aneurysms: a cadaver stepwise dissection and clinical case series. *Neurosurg Rev* 2020;43(01):361–370
- 13 Dagtekin A, Avci E, Uzmansel D, et al. Microsurgical anatomy and variations of the anterior clinoid process. *Turk Neurosurg* 2014;24(04):484–493
- 14 Gupta N, Ray B, Ghosh S. A study on anterior clinoid process and optic strut with emphasis on variations of caroticoclinoid foramen. *Nepal Med Coll J* 2005;7(02):141–144
- 15 Hunnargi S, Ray B, Pai SR, Siddaraju KS. Metrical and non-metrical study of anterior clinoid process in South Indian adult skulls. *Surg Radiol Anat* 2008;30(05):423–428
- 16 Huynh-Le P, Natori Y, Sasaki T. Surgical anatomy of the anterior clinoid process. *J Clin Neurosci* 2004;11(03):283–287
- 17 Lee HY, Chung IH, Choi BY, Lee KS. Anterior clinoid process and optic strut in Koreans. *Yonsei Med J* 1997;38(03):151–154
- 18 Cecen A, Celikoglu E, Is M, et al. Pre-operative measurement of the morphometry and angles of the anterior clinoid process (ACP) for aneurysm surgery. *Int J Morphol* 2016;34(04):1333–1338
- 19 Kapur E, Mehić A. Anatomical variations and morphometric study of the optic strut and the anterior clinoid process. *Bosn J Basic Med Sci* 2012;12(02):88–93
- 20 Huynh-Le P, Natori Y, Sasaki T. Surgical anatomy of the anterior clinoid process. *J Clin Neurosci* 2004;11(03):283–287
- 21 Kantarci M, Karasen RM, Alper F, Onbas O, Okur A, Karaman A. Remarkable anatomic variations in paranasal sinus region and their clinical importance. *Eur J Radiol* 2004;50(03):296–302