

FASCIOCUTANEOUS PEDICLED FLAPS FROM POSTERO-LATERAL & LATERAL THORACIC REGION

PRAMOD KUMAR, R. CHANDRA AND S. P. BHAGIA

SUMMARY

The detailed anatomy of the lateral and posterolateral thoracic region and observations in five cadaveric dissections are being described. In 13 selected patients, parascapular, lateral thoracic and subaxillary flap has been used clinically. The results of the study have been analysed.

The vascular supply to the skin of the lateral thoracic region is derived from—

- (a) *Musculocutaneous perforators*: From the thoracodorsal artery, the inter-costal arteries and the lateral thoracic artery.
- (b) *Direct Cutaneous arteries*: To lateral thoracic region from subscapular thoracodorsal arterial axis, lateral thoracic artery, the pectoral branch of acromiothoracic artery and sometimes the accessory lateral thoracic artery.

Based on the above anatomy the parascapular flap (Tolhurst & Haesker, 1982), the lateral thoracic flap (Bhagia & Chandra, 1987) and subaxillary fasciocutaneous flap (Chandra et al, 1987) have been designed from the lateral thoracic region.

Material and Methods

The patients for the present study have been selected from those attending the Departments of Plastic Surgery, Orthopaedics and General Surgery. Parascapular fasciocutaneous flap has been used in five patients of post-burn axillary contractures. Lateral thoracic fasciocutaneous flap has been used in four patients of defects on the dorsum of hand and subaxillary fasciocutaneous flap in four patients of defects on the dorsum of hand and middle finger.

During the present study we have dissected five cadavers to find out the details of the vascular anatomy of fasciocutaneous flaps of the lateral thoracic region.

Cadaver Study

(1) *The parascapular artery*: In all the dissections the artery was arising from the circumflex scapular artery. Within 1-2 cms. after its emergence from the omotricipital space it was found to pierce the deep fascia. Running parallel to the lateral border of scapula, it could be traced upto the inferior angle of scapula in all the cadavers (Fig.1).

(2) *The direct cutaneous branch from subscapular-thoracodorsal arterial axis*: Out of the five cadaveric dissections in 4 dissections it was found to arise from the thoracodorsal artery and in one dissection it was seen arising from the subscapular artery. In all cases below the level of 4th intercostal space in mid axillary line its course was relatively fixed. It was seen running 1-1.5 cms. anterior to the lateral border of latissimus dorsi muscle (Fig. 2), Rowsell et al (1984) in 100 cadaveric dissection, have demonstrated its presence in 82% of cases.

(3) *The lateral thoracic artery*: Lateral thoracic artery (accompanied by two venae comitantes) was found to be covered by pectoralis major muscle, only for 3-4 cms. in the upper part in all the specimens. In the rest of its course it becomes superficial. This artery could be dissected for 12-15 cms. (Fig. 2). Two fasciocutaneous perforators at the lateral border of pectoralis major could be dissected in only one specimen.

(4) *Accessory lateral thoracic artery*: This could be found in only one dissection.

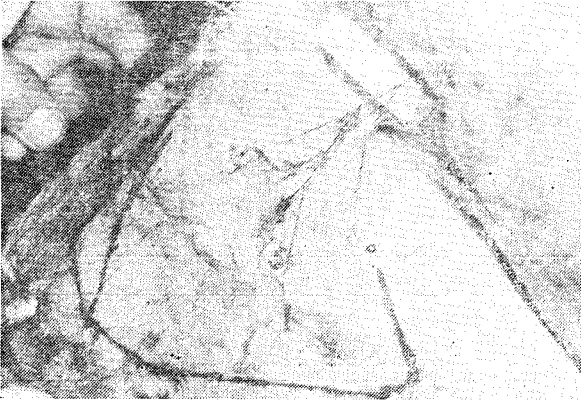


Fig. 1. Cadaveric dissection showing Parascapular (P) and Scapular (S) arteries emerging on the back through the triangular space.

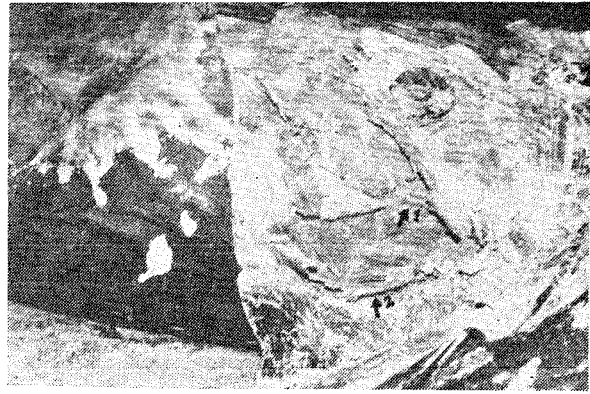


Fig. 2. Dissection showing lateral thoracic vessels (1) and the cutaneous branch from subscapular thoracodorsal arterial axis (2).

Design of the flap

Parascapular fasciocutaneous flap:

The long axis of the flap is parallel to the lateral border of the scapula (Fig. 3). The parascapular artery lies in the central axis of the flap. Base of the flap lies at the triangular space. A flap of ratio 1:3 or more can be raised safely.

Lateral thoracic fasciocutaneous flap:

The long axis of the flap is oriented vertically downwards in lateral thoracic region (Fig. 4). The base of the flap lies at the 3rd rib or 3rd intercostal space in mid axillary line. Anterior incision lies over a vertical line drawn from the coracoid process. Posterior incision lies on a vertical line drawn from a point 2 cms. medial to the free border of latissimus dorsi muscle at the level of the 3rd rib. The lower limit can be extended 3-4 cms. beyond the costal margin.

Subaxillary fasciocutaneous flap:

The long axis of the flap lies parallel to the vascular pedicle running 1-1.5 cms. anterior and parallel to the free border of latissimus dorsi (Fig. 5). The base of the flap lies at about the level of the nipple. Flap with a length: breadth ratio of 3:1 can be raised very safely.

Operative techniques:

Like other fasciocutaneous flap, all these three flaps are raised with deep fascia, leaving bare muscle in the donor area.

Care of donor area:

The donor defect is closed primarily after extensive mobilization, but large defects may require split skin graft as a cover.

Observations

During the present study we have used parascapular flap as transposition flap for resurfacing defects of axillary contractures in five cases. (Fig. 6a & 6b). Abduction splint was removed after 2 weeks. Patients were then kept on physiotherapy. No recurrence was noticed in any of these cases of axillary contracture. The subaxillary flap has been used to resurface defects of the dorsum of the hand in 3 cases (Fig. 7). In one case exposed middle phalanx and interphalangeal joints of middle finger following an electric burn has been successfully covered by the subaxillary flap (Fig. 8). Donor area was closed primarily in all cases. The lateral thoracic flap (Fig. 9) has been used to resurface large defects over dorsum of hand following hand injury in 3 cases and following

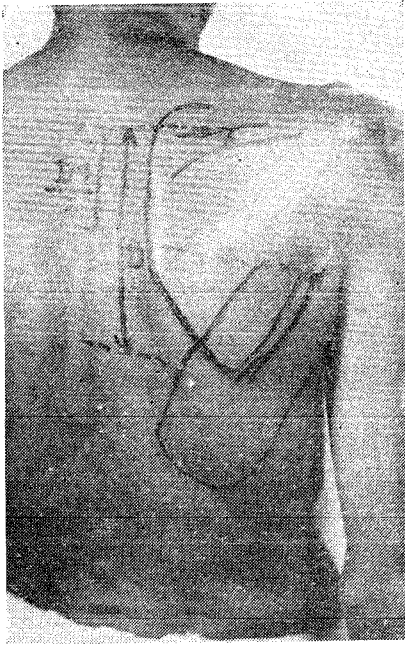


Fig. 3. Design of the parascapular flap.
D—Distance between inferior angle of scapula and mid point of spine of scapula.

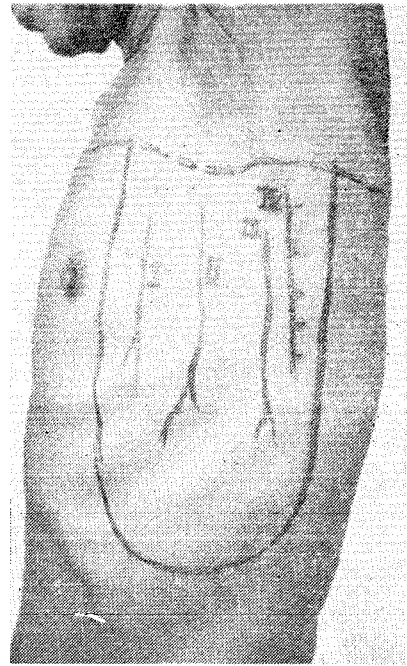


Fig. 4. Design of the lateral thoracic fasciocutaneous flap. I—Lat thoracic, II—Accessory lateral thoracic, III—Cutaneous br. from subscapular thoracodorsal arterial axis, IV—Musculocutaneous perforators from thoracodorsal artery.

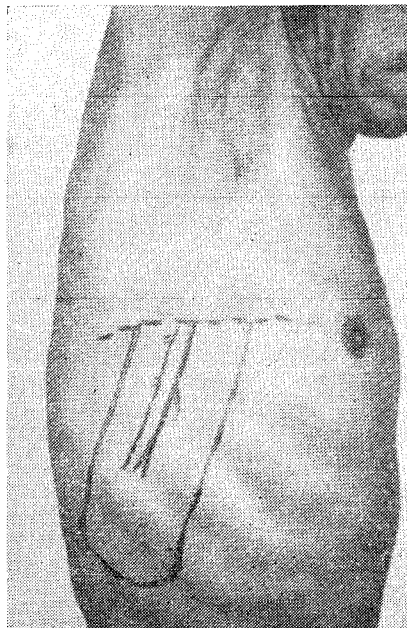


Fig. 5. Design of subaxillary fasciocutaneous flap.

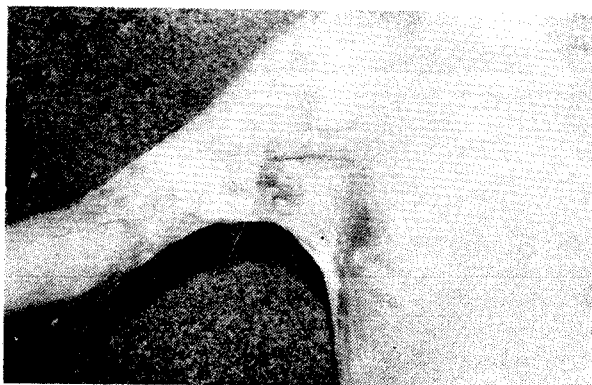


Fig. 6 (a). Photograph showing Post-burn axillary contracture.

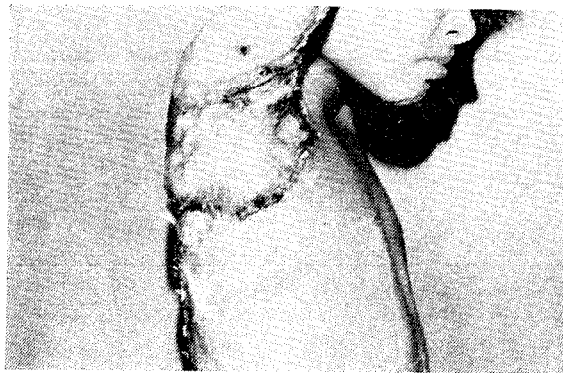
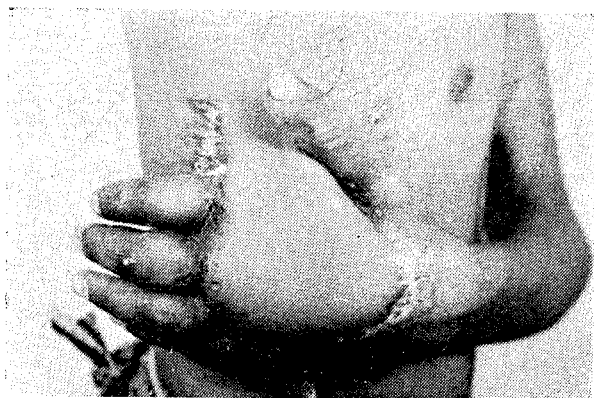

Fig. 6 (b). Post-operative result. Parascapular flap has been used as transposition flap.



Subaxillary fasciocutaneous flap has been used to resurface defect of the dorsum of hand.

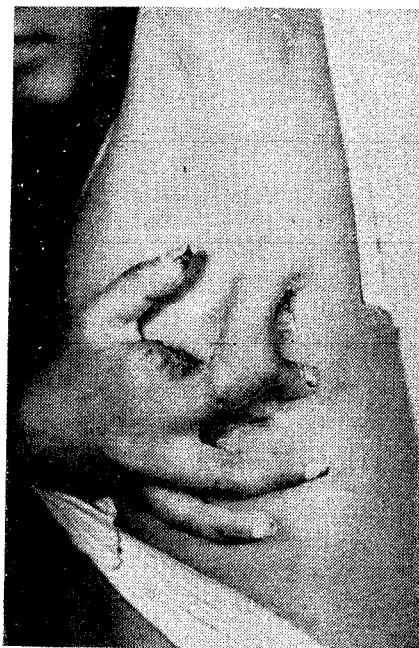

Fig. 8. Subaxillary fasciocutaneous flap used to cover exposed middle phalanx and P. I. P. joint of middle finger.

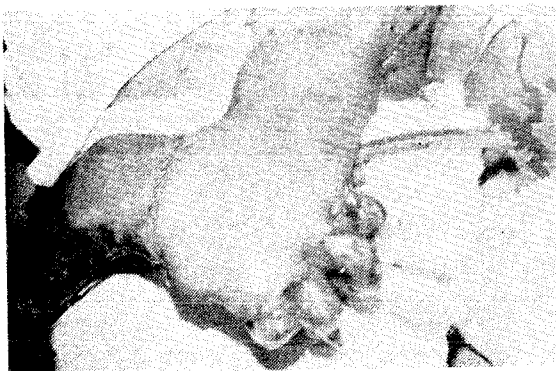


Fig. 9. Lateral thoracic fasciocutaneous flap used to cover the large defect over the dorsum of the hand.

release of post-burn extension contracture of the hand in one case.

For resurfacing defects of hand subaxillary and lateral thoracic flaps provide a position of immobilisation which is quite comfortable. These flaps are thin and provide non-hairy skin.

Infection and loss of skin graft was noticed in one case of hand injury where lateral thoracic flap was used to cover the defect over dorsum of the hand.

Discussion

Based on the various direct cutaneous arteriovenous systems, free lateral thoracic flap (Hariri et al, 1978) and free thoracodorsal axillary flap (de Coninck, 1975; Baudet 1976) have been designed.

After the success of fasciocutaneous flap of Ponten (1981), the lateral and posterolateral thoracic region has been explored for fasciocutaneous flaps by Tolhurst & Haesker (1982), Nassif (1982), Cormac & Lamberty (1983), Chandra et al (1987) and Bhagia & Chandra (1987).

From the point of view of vascularity, the flaps from lateral thoracic region are very reliable. In the present study of thirteen cases flap necrosis was not seen in any of the case.

Tolhurst & Haesker (1982) has used 15 parascapular flaps for axillary contractures

without any complication. Bhagia et al (1986) have successfully used parascapular flap to salvage the amputation stump with exposed neurovascular bundle. In the present series of five cases of post-burn axillary contractures the flap was used without any regrets.

Taylor and Daniel after twenty cadaveric dissections proposed a free skin flap based on the subscapular vessel system in 1975. He did not report any clinical case. Chandra et al (1987) have designed subaxillary pedicled fasciocutaneous flap based on the direct cutaneous branch from subscapular thoracodorsal arterial axis and used it in 12 patients for defects of fingers, thumb, web spaces, adduction contracture and dorsum of the hand. They noticed superficial necrosis in one case only. In the present series we have used this flap for resurfacing defects of dorsum of hand and exposed proximal inter-phalangeal joint of middle finger without any complication.

Bhagia & Chandra (1987) have designed and used lateral thoracic flap in fifteen patients without any problem. They have used this flap as a local transposition flap in cases of axillary contractures, as distant flap in cases of hand injury, ipsilateral upper arm resurfacing, adduction contracture and circumferential resurfacing of distal forearm in a case of Volkmann's ischemic contracture and as a tube pedicle on a wrist carrier for a defect of the leg.

We have used it in four cases with large defects over dorsum of the hand with wound infection and loss of graft from the donor area in one case.

In our experience the donor defect in lateral thoracic area upto 5 cms. can be closed primarily after undermining with minimal scar stretching. Between 5-7 cms., the defect can be closed after extensive undermining and

tension stitches are left for about 14 days. Defect larger than 7 cms. require split skin graft as a cover.

Conclusion

The pedicled fasciocutaneous flaps of the lateral and posterolateral thoracic regions are relatively new, reliable and versatile flaps and can be clinically used in different situations.

REFERENCES

1. BAUDET, J., GUIBERKAN, J. C. AND NASCIMENTO, E. : Successful free transfer of two free thoracodorsal axillary flaps. *Plastic and Reconstructive Surgery*. 1976; 58: 680.
2. BHAGIA, S. P. AND CHANDRA, R. : Lateral Thoracic Fasciocutaneous flap, Transactions of the IX International Congress of Plastic and reconstructive Surgery, Tata McGraw-Hill Publishing Company Limited, New Delhi (India), 1987; 148-149.
3. BHAGIA, S. P., KUMAR, P., CHANDRA, R. AND BHATNAGAR, S. K. : The Parascapular Fasciocutaneous Flap, *Indian Journal of Plastic Surgery*, 1986; 19: 83-87.
4. CHANDRA, R., KUMAR, P. AND ABDI, S. M. H. : The Subaxillary Pedicled Flap, *British J. of Plastic Surgery*, 1987 (In Press).
5. CORMAC, G. C. AND LAMBERTY, B. C. G. : The anatomical vascular basis of the axillary fasciocutaneous pedicled flap. *British Journal of Plastic Surgery*. 1983; 36: 425.
6. DE CONINCK, A. ET AL : AUTO transplants are micro-sutures vasculaires. *Anatomic des zones donneuses. Am. Chir. Plast.* 1975; 20: 163.
7. HARI, K., TORI, S. AND SEKIGUCHI, J. : The free lateral thoracic flap. *Plastic and Reconstructive Surgery*, 1978; 62: 212.
8. NASSIF, T. M., VIDAL, L., BOVET, J. L. AND BANDED, T. J. : The parascapular flap: a new cutaneous microvascular free flap. *Plastic and Reconstructive Surgery*. 1982; 69: 591.
9. ROWSELL, A. R., DAVIES, D. M., EISENBERG, N. AND TAYLOR, G. I. : The anatomy of the subscapular thoracodorsal arterial system: Study of 100 cadaver dissections. *British Journal of Plastic Surgery*. 1984; 37: 574.
10. TAYLOR, G. I. AND DANIEL, R. K. : The anatomy of several free flap donor sites. *Plastic and Reconstructive Surgery*. 1975; 56: 243.
11. TOLHURST, D. E. AND HAESKER, B. : Fasciocutaneous flaps in the axillary region. *British Journal of Plastic Surgery*, 1982; 35: 430.

The Authors

DR. PRAMOD KUMAR, M.S., *Chief Resident*.

PROF. R. CHANDRA, M.S., M.S., F.R.C.S., *Professor & Head*.

DR. S. P. BHAGIA, M.S., M.Ch.

Postgraduate Deptt. of Plastic Surgery, K. G.'s Medical College, Lucknow.

Request for Reprints

DR. PRAMOD KUMAR, M.S., *Chief Resident*, Postgraduate Department of Plastic Surgery, King George's Medical College, Lucknow.