

A CASE OF PRIAPISM

R. BHARAT, B. P. SENGUPTA AND M. N. BHAT

SUMMARY

A rare case of idiopathic priapism in a 45 years old man is being reported. It was treated by Saphenocorporal shunt with gratifying result.

Priapism is a painful, pathological and persistent erection of penis unrelated to sexual desire. There have been diverse opinions regarding the aetiology and management of this condition.

Lue, Hellstrom, McAninch and Tonagho (1986) have described two types of Priapism—Ischaemic and Nonischaemic. According to them in patients with severe ischaemia, as detected by intracorporeal pressure monitoring, blood should be evacuated by a shunt procedure.

It is very agonising condition for the patient and is accompanied by extreme embarrassment demanding urgent measures.

Case Report

A 45 years old man was brought to the emergency with persistent painful erection of penis of six days duration and acute retention of urine for two days. Onset of erection was not related to any sexual act. There was no history of any spinal trauma. Patient was apparently in good health. The only positive findings were a fully erect penis and the distended urinary bladder (Fig. 1).

Nervous system was normal. There was no evidence of any local pathology of penis. On rectal examination prostate was normal. Haemogram did not show any leukaemia or sickling.

An injection of $\frac{1}{4}$ grain of Morphine was given. The penis was covered with an ice pack. In operating room epidural anaesthesia was tried but it failed to relieve him. It was followed

by spinal anaesthesia, which too was ineffective. So a final diagnosis of idiopathic priapism was made. It was decided to go ahead and perform a Saphenocorporal shunt. Urine was diverted by a suprapubic cystostomy. A vertical incision of 12 cm. extending downward from the medial edge of the right inguinal ligament was made through the skin and subcutaneous tissue. A length of 10 cm. of long saphenous vein was exposed. The tributaries of the vein were ligated and divided. A fine bull dog clamp was placed at the distal most point of the vein. The saphenous vein was divided between the bull dog clamp and a distal ligature. The vein was flushed with heparin solution.

A 4 cm. long incision was made on the right lateral aspect of the base of penis. Corpus cavernosum was exposed. Small ellipse of cavernous tissue was excised. The penis was gently squeezed to evacuate the thick black colored blood. A thick needle was used to irrigate the corpus cavernosum by heparin solution. By inserting a finger a tunnel was made under the intervening skin between the groin and penile incisions. The distal end of the saphenous vein was cut obliquely and brought to the penile incision through the tunnel. An anastomosis was carried out between the cut end of saphenous vein and opening of the corpus cavernosum by a continuous 6/0 prolene suture.

The penis gradually became flaccid, but still was grossly oedematous (Fig. 2). The two incisions were closed.

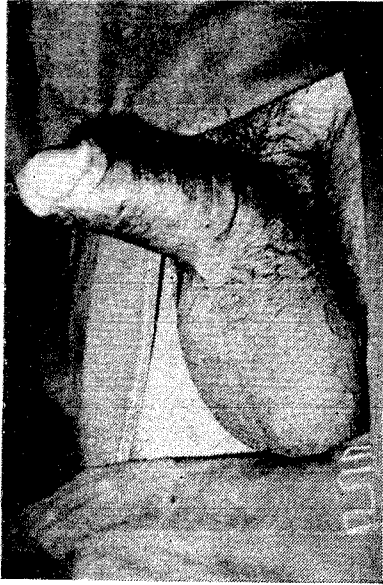

Fig. 1. Erect Penis—Pre-operative.

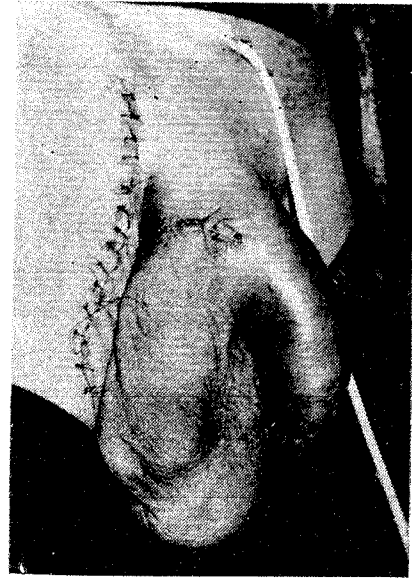


Fig. 2. Immediate Post-operative.

The post-operative period was uneventful. The stitches and suprapubic catheter were removed on the 7th day. The patient started passing urine normally. Oedema of the penis settled after about three weeks. The patient was quite satisfied with the procedure.

Discussion

During the past decades many new conservative and operative treatments have been described for idiopathic priapism. Grace and Winter (1968) in a collected series of 23 patients of priapism found nine patients had repeated sustained erections of penis. Most of these cases subsided spontaneously. Maria and Haricharan (1984) reported a case of idiopathic priapism of eight days duration in a 35 years old patient treated by a bilateral saphenocavernous shunt. In our case a unilateral

shunt was found to be adequate. Among the various procedures Greyhack's saphenocavernous shunt has stood the test of time. If performed within 24 hours, return of normally erectile penis can be assured. If resolution of priapism is not prompt, the shunt can be supplemented by catheterisation and continuous suction of corpora cavernosa (Duback and Ramey, 1968). This has been done with success in Sickle cell trait, but can as well be done in case of idiopathic priapism.

Conclusion and Result

The above case has been followed up for a year now. He had no further episodes of Priapism. He is able to get partial erection, perhaps just enough to perform the sexual act.

REFERENCES

1. DUBACK, R. T. AND RAMEY, J. A. : Priapism in Sickle cell trait : Case report utilising hemovac suction as an adjunct to therapy. *J. Urol*, 1968; 100 : 175.
2. GRACE, D. A. AND WINTER, C. C. : Priapism : An appraisal of management of 23 patients. *J. Urol*, 1968; 99 : 301.
3. MARIA AND HARICHARAN, A. I. : Priapism : A case report. *Ind. J. of Surgery*, 1984; 46 : 49.

4. LEE, T. F., HELSTROM, W. J. G., McANINCH, J. W. AND TONAGHO, E. A. : Priapism : Refined approach to diagnosis and treatment. J. of Urol, 1986; 136 : 194.

The Authors

DR. R. BHARAT, M.Ch. (Plastic Surgery), *Associate Plastic Surgeon.*

DR. B. P. SENGUPTA, M.S., *Senior Surgeon.*

DR. M. N. BHAT, M.S., *Senior Surgeon.*

Department of Surgery, Tata Main Hospitals, Jamshedpur.

Request for Reprints

DR. R. BHARAT, 66, Rajendranagar, Sakchi, Jamshedpur - 831001.