

## THE DORSO-LATERAL FLAP IN POST BURN FLEXION CONTRACTURE OF FINGERS

A. K. SINGH, G. S. KALRA AND S. D. PANDEY

### SUMMARY

*Volar defects of the fingers can be resurfaced by a flap from the dorso-radial or dorso-ulnar aspect of the same finger. Its use following release of twenty-one post burn flexion contracture of the fingers in fifteen patients has been discussed.*

Post burn contracture of the PIP joint is not an uncommon sequelae of burns involving the volar aspect of fingers. It is preventable by proper splintage, early resurfacing (Cannon and Zuidema, 1959; Salisbury and Pruitt, 1976) and vigorous physiotherapy (Boswik, 1974).

If the scar is narrow and linear, it can be released by single or multiple "Z" plasties (McGregor, 1967). Wide scars and severe contractures are not amenable to "Z" plasty. Following release of contracture, the raw area can be covered by skin-grafts or graft from sole (Glanz, 1960, Micks et al., 1967). Local flaps from the same finger, viz. the lateral finger flap (Green, 1979), dorso-lateral flap (Joshi, 1972) and flaps from the adjacent finger, in the form of cross finger flap (Curtis, 1957) and flag flap (Villain, 1973) have been used. Distant flaps from abdomen (Kelleher, 1970), from opposite arm (McGash, 1956), have also been used for large defects.

Skin grafts have tendency to contract and hence require long period of immobilisation. Moreover, graft can not be applied over denuded tendon or exposed joints. Hence flaps, preferably 'local flaps' should be used. Distant flaps are multistaged procedures and require long periods of immobilisation. Same is true for cross finger flaps.

Joshi (1972), has used skin of the dorsal and ulnar or radial side of the finger to resurface

the raw area created after release of flexion contracture. We found the concept interesting and decided to use it clinically.

### Design of flap

The first step consists of marking the dimensions of the flap. Size of the flap required is measured by drawing two perpendicular lines, from the point of maximum contracture, towards the dorsum of the finger (Fig. 1).

The flap is taken from the dorsum and side of the finger. Depending on the finger involved, the flap is taken either from the radial or ulnar side. For instance, in the index finger the flap is taken from the ulnar side (dorso-ulnar flap) whereas in the little finger from the radial side (dorso-radial flap). Thus there is no scarring over the more important side of the finger.

Unless the volar skin is badly scarred, it is included in the flap (Fig. 2). The flap is elevated protecting the neurovascular bundle. The dorsal digital vessels and nerve are included in its base (Joshi, 1972). Skin superficial to the deep fascia of extensor expansion is taken with the flap (Fig. 3). Following release of contracture, the flap is transposed and sutured to the defect (Fig. 4). When the defect is large, the joint is covered with the flap and the remaining area is grafted with thick split skin graft (Fig. 5). A bolus dressing and plaster of paris cast are applied.

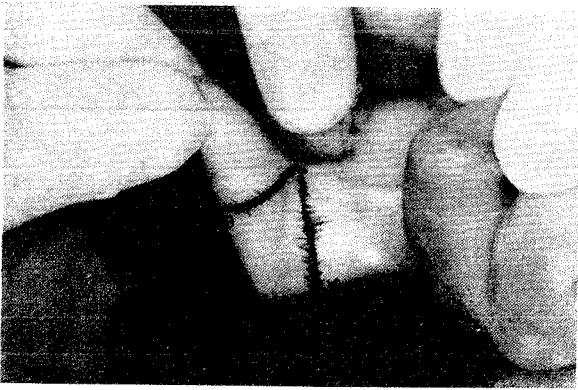


Fig. 1. Showing contracture of middle finger PIP joint.  
A-B=Size of the flap.

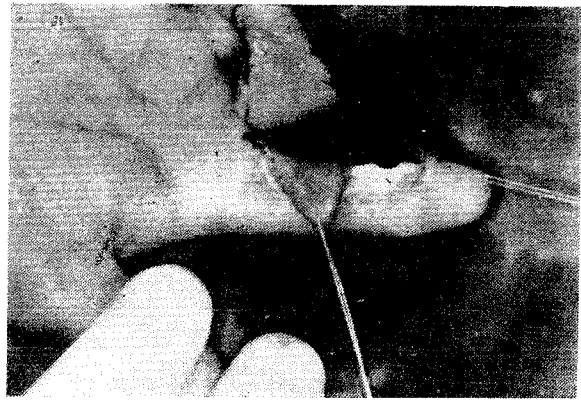


Fig. 2. Showing marking of the flap in the middle finger. A dorso-ulnar flap has already been elevated in the index finger.

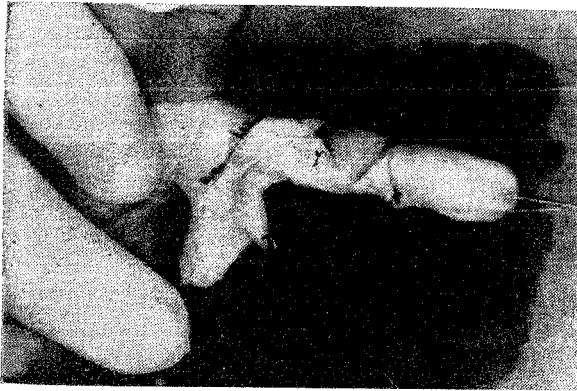


Fig. 3. Contracture has been released and the flap (dorso-radial) elevated.

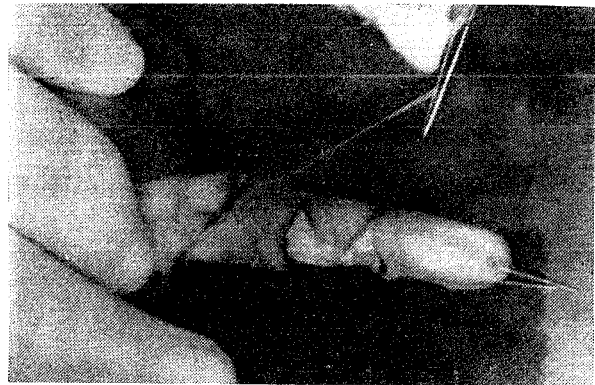


Fig. 4. Showing transposition of flap to cover the PIP joint.

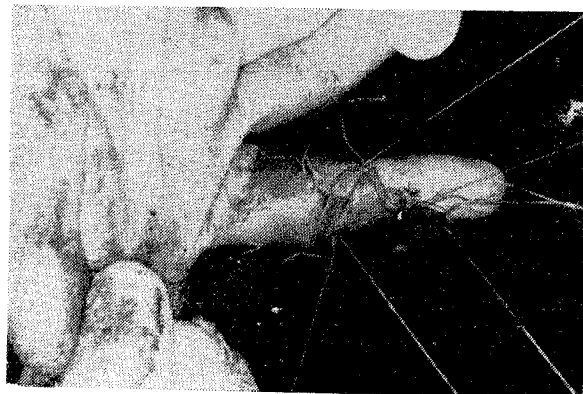


Fig. 5. Remaining raw area grafted with thick split skin graft.

### Observations

21 flaps have been used in 15 patients with post burn contracture of PIP joints. Patients having gross scarring of the dorsal skin as well, were considered unsuitable for this procedure.

In all but 3 fingers, full correction could be achieved, where the neurovascular bundle was also short. During the release of contracture, the flexor tendon got exposed in 5 patients and it was covered by the dorso-lateral flap. Maximum size of the flap used was  $2.0 \times 3.1$  cm. No necrosis of the flap was observed. Donor area had some skin loss in 2 fingers but it healed in about a week's time. Good functional result was obtained in all the cases.

### Discussion

Release of moderate and severe flexion contracture of finger requires a flap cover, as skin grafts contract and result in recurrence of the deformity (Beasley, 1967, 1970 and Portar, 1968). Distant flaps, like the abdominal flap (Kelleher 1970), cross arm flap (McGash, 1956), are multistaged procedures, require long period of immobilisation predisposing to joint stiffness, besides causing considerable inconvenience to

the patient. The flap is not sensory and the skin is thick. Same is true for cross finger flaps (Curtis, 1958) and flag flaps (Villain, 1973).

The development of dorso-lateral flap (Joshi, 1972) has made available enough local tissue which can be used as transposition flap to reconstruct volar defect. The procedure is simple and can be done even under local anaesthesia as an out patient procedure. Early mobilisation of joints is possible and the flap is sensory.

We have not observed any complications during the use of this flap except that if not properly planned, the flap may fall short, but, even in such a situation it is suited to cover the front of a joint, so that skin grafting at this site is obviated. The remaining raw areas are skin grafted. It is also a good flap to cover exposed flexor tendon. However, we feel that this flap should not be used when the dorsal skin is also burnt and some alternate method for resurfacing be employed.

In this study, albeit, the flap has been used in post burn flexion contractures of PIP joints. It can also be used as a cover for volar raw areas of the fingers.

### REFERENCES

1. BEASLEY, R. W. : Principles and Techniques of resurfacing operations in hand surgery. *Surg. Clinic North Am.*, 1967; 47 : 389.
2. BEASLEY, R. W. : Local flaps for surgery of the Hand. *Ortho. Clinic North Am.*, 1970; 2 : 219.
3. BOSWICK, J. A. JR. : Rehabilitation of the burnt hand. *Clinic Ortho.*, 1974; 104 : 162.
4. CURTIS, R. M. : Cross finger pedicle flap in hand surgery. *Ann. Surg.*, 1957; 145 : 650.
5. CANNAN, B. AND ZUIDEMA, G. D. : The care and the treatment of the burnt hand. *Clinic Ortho.*, 1959; 15: 111.
6. GLANZ, S. : Repair of the contractures of the hand with pedal full thickness skin grafts. *Am. J. Surg.*, 1960; 100 : 412.
7. GREEN, D. P. AND DOMINGUEZ, O. J. : A transposition skin flap for the release of volar contracture of skin at M. P. Joint. *Plast. Recons. Surg.* 1979; 64 : 516-520.
8. JOSHI, B. B. : Dorso-lateral flap from same finger to relieve flexion contracture. *Plast Recons. Surg.* 1972; 49; 186-189.
9. KELLEHER, S. C. ET AL. : Use of tailored abdominal pedicle flaps for surgical reconstruction of the hand. *J. Bone, Surg.*, 1970; 52-A: 1552.
10. MCGASH, C. R. : Cross arm bridge flap in the repair of flexion contracture of the finger. *British J. Plast. Surg.* 1956; 9 : 25-33.
11. MCGREGOR, I. A. : The Z-plasty in hand surg. *J. Bone Joint Surg.* 1967; 49-B, 498.
12. MICKS, J. E. AND WILSON, J. N. : Full thickness sole skin grafts for resurfacing the hand. *J. Bone joint. Surg.* 1967; 49-A: 1128.

13. PORTAR, R. W. : Functional Assessment of transplanted skin in volar defects of the digits : a comparison between free grafts and flaps. *J. Bone Joint Surg.* 1968; 50-A, 955.
14. SALISBURY, R. E. AND PRUITT, B. A. : Burns of the upper extremity, W. B. Saunders Co., Philadelphia, 1976.
15. VILLAIN, R. AND DUPUIS, J. P. : Use of the flag flap for coverage of small area on a finger or the palm. *Plast. Reconst. Surg.* 1973, 51: 397.

### **The Authors**

DR. A. K. SINGH, M.S., M.Ch., *Lecturer*, Plastic Surgery, K. G.'s Medical College, Lucknow.

DR. G. S. KALRA, M.S., D.N.B., *Chief Resident*, Department of Plastic Surgery, K. G.'s Medical College, Lucknow.

DR. S. D. PANDEY, M.S., M.Ch., *Reader*, Plastic Surgery, K. G.'s Medical College, Lucknow.

### **Request for Reprints**

DR. A. K. SINGH, *Lecturer* in Plastic Surgery, K. G.'s Medical College, Lucknow.