

**UNILATERAL HYPERTROPHIC MALE NIPPLE**

A. K. KHANNA AND M. K. MISRA

**SUMMARY**

*A male patient with unilateral hypertrophy of the right nipple, an extremely rare clinical entity is being described.*

A 24 year old University student was seen in our Surgical out-patients department with the only complaint of a big nipple on the right side for many years which was now cosmetically not acceptable as he started to live in the University hostel and the nipple could be seen prominent under the vest. It was not congenital and there was no family history of such disease. He was not alcoholic. General examination was not significant. The secondary sexual characters were well developed. The external genitalia were normal. Left breast, left nipple and right breast proper were normal. Right nipple was hypertrophic and projecting without any overlying skin complication or nipple discharge (Figs. 1 & 2). Liver function tests and seminogram were normal. A wedge excision of the nipple was carried out under local anaesthesia. He was reviewed 1 month later. Both nipples were of almost equal size. Histology of the lesion was not conclusive.

We are unaware of any such previously reported case. Sperli (1974) described a technique of cosmetic reduction of the female nipple with functional preservation. In males as there is no functional importance of the nipple so a wedge excision may suffice for correcting the disparity in size.

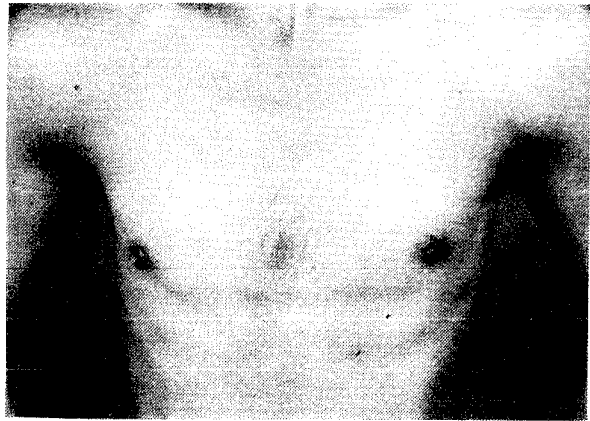


Fig. 1. Close-up view of the chest wall.

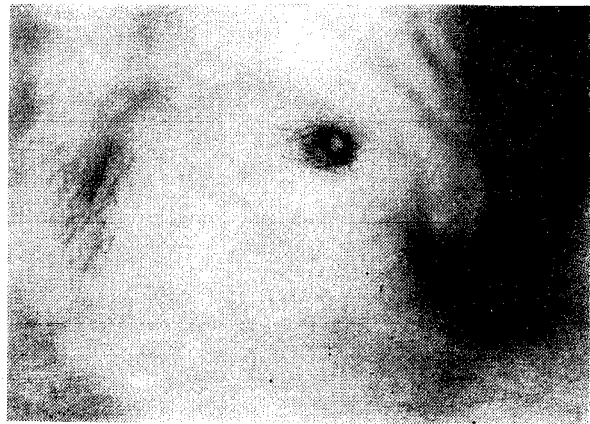


Fig. 2. Close-up view of the nipple.

**REFERENCE**

1. SPERLI, A. E. : Cosmetic reduction of the nipple with functional preservation. *Br. J. Plast. Surg.*, 1974; 27 : 42-43.

**The Authors**

DR. A. K. KHANNA, M.S., M.N.A.M.S., *Lecturer*, Department of Surgery, Institute of Medical Sciences, Banaras Hindu University, Varanasi-221005.

PROF. M. K. MISRA, M.S., F.R.C.S., F.A.C.S., *Professor*, Department of Surgery, Institute of Medical Sciences, Banaras Hindu University, Varanasi-221005.

**Request for Reprints**

DR. A. K. KHANNA, Department of Surgery, Institute of Medical Sciences, Banaras Hindu University, Varanasi-221005.