



Intracranial Cavernous Malformation with Concomitant Isolated Cerebral Mucormycosis Infection: A Case Report

Pratishtha Sengar¹ Nityanand Pandey² Vikas Kailashiya¹ Varun Kumar Singh³

¹Department of Pathology, Institute of Medical Sciences, Banaras Hindu University, Varanasi, Uttar Pradesh, India

²Department of Neurosurgery, Institute of Medical Sciences, Banaras Hindu University, Varanasi, Uttar Pradesh, India

³Department of Neurology, Institute of Medical Sciences, Banaras Hindu University, Varanasi, Uttar Pradesh, India

Address for correspondence Pratishtha Sengar, MBBS, DNB, Department of Pathology, Institute of Medical Science, Banaras Hindu University, Varanasi, 221005, Uttar Pradesh, India (e-mail: pratishthasengar@gmail.com).

Asian J Neurosurg

Abstract

Cerebral cavernous malformation is an angiographically occult, well-circumscribed, benign hamartoma consisting of thin-walled sinusoidal vascular channels. Intracranial mucormycosis represents one of the most severe manifestations of mucor infection. We, hereby, report a case of cavernous malformation made rarer with concomitant mucormycosis. A 22-year-old female presented with left-sided facial seizures since age of 7 years and headache for the past 3 years. Magnetic resonance imaging brain revealed a right posterior frontal lobe cavernous malformation. Right frontal craniotomy with excision of cavernoma was done. Gross examination showed a solid cystic mass with multiple mulberry protrusions. Histopathological examination revealed features of cavernous malformation with evidence of mucormycosis. A final diagnosis of cavernous malformation with mucormycosis was rendered and microbiological studies were advised. To the best of our knowledge, this is the first case report of a cerebral cavernous malformation with mucormycosis in an immunocompetent patient without any risk factor.

Keywords

- ▶ cerebral cavernous malformation
- ▶ isolated cerebral mucormycosis
- ▶ seizure
- ▶ magnetic resonance imaging
- ▶ antiepileptic drugs

Introduction

Vascular malformations of central nervous system encompass a variety of lesions like cerebral cavernous malformation (CCM), arteriovenous malformation, and capillary telangiectasia and venous angiomas. CCMs are angiographically occult, well circumscribed, benign hamartoma consisting of thin-walled sinusoidal vascular channels but lacking large feeding arteries or large draining veins. They can be solitary or multiple (50% of cases) and are usually detected

on magnetic resonance imaging (MRI). Mucormycosis is a rare, and fatal opportunistic fungal infection caused by members of Mucorales family.¹ It often occurs in patients with immunocompromised state like hematological malignancies, organ transplantation, diabetic ketoacidosis, or with history of intravenous drug abuse.² Isolated cerebral mucormycosis (ICM) accounts for 8% of all mucormycosis cases.³ The clinical symptoms of ICM are illusive and hence high index of suspicion should be kept based on clinical and

DOI <https://doi.org/10.1055/s-0043-1772765>.
ISSN 2248-9614.

© 2023. Asian Congress of Neurological Surgeons. All rights reserved.

This is an open access article published by Thieme under the terms of the Creative Commons Attribution-NonDerivative-NonCommercial-License, permitting copying and reproduction so long as the original work is given appropriate credit. Contents may not be used for commercial purposes, or adapted, remixed, transformed or built upon. (<https://creativecommons.org/licenses/by-nc-nd/4.0/>)

Thieme Medical and Scientific Publishers Pvt. Ltd., A-12, 2nd Floor, Sector 2, Noida-201301 UP, India

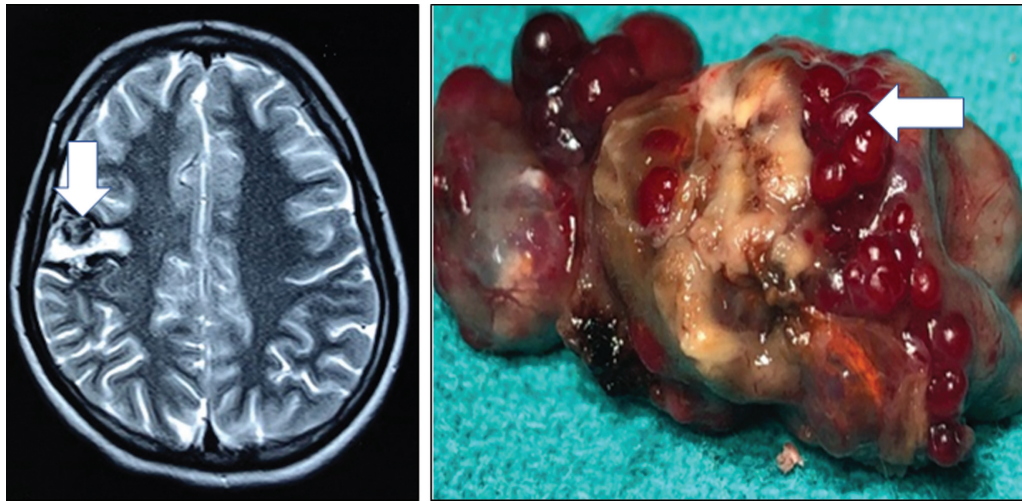

Fig. 1 Magnetic resonance imaging brain showing right posterior frontal heterogeneously hyperintense cortical lesion with intralésional hematoma and thrombosis (white arrow) suggestive of cavernous malformation (A). Resected specimen from right posterior frontal lobe showed a 4 × 3 cm capsulated brownish yellow solid-cystic mass with mulberry like projections (white arrow; B).

radiological findings. Here, we are reporting first case of CCM with concomitant ICM in a young immunocompetent female without any risk factors.

Case History

A 22-year-old female was presented with left-sided facial seizures since age of 7 years and headache for the past 3 years. Seizure was limited to left half of the face and manifested in the form of twitching movements lasting for 1 to 2 minutes. Frequency of seizure was one to two episodes per day. She was kept on two antiepileptic drugs, oxcarbazepine 600 mg twice daily and clobazam 10 mg once daily from another treating physician. Headache was holocranial, intermittent lasting for 3 to 4 hours and was not associated with nausea, vomiting, photo, and phonophobia. There was no preceding history of fever, loss of weight, and loss of appetite. Past history was negative for tuberculosis, connec-

tive tissue disease, or glucocorticoid use. Family history was negative for similar illness. Menstrual history was normal.

On general examination, her blood pressure was 120/70 mm Hg and pulse rate 80 per minute. There was no pallor, icterus, cyanosis, pedal edema, or lymphadenopathy. Cardiovascular, respiratory, and abdominal examinations were within normal limits. Neurological examination also did not reveal any cranial nerves, motor, sensory, or cerebellar abnormality.

On laboratory evaluation, her complete blood count, liver, renal and thyroid function test were unremarkable. MRI brain revealed a contrast enhancing lesion with evidence of bleed in right posterior frontal lobe suggestive of cavernous malformation (► Fig. 1).

Patient underwent right frontal craniotomy with excision of cavernoma. Gross examination showed a 4 × 3 cm solid cystic mass with multiple mulberry protrusions (► Fig. 2). Histopathological examination revealed features of cavernous

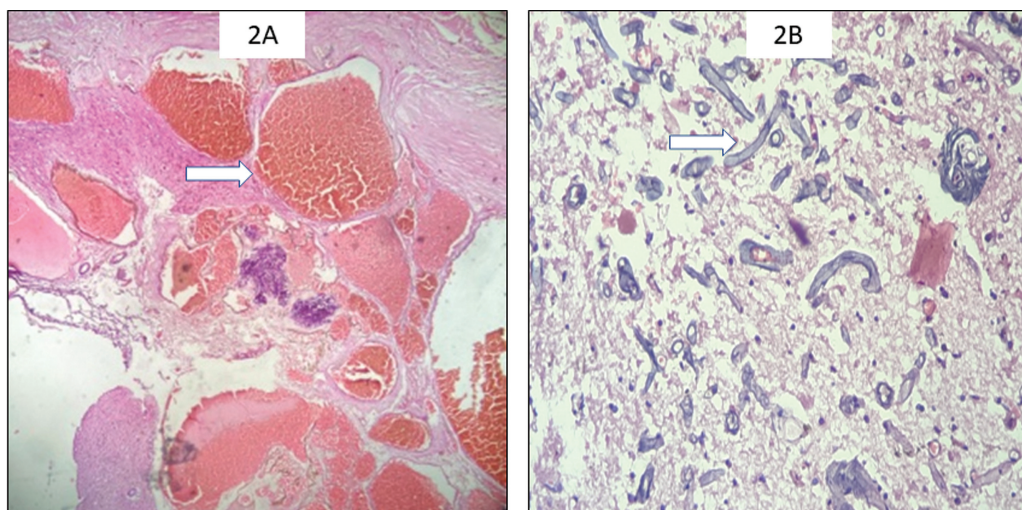


Fig. 2 Resected lesion composed of many closely packed anastomosing congested vascular channels having no muscularization. Some of the channels showed presence of fresh thrombus (white arrow) (20 × , hematoxylin and eosin [H&E]) (A). Peripheral glial tissue showed presence of broad aseptate hyphae of mucormycosis branching at 90 (white arrow) (400 × , H&E) (B).

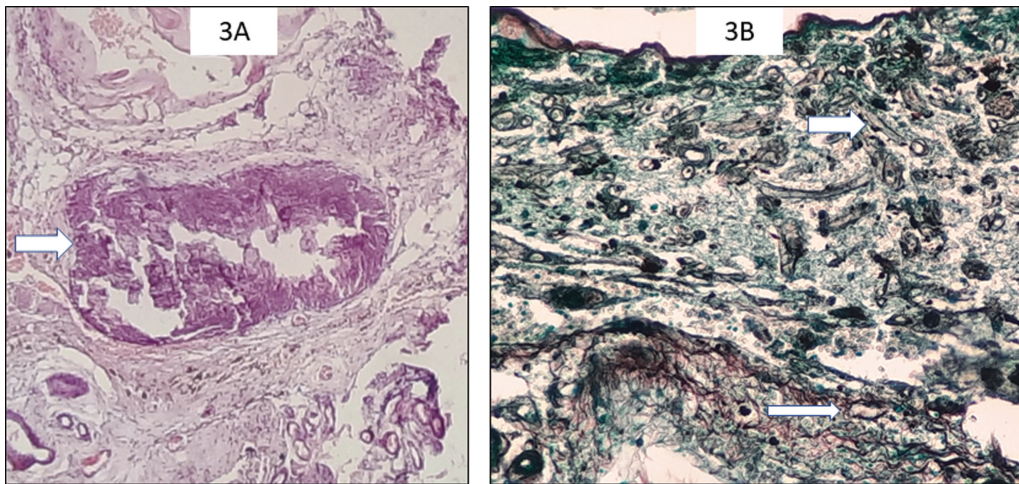


Fig. 3 Few vessels were obliterated with the Mucor colonies and showed calcification (*white arrow*) ($400\times$, hematoxylin and eosin) (A). Gomori methenamine silver (GMS) staining highlights the broad aseptate hyphae of mucormycosis and also the calcified vessel wall getting infiltrated by fungal hyphae (*white arrow*) ($400\times$, GMS) (B).

malformation with evidence of broad aseptate 90° branching fungal hyphae conforming to the morphology of mucormycosis (**Fig. 3**). Adjacent scant brain parenchyma also revealed fungal infiltration along with reactive gliosis. Few foci of angioinvasion were seen. Hence, a final diagnosis of cavernous malformation with mucormycosis fungal infection was made.

Postoperatively patient was doing well without any apparent focal neurological deficit. She was investigated in detail to rule out any source of the fungal infection. However, her chest X-ray, ultrasound abdomen, and two-dimensional (2D) echocardiography did not reveal any abnormality. Her blood and urine culture were sterile. She also underwent detailed otorhinolaryngology evaluation to rule out occult source of infection that came out negative. Patient was discharged on 2 antiepileptic drugs, oxcarbazepine 600 mg twice daily and clobazam 10 mg once daily. Opinion was taken from neurologist and microbiologist regarding antifungals, which was not given considering no other foci of infection evidenced by normal clinical and radiological evaluation. At 2 months of follow-up, oxcarbazepine was tapered to 450 mg twice daily and clobazam was stopped. She was doing well without any occurrence of fresh seizures.

Discussion

In the present case, a young female presented with left-sided focal seizure and was not responsive to two antiepileptic drugs. MRI brain revealed right posterior frontal cavernous malformation. However, on excision of cavernoma, histopathological examination showed evidence of mucormycosis within the lesion as well as intervening glial tissue. Such combination of cavernous malformation with ICM has not been found in the available English literature.

ICM is rare in healthy and immunocompetent individuals.^{4,5} ICM in immunocompetent adults must fulfil three criteria: (1) Isolated cerebral localization; (2) identification of Mucorales by culture, polymerase chain reaction or characteristic broad based aseptate hyphae on pathology from brain biopsy or

autopsy sample; (3) immunocompetent host.⁶ Our case fulfilled all the above criteria of ICM in an immunocompetent individual. Detailed clinical, laboratory, and radiological examination did not reveal any underlying systemic disease or predisposing condition. Intravenous drug abuse has been reported to be the commonest risk factor in patients with ICM, but in present case even such history of addiction was absent.⁶

Concomitant CCM with fungal infection is an extremely rare occurrence. Sun et al reported a case of 60-year-old male with a history of meningioma-induced seizure 3 years back. MRI brain revealed brain abscess in addition to meningioma. Patient underwent antibiotic treatment with resection of meningioma. Later on, due to appearance of new focal deficit and expansion of the previous lesion, surgical resection was done. Resected specimen revealed aspergillus fumigatus infection complicating cavernous haemangioma.⁷ Similarly in our case, mucormycosis complicating cavernous malformation was detected. Localization of fungal infection to the cerebral cavernoma without any other foci of infection might be due to a state of equilibrium between mucor infection and body's immunity as proposed by Sun et al.⁷

Conclusion

To the best of our knowledge, this is the first case report of a CCM with mucormycosis in an immunocompetent patient without any risk factor.

Informed Consent

The written informed consent was taken from the parents of the patient.

Authors' Contribution

Pratishtha Sengar was involved in writing of the manuscript and data collection. Nityanand Pandey helped in editing of the manuscript and data collection. Vikas Kailashiya was involved in conceptualization and designing of the study

and writing the manuscript. Varun Kumar Singh analyzed the data and reviewed the manuscript.

Funding

None.

Conflicts of Interest

None declared.

Acknowledgement

We acknowledge the patient's parents for giving consent for participating in this study.

References

- 1 Teixeira CA, Medeiros PB, Leushner P, Almeida F. Rhinocerebral mucormycosis: literature review apropos of a rare entity. *BMJ Case Rep* 2013;2013:bcr2012008552
- 2 Zhang GJ, Zhang SK, Wang Z, et al. Fatal and rapid progressive isolated cerebral mucormycosis involving the bilateral basal ganglia: a case report. *Front Neurol* 2020;11:295
- 3 Roden MM, Zaoutis TE, Buchanan WL, et al. Epidemiology and outcome of zygomycosis: a review of 929 reported cases. *Clin Infect Dis* 2005;41(05):634–653
- 4 Sweeney PJ, Hahn JF, McHenry MC, Mitsumoto H. Mucormycosis presenting as positional nystagmus and hydrocephalus. *Case report. J Neurosurg* 1980;52(02):270–272
- 5 Verma A, Brozman B, Petito CK. Isolated cerebral mucormycosis: report of a case and review of the literature. *J Neurol Sci* 2006;240(1-2):65–69
- 6 Meyerowitz EA, Sanchez S, Mansour MK, Triant VA, Goldberg MB. Isolated cerebral mucormycosis in immunocompetent adults who inject drugs: case reports and systematic review of the literature. *Open Forum Infect Dis* 2020;7(12):ofaa552
- 7 Sun Y, Yu J, Li G, Huang H. Intracranial aspergillus fumigatus infection complicated with cavernous hemangioma: case report and literature review. *Int J Clin Exp Med* 2015;8(11):20524–20531