


Irresistible Laughter—A Rare Presentation of Intracranial Tumor: Irony of Neurocircuitry

Kirandeep Kaur¹ Nidhi B. Panda¹ Shalvi Mahajan²  Tulasi Ram³

¹Division of Neuroanaesthesia, Department of Anaesthesia and Intensive Care, Postgraduate Institute of Medical Education and Research, Chandigarh, India

²Department of Anaesthesia and Intensive Care, PGIMER, Chandigarh, India

³Department of Neurosurgery, Postgraduate Institute of Medical Education and Research, Chandigarh, India

Address for correspondence Nidhi B. Panda, MD, Department of Anaesthesia and Intensive Care, Division of Neuroanaesthesia, Postgraduate Institute of Medical Education and Research, Chandigarh 160015, India (e-mail: nidhibp@gmail.com).

Asian J Neurosurg 2024;19:347–348.

Pseudobulbar affect (PBA) is defined as episodes of unprovoked uncontrollable laughter or crying not related to an emotional or environmental stimulus. PBA has been associated with various neurological diseases, drugs, movement

disorders, stroke, posttraumatic brain injury, and intracranial lesions including cerebellopontine angle (CPA) tumors.¹

A 29-year-old female presented with holo-cranial headaches and outbursts of uncontrolled laughs. Magnetic resonance

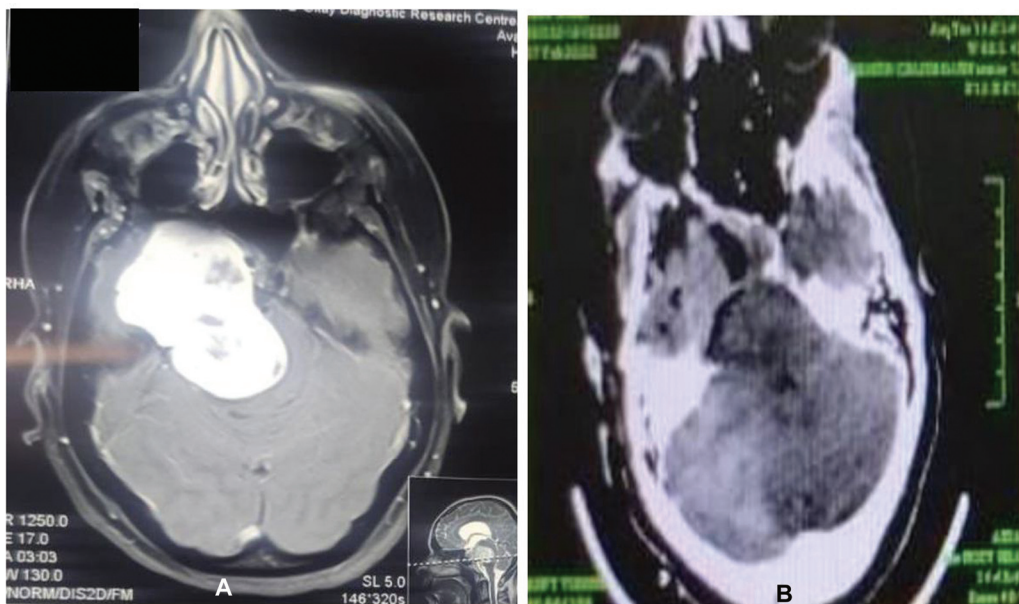


Fig. 1 (A) MRI with contrast showed a dumbbell-shaped extra-axial mass in the middle and posterior cranial fossa extending from the right cerebellopontine angle having cystic and hemorrhagic components. (B) NCCT head in the axial cut in the immediate postoperative period. MRI, magnetic resonance imaging; NCCT, noncontrast computed tomography.

article published online
May 27, 2024

DOI <https://doi.org/10.1055/s-0043-1772767>.
ISSN 2248-9614.

© 2024, Asian Congress of Neurological Surgeons. All rights reserved.

This is an open access article published by Thieme under the terms of the Creative Commons Attribution-NonDerivative-NonCommercial-License, permitting copying and reproduction so long as the original work is given appropriate credit. Contents may not be used for commercial purposes, or adapted, remixed, transformed or built upon. (<https://creativecommons.org/licenses/by-nc-nd/4.0/>)

Thieme Medical and Scientific Publishers Pvt. Ltd., A-12, 2nd Floor, Sector 2, Noida-201301 UP, India

imaging findings were suggestive of a $5.5 \times 4.9 \times 3.7$ cm solid and cystic lesion in the right CPA compressing on the brainstem (**Fig. 1A**). Preoperative investigations were normal. A standard anesthetic technique for intraoperative neuromonitoring was used to facilitate electromyography of lower cranial nerves. Through a right frontotemporoorbitozygomatic craniotomy a yellowish-grey suckable tumor was seen between maxillary and mandibular divisions of cranial nerve V. Posterior fossa was entered and gross total excision of tumor extending to ventral part of brainstem was done (**Fig. 1B**). Histopathological examination of the resected tumor confirmed the trigeminal schwannoma. In the postoperative period, there was complete resolution of her psychiatric symptoms.

Large intracranial lesions are thought to be responsible for the “release phenomenon” causing loss of control of the lower brainstem from the higher centers manifesting as psychiatric mimics.² Why not all patients have PBA remains elusive?³ Not one particular area has been ascribed to the presentation, but various areas postulated to be involved are the periaqueductal region, and lateral pons with anatomical relations to the frontal, basal temporal, hypothalamus, basal ganglia, thalamus, cerebellum, and upper cervical spinal cord. Awareness of such odd presentations can help in prompt management, avoiding unwanted consultations, and additional preoperative anxiolytics, considering it a manifestation of higher levels of anxiety.

Thus, behind this reversible psychiatric presentation, there may be a large intracranial pathology requiring early

management by tumor resection. Neuroanesthesiologists should be well versed in this rare exposition that mimics psychiatric symptomatology.

Patients' Consent

Patient consent was obtained for the publication of clinical information and images to enhance medical knowledge.

Authors' Contributions

K.K. helped review the literature and prepare the manuscript. N.B.P. helped review and approve the final version of the manuscript. S.M. helped design, review the literature, and prepare the manuscript. T.R. helped review and approve the final manuscript.

Conflict of Interest

None declared.

References

- 1 Wortzel HS, Oster TJ, Anderson CA, Arciniegas DB. Pathological laughing and crying : epidemiology, pathophysiology and treatment. *CNS Drugs* 2008;22(07):531–545
- 2 Wild B, Rodden FA, Grodd W, Ruch W. Neural correlates of laughter and humour. *Brain* 2003;126(Pt 10):2121–2138
- 3 Gosal JS, Pandey S, Das KK, et al. Pathologic laughter as an early and unusual presenting symptom of petroclival meningioma: a case report and review of the literature. *World Neurosurg* 2019; 123:161–164