

NON-OSSIFYING FIBROMA OF MAXILLA—A CASE REPORT

HARSH SHARMA, S. P. AGARWAL AND D. DAYAL

SUMMARY

A rare case of non-ossifying fibroma of the maxilla is being reported alongwith the review of literature.

(*Key Words* : Fibromas, Maxillary tumors)

Non-ossifying fibroma or desmoplastic fibroma is a rare tumor of the jaw. In the region of the face, it mostly involves the lower jaw (Table). However, Sood and Chatterjee (1975) have reported one case of maxillary involvement. Another case of maxillary involvement is being reported.

Table—Showing the number of cases of non-ossifying Fibroma of the Jaws

Authors	Year	No. of case	Site
Dechaume, M. et al.	1948	One	Mandible
Mark, H. I.	1955	One	Mandible
Burch, R. J. et al.	1960	One	Mandible
Whiteside, T. E. et al.	1960	One	Mandible
John, G. Griffith et al.	1965	One	Mandible
Fillippo, T.	1967	One	Mandible
Dahlin, D. C. et al.	1967	One	Mandible
Hammer, J. E. III et al.	1968	One	Mandible
Hinds, E. C.	1969	One	Mandible
Martis, C. et al.	1972	One	Mandible
Hovinga, J. et al.	1974	One	Mandible
Badger, C. A. et al.	1974	One	Mandible
Cunningham, C. D. et al.	1975	One	Mandible
Rouchen, G. et al.	1975	One	Mandible
Nassbaum, G. B. et al.	1976	One	Mandible
Wegner, J. E. et al.	1977	One	Mandible
Peede, L. F. et al.	1977	One	Mandible
Sood, V. P. et al.	1975	One	Maxilla
Present	1988	One	Maxilla

Case Report

A 16 year old male presented with a painless progressive swelling on the right side of his face for the last 2 months. There was no history of trauma.

On examination there was a diffuse firm to hard, non-tender, non-pulsatile swelling in the region of the right cheek. Skin over the swelling was normal in appearance, color and temperature (Fig. 1). Sublabial examination revealed expansion of the alveolus on the right side. The hard palate on the same side was bulging, non-tender and firm except at places where it yielded to pressure. The mucosa over it was normal. Anterior rhinoscopy revealed medial shifting of the lateral wall of nose. The floor of the nose was slightly raised.

Radiological examination was not conclusive (Fig. 2).

Biopsy was done by Caldwell Luc's approach. Microscopic examination showed proliferated spindle shaped fibroblasts with fusiform nuclei and acidophilic cytoplasm. They showed little pleomorphism but no mitotic figures. No osteoplastic and osteoclastic giant cells were present (Fig. 3).

Maxillectomy was done and tumor mass along with the anterolateral and medial walls was removed (Fig. 4). Patient could be followed up only for 2 years during which period there was no recurrence.

Discussion

Non-ossifying fibroma is a rare benign, but highly invasive tumor of the maxilla with tendency to recur after treatment. It may involve the vital structures and may be fatal (John, et al., 1965).

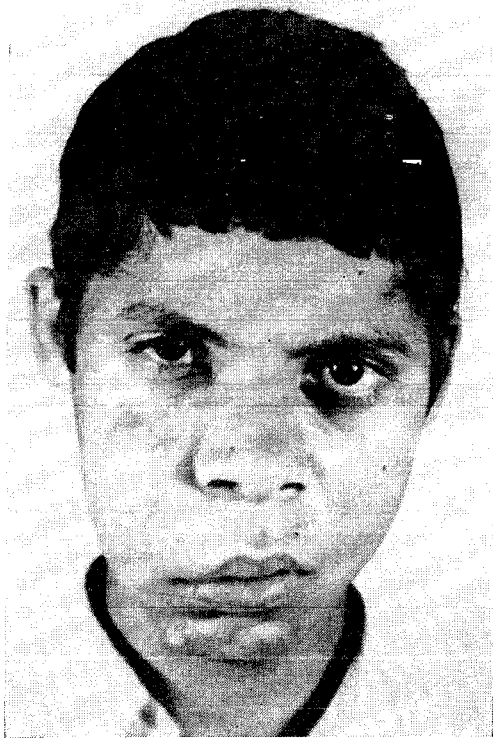

Fig. 1. Shows diffuse swelling in the region of right cheek.

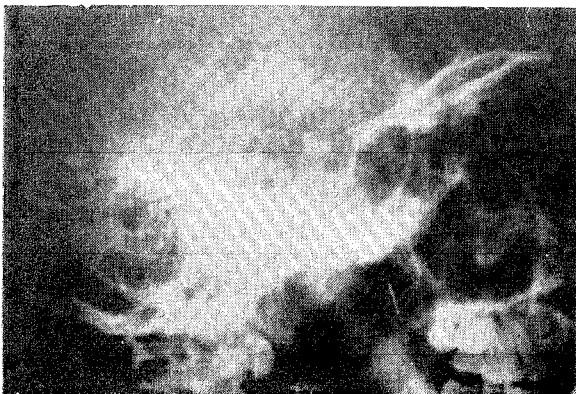


Fig. 2. Shows expansion of anterolateral wall of maxillary sinus with erosion.

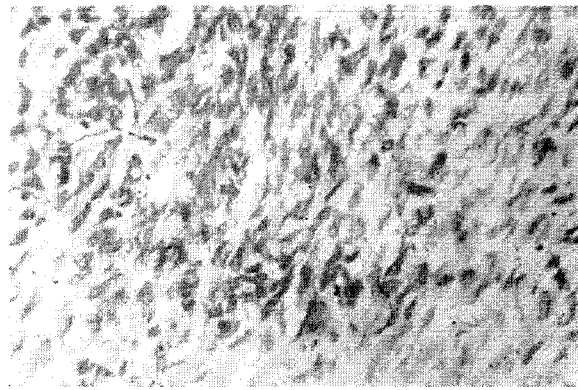


Fig. 3. Shows proliferated spindle shaped fibroblasts with fusiform nuclei.

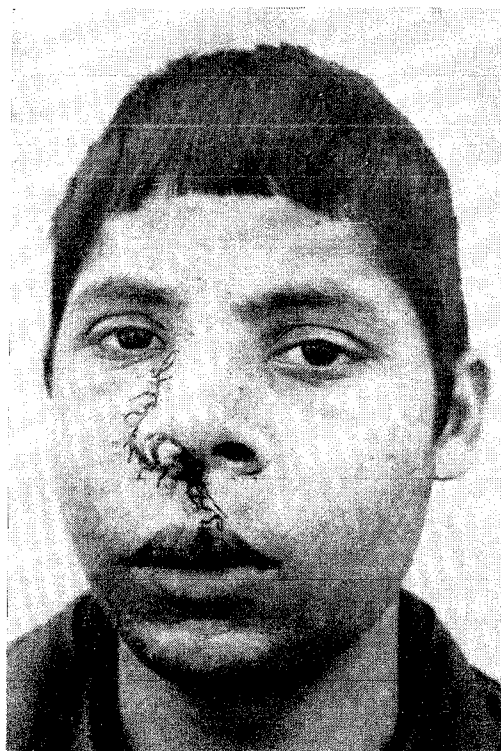

Fig. 4. Shows post-operative condition of the patient.

Etiology of this tumor is unknown but trauma may be a predisposing factor. It is believed to arise from the retained embryonic connective tissue cells of perineural sheath or from the mesenchymal part of the tooth germ.

It is more common in mandible than maxilla

and presents as a slow painless growth in 15-38 years age group. Sudden increase in the tumor may occur.

Radiology shows well defined radiolucent zone with sclerotic border. Some bone reaction may be seen at the periphery. Sometimes

trabeculations may be seen.

On gross examination it was firm to hard growth which was well circumscribed. Microscopic examination showed fibrous tissue with abundant background of collagen matrix and hypocellularity. The fibroblasts were small in size. Mononuclear giant cells or hemorrhagic deposits were not seen. Rare mitosis but no pathological cell division, osteoid tissue or

osseous metaplasia has been reported in the available literature.

The cases have to be treated by wide excision after confirmation of the diagnosis as was done in our case. Radiotherapy is not indicated, but can be used to slow the growth of the lesion that has been subtotally excised in the post-operative period if so desired.

REFERENCES

1. BADGER, C. A., SYED, A. A. AND MALBY, F. C. : Desmoplastic Fibroma of the mandible (1974) quoted by Freedman, P. D. et al. Desmoplastic fibroma of jaw bones. *Oral Med. Oral Surg. Oral Path.*, 1978; 46 : 386.
2. BURCH, R. J., WOODWARD, H. W. : Central fibroma of mandible *J. Oral Surg.*, 1960; 18 : 432.
3. CUNNINGHAM, C. D., SMITH, R. O., ENRIQUEZ, P. AND SINGLETON, G. T. : Desmoplastic fibroma of the mandible a case report (1975) quoted by Freedman, P. D. et al. Desmoplastic fibroma of jaw bones. *Oral Med. Oral Surg. Path.*, 1978; 46 : 386.
4. DAHLIN, D. C. AND HOOVER, N. W. : Desmoplastic fibroma of bone. Report of two cases *J. Amm. Med. Ass.*, 1964; 188 : 685.
5. DECHAUME, M., CHATUT, A. AND BARGAT, P. : In casde fibroma du maxillare in fericure (1948) quoted by Mark H. I. Central fibroma of mandible. *Oral Surg. Oral Med. Oral Path.*, 1955; 8 : 366.
6. FILLIPPO, T., FIBROMA DEL CORPODELLA MANDIBOLA (1952) QUOTED BY MARK, H. I. : Central fibroma of mandible, *Oral Path.*, 1955; 8 : 366.
7. FREEDMAN, P. D., KERPEL, S. M., BEGEL, H. AND LUMERMAN, H. : Desmoplastic fibroma of the jaw bones. Report of a case with review of literature. *Oral Surg. Oral Med. & Path.*, 1978; 46 : 386.
8. HAMMER, J. E. III AND SCOFIELD, H. H. : Benign Osseous Jaw lesions of periodontal membrane origin-an-analysis of 249 cases. *Cancer*, 1968; 22 : 861.
9. HINDS, E. C., KENT, J. N. AND FECHNER, R. E. : Desmoplastic fibroma of the mandible report of a case quoted (1969) by Wanger, J. E. et al. Desmoplastic fibroma of bone. A case in the mandible. *Oral Surg. Med. Oral Path.*, 1977; 43 : 108.
10. HOVINGA, W. N. AND ROSAL, J. : Desmoplastic fibroma in the mandible (1974) quoted by Wagner J. E. et al. Desmoplastic fibroma of bone a case in the mandible *Oral Surg. Oral Med. Oral Path.*, 1977; 43 : 108.
11. JOHN, G. GRIFFITH AND WILLIAM, B. IRBY : Desmoplastic fibroma Report of rare tumor of the oral structures, *Oral Surg. Oral Med. Oral Path.*, 1965; 20 : 269.
12. MARK, H. I. : Central fibroma of mandible, *Oral Surg. Oral Med. Oral Path.*, 1955; 8 : 366.
13. MARTIS, C. AND KARAKASIS, D. : Central fibroma of the Mandible (1955) quoted by Freedman, P. D. et al. Desmoplastic fibroma of jaw bones. *Oral Med. Oral Surg. Oral Path.*, 1978; 46 : 386.
14. MUSGROVE, JAMES, E., MC DONALD, J. AND OHM, R. : Extra abdominal desmoid tumor. *Arch of Pathology*, 1948; 45 : 513.
15. NUSSBAUM, G. B., TERRY, J. J. AND JOY, E. D. : Desmoplastic fibroma of the mandible in a 3 year old child (1976) quoted by Freedman, P. D. et al. Desmoplastic fibroma of jaw bones. *Oral Med. Oral. Surg. Oral Path.*, 1978; 46 : 386.
16. PEEDE, L. F. AND EPKER, B. N. : Aggressive juvenile fibromatosis involving mandible. Surgical excision with immediate reconstruction quoted by Freedman, P. D. et al. Desmoplastic fibroma of jaw bones. *Oral Surg. Oral Med. Oral Path.*, 1978; 46 : 386.
17. RABBAN, W. N. AND ROJAI, J. : Desmoplastic fibroma Report of ten cases and review of literature. *J. Bone and Joint Surg.*, 1968; 50A : 847.
18. ROUCHON, C., BROCHERIOUE, C., COSTA, A. AND JACOB, A. : Fibromes, Desmoides Osseux dela Mandibule a Propos d'un cas (1975) quoted by Freedman P. D. et al. Desmoplastic fibroma of jaw bones. *Oral Surg. Oral Med. Oral Path.*, 1978; 46 : 386.
19. SOOD, V. P. AND CHATTERJEE, A. K. : Desmoplastic fibroma of Maxilla, *J. of Laryngology and Otology*, 1975; 89 : 329.

20. WAGNER, J. E., LORANDI, C. S. AND EBLING, H. : Desmoplastic fibroma of bone. A case in the mandible. Oral Surg. Med Oral Path., 1977; 43 : 108.
21. WHITESIDE, T. E. AND ACHERMAN, L. V. : Desmoplastic fibroma. J. Bone and Joint Surg, 1960; 42A : 1143.

The Authors

DR. HARSH SHARMA, M.S., *Chief resident in E.N.T.*, King George's Medical College, Lucknow.

DR. S. P. AGARWAL, M.S., *Lecturer in E.N.T.*, King George's Medical College, Lucknow.

PROF. D. DAYAL, D.L.O., M.S., *Professor & Head of the Deptt. of E.N.T.*, King George's Medical College, Lucknow.

Request for Reprints

DR. S. P. AGARWAL, M.S. (E.N.T.), Lecturer, Department of E.N.T., King George's Medical College, Lucknow.