



# A Rare Case Report of Simultaneous Occurrence of Chronic Subdural Hematoma and Acute Extradural Hematoma in a Patient after Multiple Ventriculoperitoneal Shunt Surgeries

Vikrant Yadav<sup>1</sup> Ravi Shankar Prasad<sup>1</sup>

<sup>1</sup>Department of Neurosurgery, Institute of Medical Sciences, Banaras Hindu University, Varanasi, Uttar Pradesh, India

Asian J Neurosurg 2023;18:656–660.

Address for correspondence Vikrant Yadav, MBBS, MS, Department of Neurosurgery, Institute of Medical Sciences, Banaras Hindu University, Varanasi, Uttar Pradesh 221005, India (e-mail: vikrantyadav473@gmail.com).

## Abstract

Ventriculoperitoneal (VP) shunt surgeries are common neurosurgical procedure for hydrocephalus. Subdural hematoma (SDH) and extradural hematoma (EDH) are rare but potentially life-threatening complications following VP shunt surgeries. We are describing probably the first case in which a 12-year-old boy presented to the emergency room in altered sensorium and gradual onset quadriplegia following multiple shunt revision procedures done in an outside hospital. Computed tomography head showed chronic right-sided frontotemporoparietal chronic SDH and parietal dominant EDH simultaneously with multiple shunt systems in ventricles. Patient was taken for surgery in emergency and emergent evacuation of hematoma was done. Patient improved in the postoperative period. In this case report we will make an attempt to describe a rare complication of VP shunt surgery and possible mechanisms responsible for it.

## Keywords

- ▶ extradural
- ▶ hematoma
- ▶ hydrocephalus
- ▶ subdural
- ▶ ventriculoperitoneal shunt

## Introduction

Ventriculoperitoneal (VP) shunt surgery is a very common neurosurgical procedure in the continuum of relatively high prevalence of hydrocephalus in our country. In the Indian context, VP shunts are most commonly used to treat hydrocephalus.<sup>1</sup> Shunt surgeries are associated with many complications. Excessive drainage is one of those complications which has significant impact on the neurological status of the patients. Chronic subdural hematoma (SDH) and extradural hematoma (EDH) are potentially life-threatening complications of excessive drainage occurring usually over different time periods.<sup>2,3</sup> Occurrence of both entity simultaneously in a

patient is extremely rare. Hereby, we report a case of a 12-year-old boy who presented to the emergency room in altered sensorium and gradual onset quadriplegia following multiple shunt revision for congenital hydrocephalus secondary to aqueductal stenosis and his initial computed tomography (CT) head scans showed simultaneous occurrence of chronic SDH on the right side and EDH on the left side.

## Case Illustration

A 12-year-old boy presented to the emergency room as a referred case from other hospital in altered sensorium and gradual onset quadriplegia following left-sided VP shunt

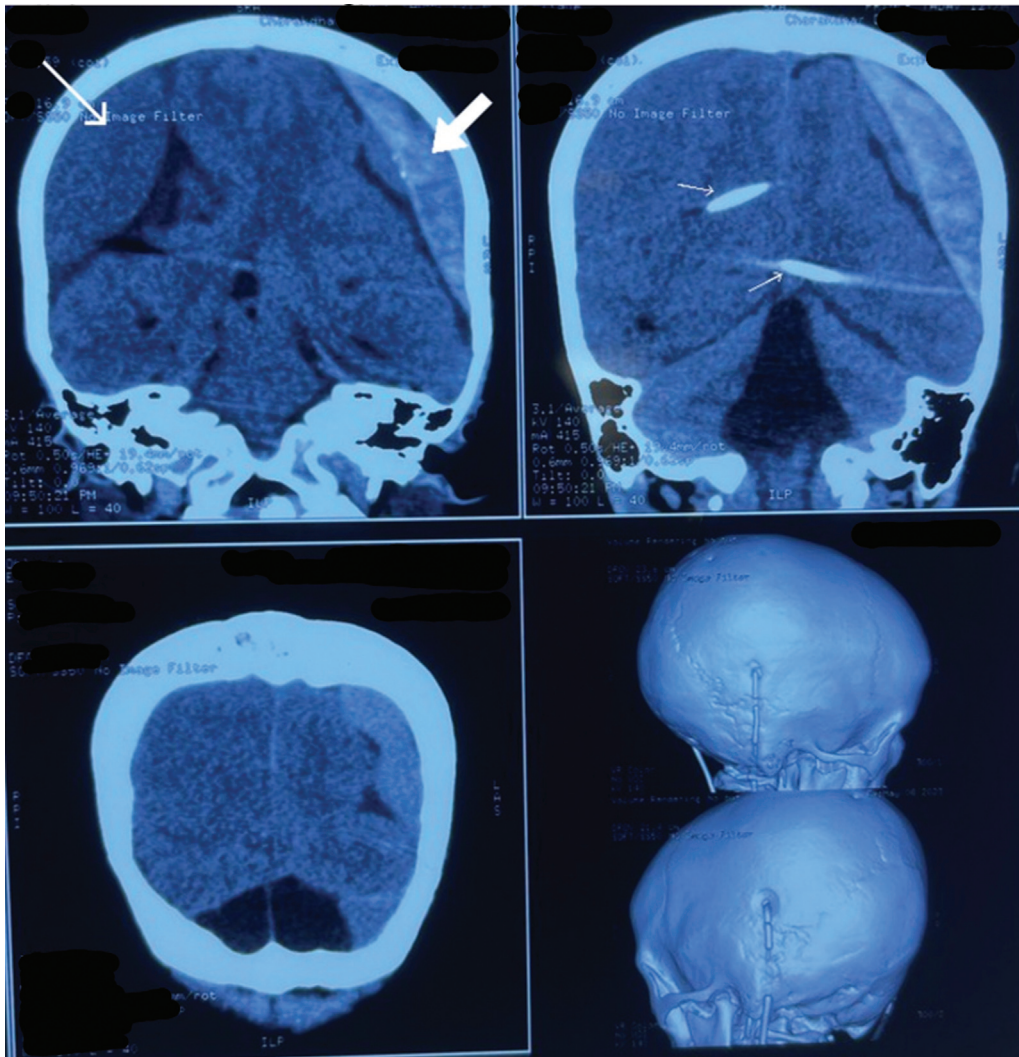
article published online  
September 13, 2023

DOI <https://doi.org/10.1055/s-0043-1773765>.  
ISSN 2248-9614.

© 2023. Asian Congress of Neurological Surgeons. All rights reserved.

This is an open access article published by Thieme under the terms of the Creative Commons Attribution-NonDerivative-NonCommercial-License, permitting copying and reproduction so long as the original work is given appropriate credit. Contents may not be used for commercial purposes, or adapted, remixed, transformed or built upon. (<https://creativecommons.org/licenses/by-nc-nd/4.0/>)

Thieme Medical and Scientific Publishers Pvt. Ltd., A-12, 2nd Floor, Sector 2, Noida-201301 UP, India



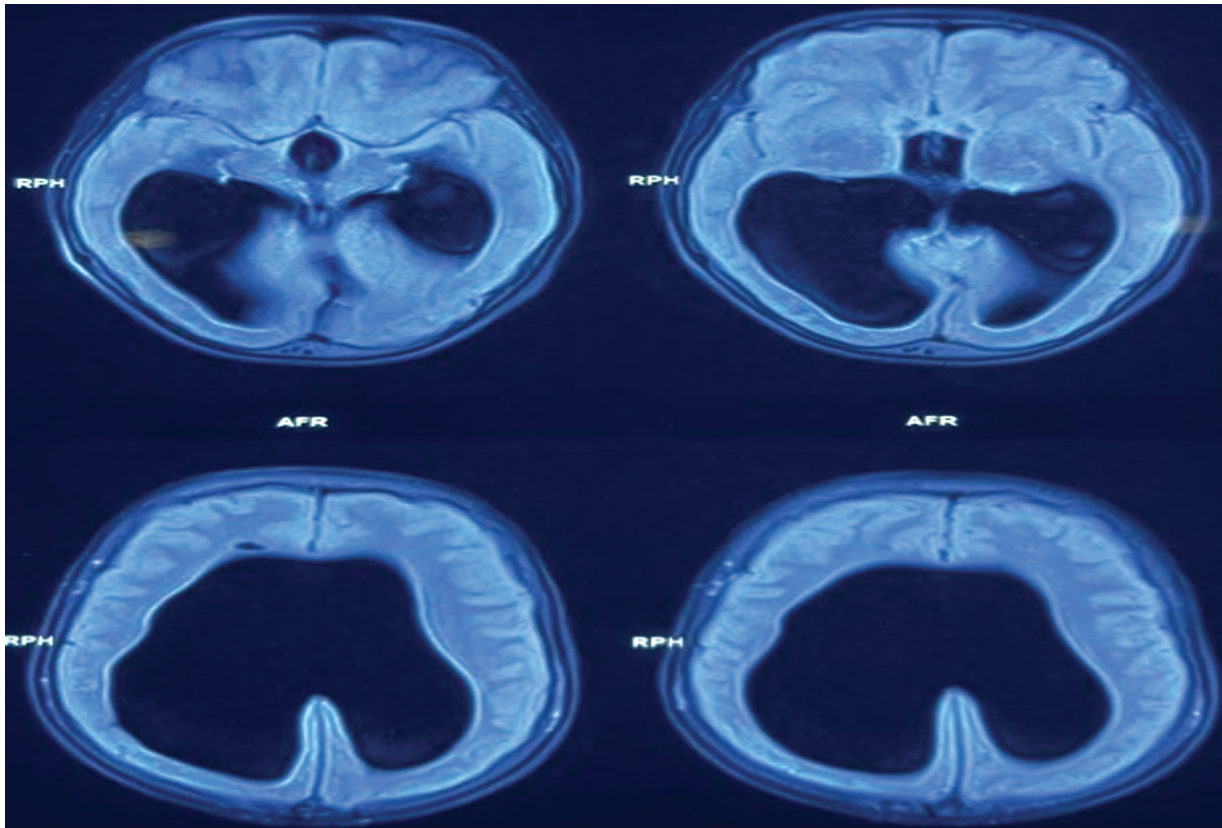
**Fig. 1** Computed tomography (CT) scan of head showing right-sided chronic subdural hematoma (*thin arrow*) and acute extradural hematoma (*thick arrow*) with two shunt systems in ventricles (*small arrow*).

insertion in the same hospital. At the time of admission, his score at Glasgow Coma Scale (GCS) was E2V2M5. Pupil was bilaterally sluggish reactive. Blood pressure was 118/66 mm Hg and pulse rate was 56 beats per minute. Patient was resuscitated in the emergency room and all routine investigations were sent. CT scan of the head showed right-sided frontotemporoparietal chronic SDH and left-sided parietal dominant EDH with two different shunt systems in ventricles (► **Fig. 1**). On detailed history elaboration from parents we came to know that the patient underwent multiple shunt surgeries for congenital hydrocephalus secondary to aqueductal stenosis as revealed by his previous scan (► **Figs. 2,3,4**). Right-sided VP shunt was done at the age of eight years for congenital hydrocephalus and left-sided VP shunt was done one year back for neurological deterioration secondary to right-sided VP shunt malfunction. Four days back, ventricular end was revised again on the left side from the same burr hole. Following poor neurological status, emergency surgery was planned. Preoperative routine investigations along with coagulation profile were found to be normal. Patient was taken to the emergency

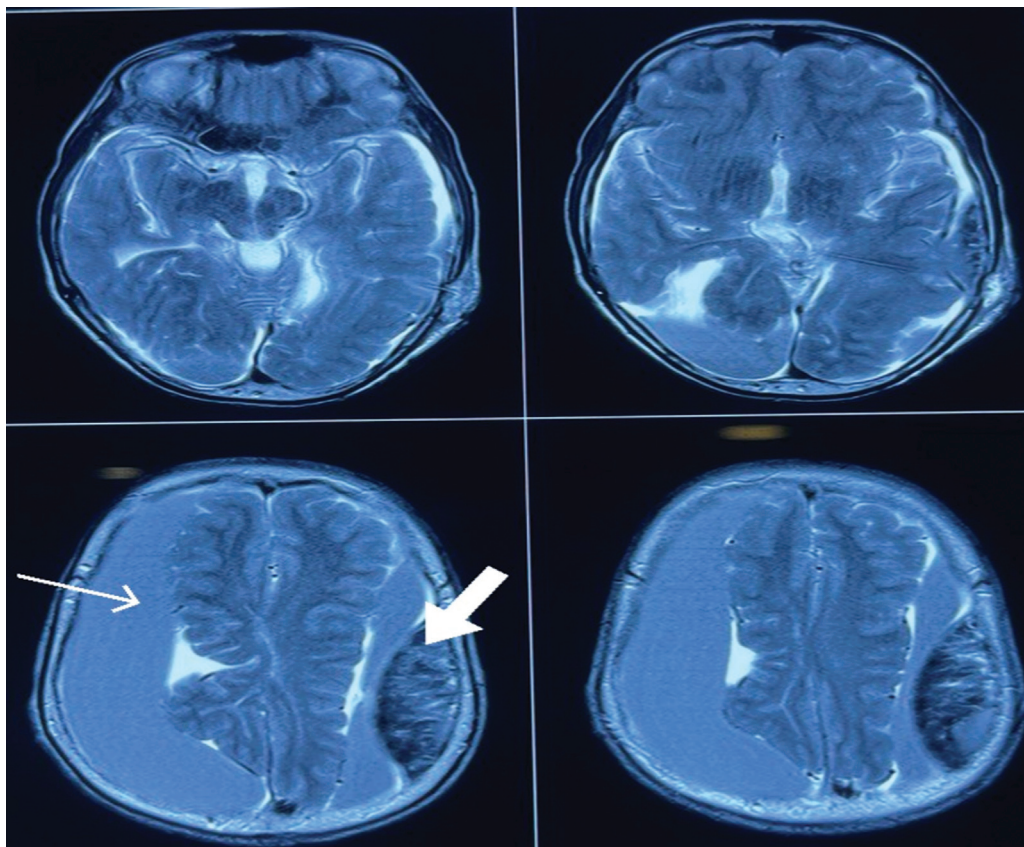
operating room where right-sided burr hole drainage of chronic SDH and left-sided parietal craniotomy with evacuation of EDH were done (► **Fig. 5**). Postoperative scans showed evacuated state of hematoma (► **Fig. 6**). Patient was observed in the critical care unit for 24 hours. Patient improved neurologically in the postoperative period and discharged on 8th day at GCS score 15 [E4V5M6] without any neurological deficit.

## Discussion

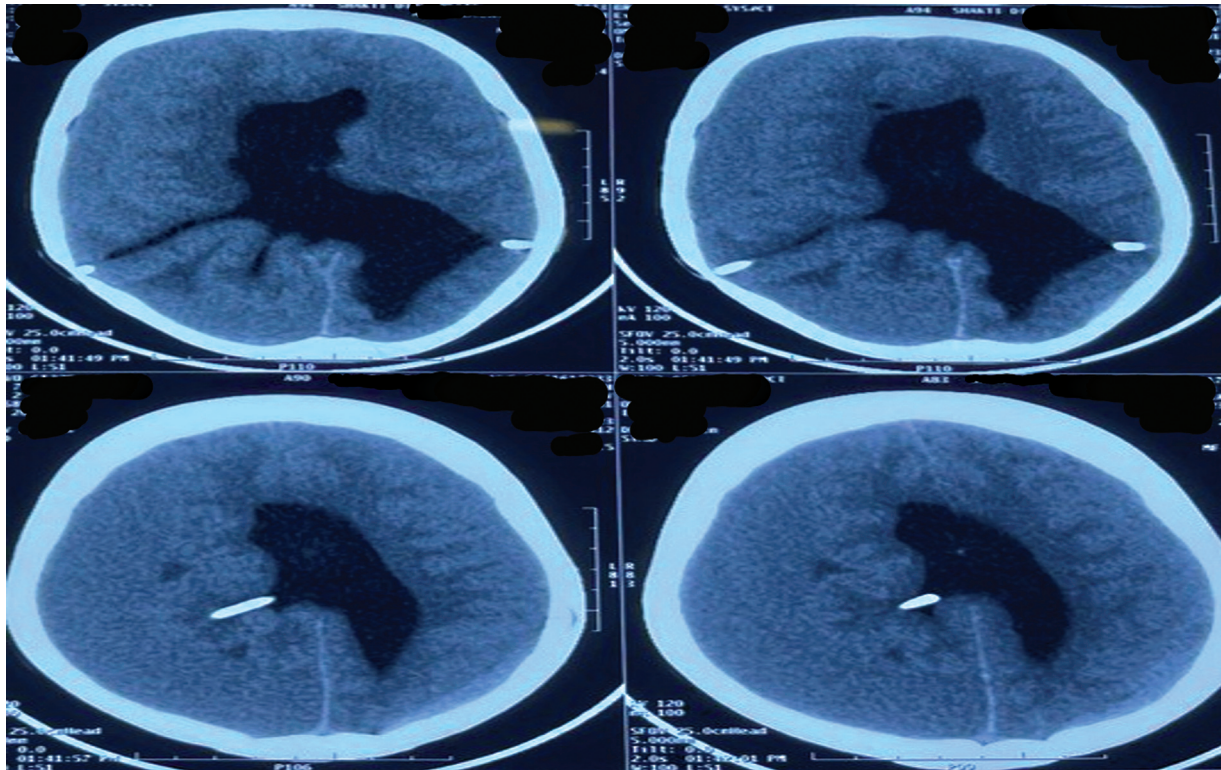
VP shunt is a very common neurosurgical procedure done for hydrocephalus due to various etiologies in different age groups. Shunt surgery and its complications are integral part of each other.<sup>4</sup> Intracranial hematomas are rare set of complications associated with VP shunt surgeries.<sup>5</sup> Intracranial hematoma can be in the form of acute or chronic SDH, EDH, or intracerebral hematoma. SDHs among these are more common.<sup>6,7</sup> SDHs can occur in up to 2 to 17% patients with cerebrospinal fluid diversion procedures.<sup>8</sup> Mechanisms to explain formation of intracranial hematomas are not precisely



**Fig. 2** Magnetic resonance imaging (MRI) brain showing dilated ventricle (first scan before any shunt surgery).



**Fig. 3** Magnetic resonance imaging (MRI) brain T2-weighted (T2W) showing right-sided chronic subdural hematoma and left-sided acute extradural hematoma.



**Fig. 4** Computed tomography (CT) scan of head showing right-sided chronic subdural hematoma with two shunt systems (before ventricular end revision on the left side).

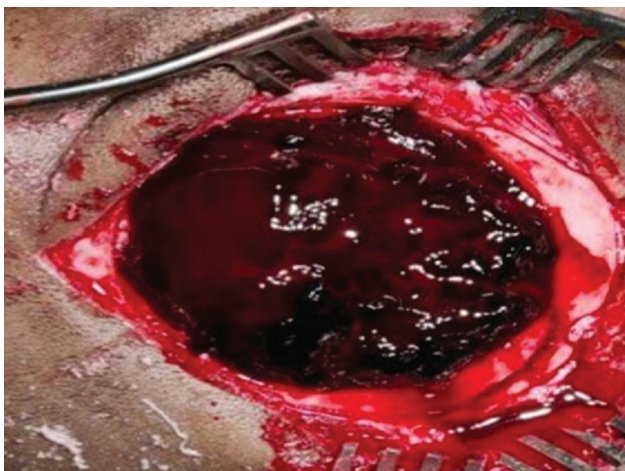
defined yet, but some concepts have been postulated. Following VP shunt surgery, ventricles shrinkage lead to the collapse of brain cortex inwards. It causes stretching of the bridging veins which are amenable to rupture even after minor trauma.<sup>8</sup> Other causes may be bleeding disorders or use of anti-coagulants.<sup>6-8</sup> Formation of EDH following shunt surgeries is extremely rare. It may be at the surgical site or distant from the surgical site.<sup>9</sup> Dural separation during ventricular catheter insertion or collapse of cortex following drainage of ventricle leads to pressure on dural venous attachment which may bleed further. Repeated attempt of ventricular catheter inser-

tion without adequate durotomy may lead to the separation of dura from calvarium and delayed manifestation in the form of EDH secondary to dural vessels oozing. Inadequate hemostasis of dural margins or bone, bleeding diathesis, or venous malformations are the other causes.<sup>9,10</sup>

In our case, gradual collapse of the cortex on the right side following VP shunt surgery led to the formation of chronic SDH. Rapid shrinkage of ventricle followed by collapse of the cortex and inadequate hemostasis of dural margins were probable causes of EDH formation on the left side.

Although chronic SDHs have gradual progression, patients may remain asymptomatic but rapid neurological deterioration can occur in case of EDH. In our case, EDH formation after shunt revision led to rapid neurological deterioration for which emergency surgery was required.

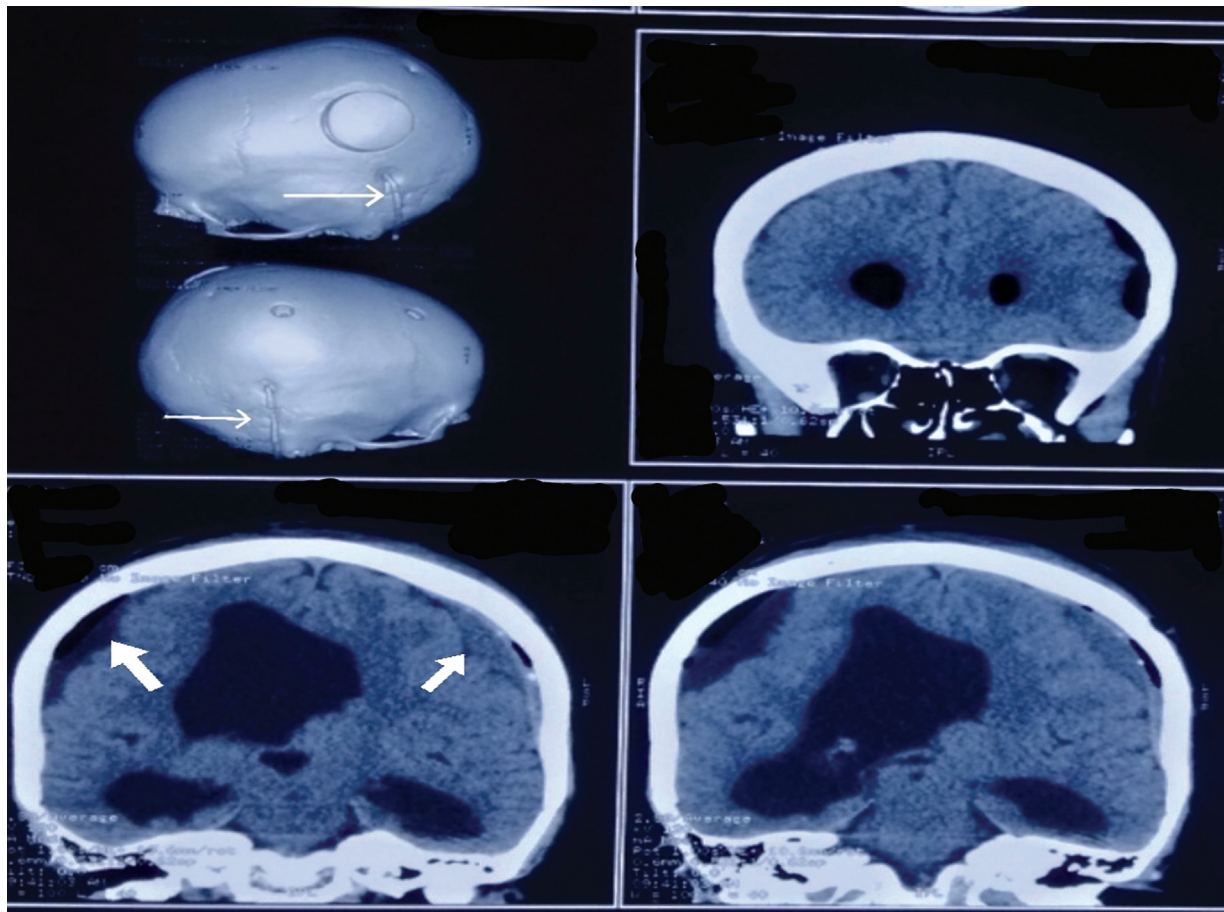
Few cases have been reported of isolated chronic SDH or EDH following VP shunt placement. We are probably one of the first authors to report such case of simultaneous occurrence of chronic SDH and EDH in a patient following shunt procedures.



**Fig. 5** Left parietal craniotomy with evacuation of extradural hematoma.

## Conclusion

VP shunt surgeries are associated with many complications. SDH and EDH are potentially life-threatening complications. Adequate hemostasis along with accurate surgical technique is of paramount importance in shunt surgeries. In case of neurological deterioration following shunt surgeries, high index of suspicion should be made and immediate CT scans are required to rule out these fatal entities. Prompt diagnosis



**Fig. 6** Postoperative computed tomography (CT) head showing evacuated state of hematoma (*thick arrow*) and shunt system in situ (*thin arrow*).

and appropriate surgical intervention lead to excellent outcome.

**Conflict of Interest**  
None declared.

**References**

- 1 Venkataramana NK. Hydrocephalus Indian scenario - a review. *J Pediatr Neurosci* 2011;6(Suppl 1):S11–S22
- 2 Illingworth RD. Subdural haematoma after the treatment of chronic hydrocephalus by ventriculocaval shunts. *J Neurol Neurosurg Psychiatry* 1970;33(01):95–99
- 3 Niimura M, Takai K, Taniguchi M. Postoperative epidural haematomas associated with hydrocephalus caused by intraoperative overdrainage of cerebrospinal fluid: two case reports with a literature review of 19 cases. *BMJ Case Rep* 2015;2015:bcr2014206654
- 4 Merkler AE, Ch'ang J, Parker WE, Murthy SB, Kamel H. The rate of complications after ventriculoperitoneal shunt surgery. *World Neurosurg* 2017;98:654–658
- 5 Kalia KK, Swift DM, Pang D. Multiple epidural hematomas following ventriculoperitoneal shunt. *Pediatr Neurosurg* 1993;19(02): 78–80
- 6 Wolfsberger S, Gruber A, Czech T. Multiple supratentorial epidural haematomas after posterior fossa surgery. *Neurosurg Rev* 2004;27(02):128–132
- 7 Coulibaly O, Dama M, Diallo O, Li G, Sogoba Y, Kanikomo D. Delayed intracerebral and subdural hematomas after ventriculoperitoneal shunt in a child: a case report and review of the literature. *Neurochirurgie* 2016;62(02):105–107
- 8 Berger A, Constantini S, Ram Z, Roth J. Acute subdural hematomas in shunted normal-pressure hydrocephalus patients - management options and literature review: A case-based series. *Surg Neurol Int* 2018;9:238
- 9 Byrappa V, Redhu S, Varadarajan B. Delayed incidental diagnosis of postoperative extradural hematoma following ventriculoperitoneal shunt. *J Neurosci Rural Pract* 2015;6(01):94–96
- 10 Garg M, Sachdeva D, Patel K, Jagetia A, Srivastava AK. Post V-P shunt surgical site EDH an uncommon complication: case report. *Rom Neurosurg* 2017;31(02):253–256