



Applications and Reliability of Dorsal Metacarpal Artery Perforator Flap

Anand Prasath Jayachandiran¹ Suresh Rajendran¹ Surya Rao Venkata Mahipathy¹
Alagar Raja Durairaj¹ Narayanamurthy Sundaramurthy¹ Manoj Ananthappan¹

¹ Department of Plastic and Reconstructive Surgery, Saveetha Medical College & Hospital, Saveetha Institute of Medical and Technical Sciences, Saveetha University, Thandalam, Tamil Nadu, India

Indian J Plast Surg 2023;56:519–525.

Address for correspondence Anand Prasath Jayachandiran, MS (General Surgery), MCh (Plastic and Reconstructive Surgery), DrNB (Plastic Surgery), Department of Plastic and Reconstructive Surgery, Saveetha Medical College & Hospital, Saveetha Institute of Medical and Technical Sciences, Saveetha University, Thandalam, Kanchipuram District, Tamil Nadu 602105, India (e-mail: j7anand@gmail.com).

Abstract

Keywords

- ▶ dorsal metacarpal artery perforator flap (DMAP)
- ▶ applications
- ▶ reliable

Dorsal metacarpal artery perforator flap (DMAP), first described by Quaba and Davison, is a useful tool in the armamentarium of plastic surgeons. It provides like for like tissue for the reconstruction of dorsal finger defects. It is a simple and relatively easy flap to harvest with minimal donor site morbidity. In this case series, we present our experience, applications, and surgical technique of flap harvesting.

Introduction

Quaba and Davison in 1990 described the dorsal metacarpal artery perforator (DMAP) flap based on the perforators from dorsal metacarpal arteries and termed it the dorsal hand flap.¹

These perforators are constant at the level of the metacarpal neck in the second to fourth intermetacarpal space.²

The skin overlying the intermetacarpal space can be elevated and pivoted on the DMAP, the proximal-most extent of the flap unto the distal border of the extensor retinaculum.^{1–4}

This article presents our experience utilizing the DMAP flap for various finger defects proximal to the tip.

Materials and Methods

Between January 2020 and January 2023, 14 patients underwent reconstruction using a DMAP flap for defects proximal to the fingertip. Twelve were male patients and two were

female patients. Among the 14, two were diabetic patients. The etiology was traumatic in 9 patients, postinfective in 2, and postsurgical in 2 patients. In 2 patients, who underwent fingertip reconstruction by reverse homodigital artery flap, the primary flap donor site was covered using the DMAP flap. The flap was used to create the web space in one postburn syndactyly patient (▶ **Fig. 1**). Patients with previous injuries or concurrent injuries along the dorsum of the hand were excluded from this reconstructive option.

Surgical Technique

All patients were operated under supraclavicular block and tourniquet control. After thorough debridement and assessing the defect, flap markings are done.

Flap markings: The outer border of the adjacent metacarpals is marked. The proximal extent of the flap is placed at the distal border of the extensor retinaculum. Planning in reverse is done and the flap is marked within this area as

article published online
September 25, 2023

DOI <https://doi.org/10.1055/s-0043-1773771>.
ISSN 0970-0358.

© 2023. Association of Plastic Surgeons of India. All rights reserved. This is an open access article published by Thieme under the terms of the Creative Commons Attribution-NonDerivative-NonCommercial-License, permitting copying and reproduction so long as the original work is given appropriate credit. Contents may not be used for commercial purposes, or adapted, remixed, transformed or built upon. (<https://creativecommons.org/licenses/by-nc-nd/4.0/>)
Thieme Medical and Scientific Publishers Pvt. Ltd., A-12, 2nd Floor, Sector 2, Noida-201301 UP, India

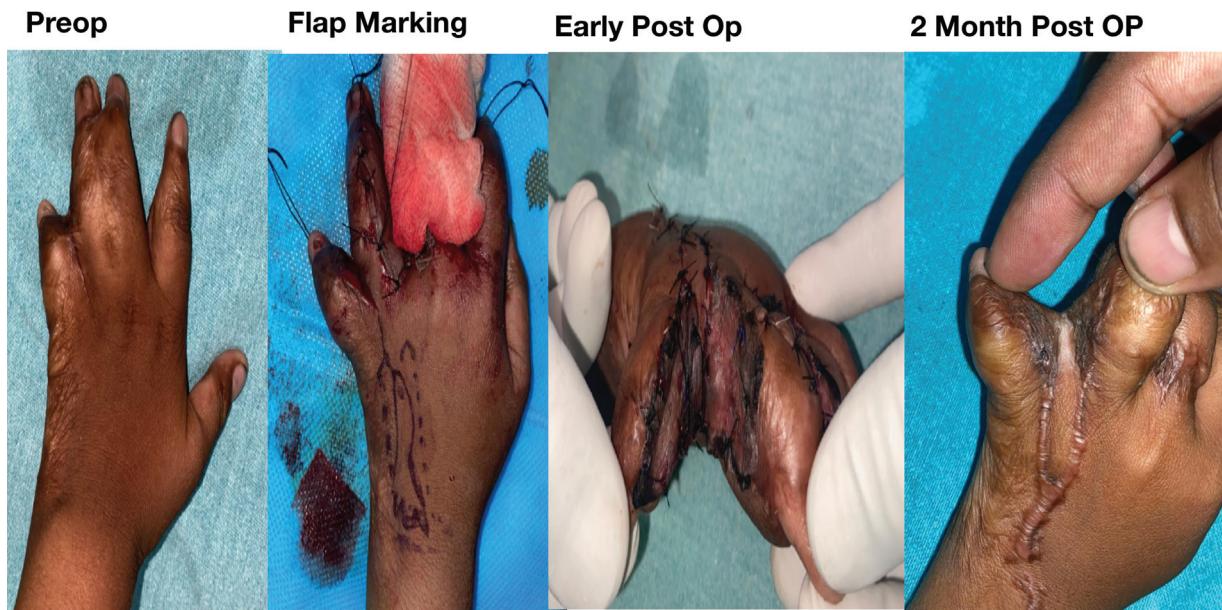


Fig. 1 A 2-year-old female child with postburn syndactyly and IVth web resurfaced with IV dorsal metacarpal artery perforator (DMAP) flap.

required. We did not Doppler the perforator preoperatively due to its anatomical constancy.¹⁻⁶ We usually make a non-delineating incision first and identify the location of the perforator distal to the juncture tendinae at the level of the metacarpal neck (→ **Figs. 2 and 3**).

After confirming the location, final adjustment of the flap design is made.

The flap is elevated superficial to the paratenon of the extensor tendons. Subcutaneous veins outside the flap terri-

tory are not included in the flap to avoid venous congestion. Though it has been said in various articles to preserve the dorsal digital nerves during flap elevation, in our series we could not preserve them as they seem to course very close to the perforators.

Due to the possibility of injuring the perforator entry to the skin paddle in most of our cases, we chose to sacrifice the nerve if the flap has to be propelled.^{1,3,4} The flap is islanded and pivoted on the perforator, leaving a cuff of fat around the

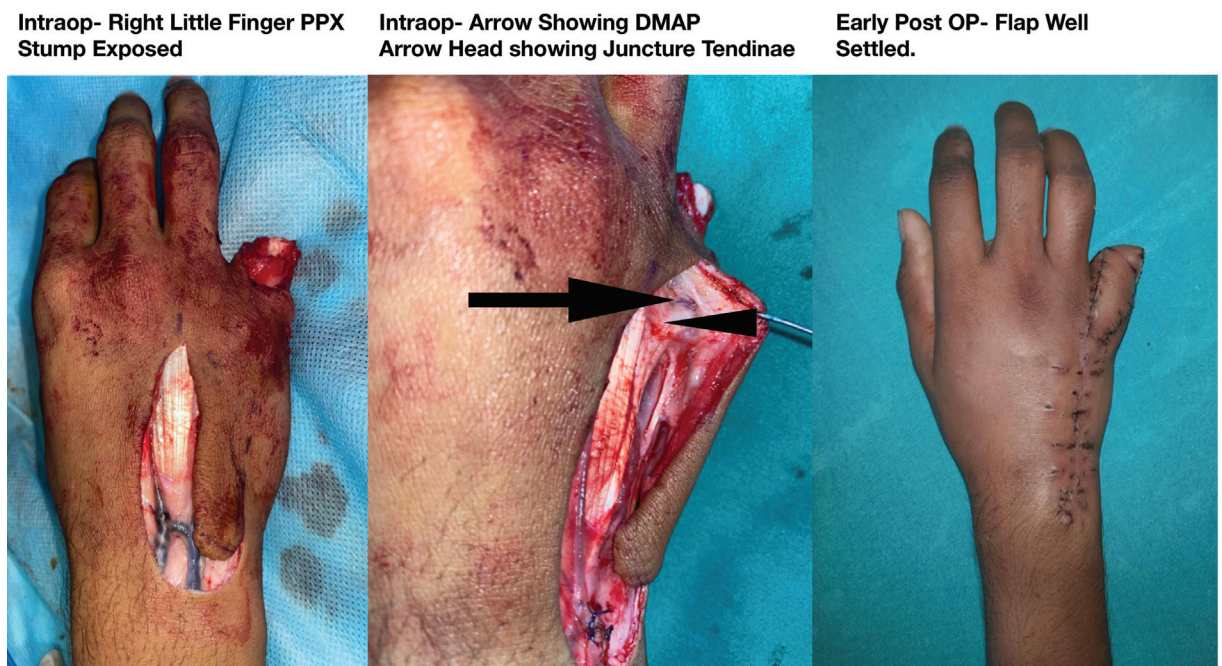


Fig. 2 A 20-year-old male with crush amputation of the right little finger following trauma. The residual bone stump was covered with IV dorsal metacarpal artery perforator (DMAP) flap.

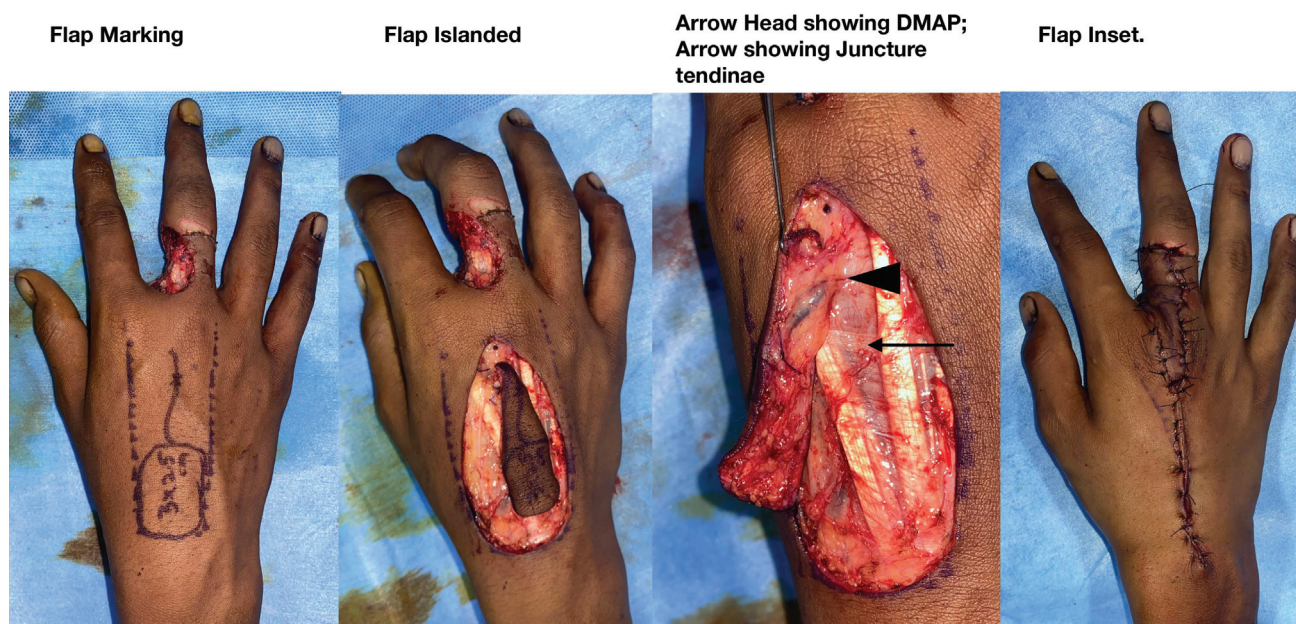


Fig. 3 Posttraumatic soft tissue defect along the dorsoradial aspect of the middle finger proximal phalanx (PPX).

perforator for better venous drainage. Tourniquet is let down and 4% lignocaine is sprayed on the perforator to prevent spasm. Flap bleeding is confirmed. The flap is propelled and the inset is given. The donor area is closed primarily. The hand is immobilized with the metacarpophalangeal (MCP) joint and wrist in extension, and fingers in extension for 1 week.

Results

Among the 14 cases, 7 flaps were raised using the second DMAP, 2 were raised on the third DMAP, and 5 were raised on the fourth DMAP. Thirteen flaps were raised as a propeller. One flap was used as a pedicled peninsular flap. Two flaps were raised with an adipofascial bridge segment.

Thirteen flaps survived, and one was lost completely due to venous congestion. Superficial epidermolysis was noticed in three flaps and was managed conservatively. The average duration for flap elevation was 45 minutes. The maximum flap dimension harvested was 9 cm in length and 2.5 cm in width. All patients were followed for 6 months. Donor site scar hypertrophy was noticed in two patients (► **Table 1**).

Representative Case (Patient 10)

An 80-year-old diabetic female sustained a road traffic accident and had multiple finger crush injuries on her left hand. She underwent debridement and fillet flap for her little finger and skin suturing for ring finger dorsum injury. She had a soft tissue defect over the dorsum of the middle finger. The second DMAP propeller was used to reconstruct the middle finger dorsal defect. The patient had superficial epidermolysis, which settled with conservative management (► **Fig. 4**).

Discussion

Like for like tissue is one of the preferred principles/options of reconstruction whenever possible. Defects of the dorsum of fingers can be reconstructed using multiple options among which the commonly used flaps are adipofascial/deepithelialized cross-finger flap, and abdominal and groin flaps.⁷ Flaps from the dorsum of the hand will be an ideal reconstructive option for dorsal finger defects.^{1,3,7}

The flaps which are described based on the dorsal metacarpal artery system are DMAP flap, extended reverse dorsal metacarpal artery flap, and reverse dorsal metacarpal artery flap.^{1-3,8-12}

Flaps which can be based or elevated from the dorsum of the finger are extended reverse dorsal metacarpal artery flap, dorsal digital artery perforators flaps, kite flap, boomerang flap, intercommissural flaps, eponychial flap (which gives relative nail lengthening and better aesthetic appearance), and first dorsal metacarpal artery (mostly used for thumb defects).^{9,11-19}

DMAP flap is based on the perforator which usually arises from the dorsal metacarpal artery at the level of the metacarpal neck distal to the juncturae tendinae.

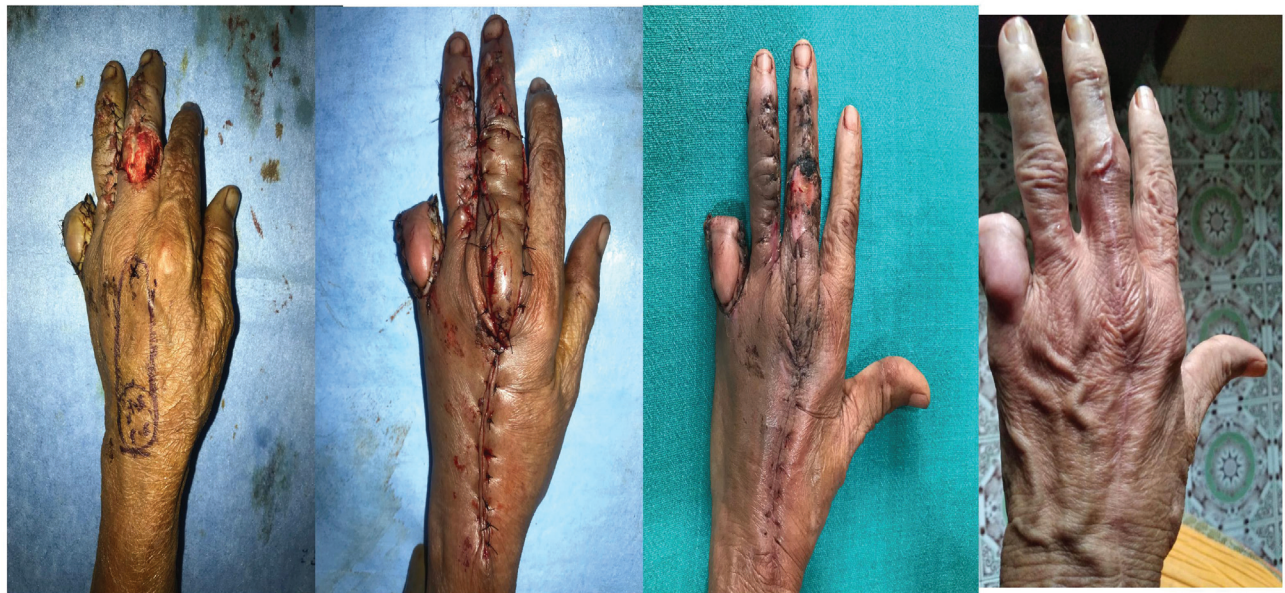The perforator nourishes the skin segment bounded on the sides by the outer borders of the adjacent metacarpals. The proximal extent of the flap is usually kept at the distal border of the extensor retinaculum.^{1,3} We, in our series, contained the dimensions of the flap as mentioned above. In certain cases, we could identify the perforator from the dorsal carpal arch while raising the proximal end of the flap. In such cases, we restricted the proximal end of the flap to the perforator from the dorsal carpal arch.

It has been described that the caliber of the dorsal metacarpal artery decreases, and its congenital absence

Table 1 Details of the patients

Serial no.	Age	Sex	Finger	Location of defect	Distal end	Etiology	Perforator location	Defect size (cm)	Remarks
1	28	M	Left index	Dorsum	MPX-DIP joint	Trauma	II	3 × 2	Superficial epidermolysis-managed conservatively
2	22	M	Left index	Dorsum and volar	Web and volar	Trauma	II	2 × 2; 2 × 2	
3	19	M	Right middle	Dorsoradial	PPX	Trauma	II	3 × 2.5	
4	24	M	Left ring	Dorsum	PIP joint	Trauma	III	2.5 × 2	
5	18	M	Left little	Dorsum	DIP joint	Trauma	IV	3 × 2	Superficial epidermolysis-managed conservatively
6	2	F	Left IVth web	Web	IVth web	Burns	IV	2 × 1.5	
7	61	M	Right index	Dorsum	PPX	Infection	II	3.5 × 2	Adipofascial bridge segment
8	22	M	Left little	Dorsoulnar	PPX	Trauma	IV	3 × 2	Flap loss
9	20	M	Right little	Dorsum	PPX	Trauma	IV	3.5 × 2	
10	80	F	Left middle	Dorsum	PIP joint	Trauma	II	3 × 2	Superficial epidermolysis-managed conservatively
11	35	M	Left little	Dorsoulnar	MCP	Surgical	IV	2.5 × 2	Pedicled
12	26	M	Left middle	Dorsoulnar	PPX-PIP joint	Surgical	III	3 × 2.5	
13	53	M	Right index	Dorsum	PPX	Infection	II	3 × 2	Adipofascial bridge segment
14	42	M	Left index	Dorsum	MPX	Trauma	II	4 × 2.5	

Abbreviations: DIP, distal interphalangeal; F, female; M, male; MPX, middle phalanx; MCP, metacarpophalangeal; PIP, proximal interphalangeal; PPX, proximal phalanx.

Intraop- Flap**Intraop- Flap Inset****Early Post OP-
Superficial Epidermolysis****Late Post Op- 1yr****Fig. 4** An 80-year-old diabetic female with soft tissue defect over the left middle finger dorsum following trauma.

increases from radial to ulnar.^{20,21} We usually locate the perforator by identifying the juncture tendinae first and dissecting distal to it. The thickness of the juncture tendinae varies between patients and also between the metacarpal spaces in the same patient 3.

Even in the absence of the dorsal metacarpal artery, the perforator arises from the branches of the deep palmar arch.^{5,6}

In our experience, the perforator is always present. We had an incidental finding of the DMAP in the case of Apert hand (→Fig. 5). It was not used for any form of reconstruction in the Apert patient.

The DMAP flap can be designed as elliptical (conventional) or curved elliptical (which is used to extend the

reach almost to the distal interphalangeal [DIP] joint).³ The curved elliptical design was utilized in two of our patients (cases 1 and 5) (→Fig. 6).

The bridge segment can be raised as an adipofascial or as a cutaneous segment. In our series, we prefer to keep the bridge segment as adipofascial in elderly patients. Considering the elasticity of the skin (and the fear of it) in younger patients which may compress the tunneled adipofascial bridge segment, we prefer to keep the bridge segment as cutaneous.¹⁰ In such scenarios we incise the intervening skin between the flap and the defect while propelling the flap (→Fig. 6). We, in our series, used the adipofascial bridge segment in two patients (cases 7 and 13).

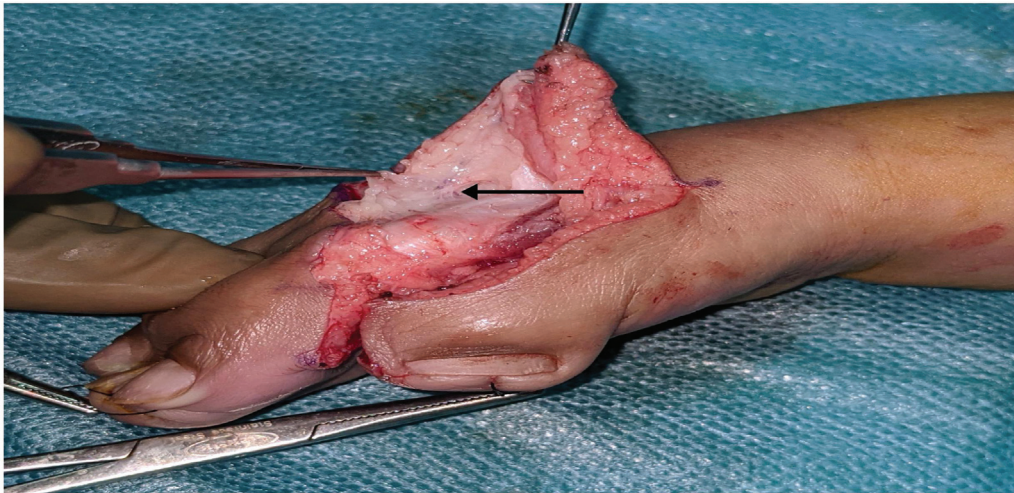


Fig. 5 Incidental finding of second dorsal metacarpal artery perforator (DMAP) perforator (arrow) in a case of Apert's hand.

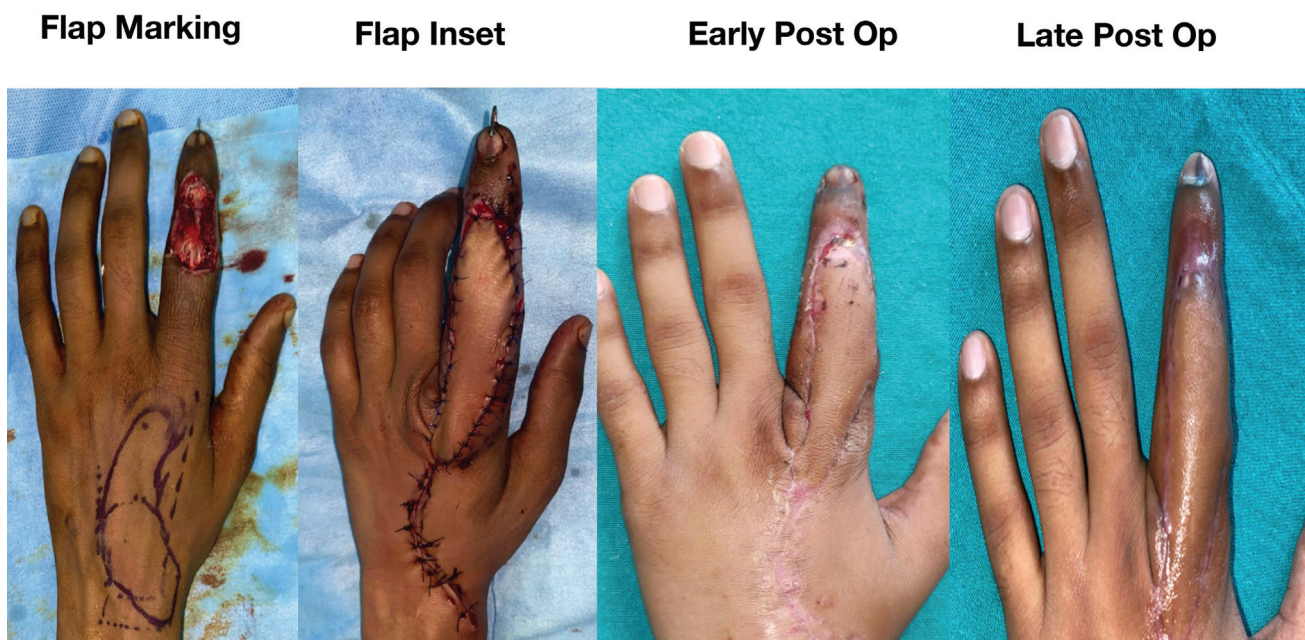


Fig. 6 A 28-year-old male with neglected crush injury over the left index finger dorsum following trauma. Note the “curved elliptical design” of the flap to increase the reach of the flap till the distal interphalangeal (DIP) joint. Flap suffered from distal superficial epidermolysis. Patient was managed conservatively.

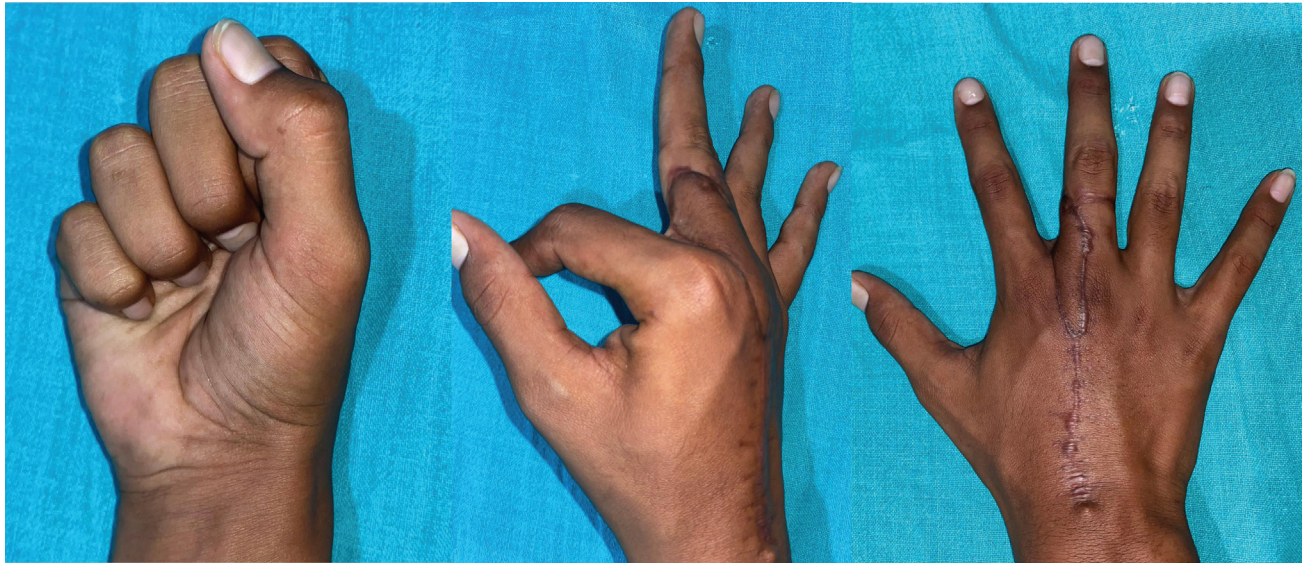


Fig. 7 Late post of patient shown in **Fig. 3** with complete range of movement at metacarpophalangeal (MCP) joint. Scar hypertrophy.

Though it is said that dorsal digital sensory nerves can be preserved while raising the flap,^{1,3,4} we found the nerve to travel closely in the vicinity of the perforator and sacrificed the nerve in most of our cases. None of the patients had any morbidity following the division of dorsal digital sensory nerves.

The DMAP flap, like another propeller flap, has the disadvantage of having venous issues.¹² This can be overcome by keeping a fat cuff around the perforator and completely islanding the flap. We routinely elevate the operated hand for 2 days in intravenous stand to promote venous return. Donor site morbidity is minimal, and we primarily closed the defects in all our patients.

In our series, we experienced a total flap loss in one patient (case 8) due to venous congestion. It was salvaged with cross-finger flap.

We have noticed scar hypertrophy in young patients who underwent DMAP flap reconstruction. All the patients with scar hypertrophy were managed conservatively. There was no restriction of MCP joint movement in patients who underwent DMAP reconstruction for the dorsum of finger defects (**Fig. 7**).

The other described variation of the dorsal metacarpal artery flap is the fascial dorsal metacarpal artery flap, where the adipofascial tissue alone is elevated and covered with split skin graft.¹⁰

Two other flaps are described based on the dorsal metacarpal artery, namely, the reverse dorsal metacarpal artery flap and extended reverse dorsal metacarpal artery flap.

The dorsal metacarpal artery is included within the reverse dorsal metacarpal artery flap and supplies the flap through the palmar-dorsal anastomosis at the level of metacarpal neck in a reverse flow manner.^{3,10,11,14,15,22,23} This flap has the advantage of raising a segment of tendon and metacarpal bone as vascularized tissue along with the cutaneous segment.^{3,7,10}

In the extended reverse dorsal metacarpal artery flap, the dorsal metacarpal artery is elevated along with the flap and pivoted at the mid-proximal phalanx. The vascular basis is based on the palmar-dorsal communication at the level of the mid-proximal phalanx.^{3,4,10,11,14,15} There has been a recent report on flaps elevated based on perforators from the first dorsal metacarpal artery for finger defects also and reverse first dorsal metacarpal artery flaps.^{19,24}

We have no experience with these flaps.

Conclusion

To conclude, DMAP flap is ideal for reconstructing defects over the dorsum of fingers proximal to the DIP joint, an excellent option for web spaces reconstruction, and lateral surfaces of the finger (up to 3 cm) with minimal donor site morbidity.

Conflict of Interest

None declared.

References

- 1 Quaba AA, Davison PM. The distally-based dorsal hand flap. *Br J Plast Surg* 1990;43(01):28-39
- 2 Maruyama Y. The reverse dorsal metacarpal flap. *Br J Plast Surg* 1990;43(01):24-27
- 3 Sebastin SJ, Mendoza RT, Chong AKS, et al. Application of the dorsal metacarpal artery perforator flap for resurfacing soft-tissue defects proximal to the fingertip. *Plast Reconstr Surg* 2011;128:166e-178e
- 4 Keshk Tarek F, Ammar MS, Fawzy HH, et al. Technical considerations of extended dorsal metacarpal artery flap for distal finger defects. *Menoufia Med J* 2022;35(01):301-306
- 5 Omokawa S, Tanaka Y, Ryu J, Kish VL. The anatomical basis for reverse first to fifth dorsal metacarpal arterial flaps. *J Hand Surg [Br]* 2005;30(01):40-44

- 6 Yoon TS, Carrera A, Benito-Ruiz J, Ferreres A, Serra-Renom JM. The anatomic basis of the fourth dorsal metacarpal flap: a cadaveric dissection. *J Hand Surg Am* 2006;31(05):711–716
- 7 Vuppapapati G, Oberlin C, Balakrishnan G. “Distally based dorsal hand flaps”: clinical experience, cadaveric studies and an update. *Br J Plast Surg* 2004;57(07):653–667
- 8 Earley MJ, Milner RH. Dorsal metacarpal flaps. *Br J Plast Surg* 1987;40(04):333–341
- 9 Keramidas E, Rodopoulou S, Metaxotos N, Panagiotou P, Iconomou T, Ioannovich J. Reverse dorsal digital and intercommissural flaps used for digital reconstruction. *Br J Plast Surg* 2004;57(01):61–65
- 10 Gregory H, Heitmann C, Germann G. The evolution and refinements of the distally based dorsal metacarpal artery (DMCA) flaps. *J Plast Reconstr Aesthet Surg* 2007;60(07):731–739
- 11 Koch H, Bruckmann L, Hubmer M, Scharnagl E. Extended reverse dorsal metacarpal artery flap: clinical experience and donor site morbidity. *J Plast Reconstr Aesthet Surg* 2007;60(04):349–355
- 12 Panse N, Karanjkar A. Propeller flaps. *Indian J Plast Surg* 2022;55(04):321–330
- 13 Yang D, Morris SF. Vascular basis of dorsal digital and metacarpal skin flaps. *J Hand Surg Am* 2001;26(01):142–146
- 14 Yousif NJ, Ye Z, Sanger JR, Arria P, Gilbert A, Matloub HS. The versatile metacarpal and reverse metacarpal artery flaps in hand surgery. *Ann Plast Surg* 1992;29(06):523–531
- 15 Yang D, Morris SF. Reversed dorsal digital and metacarpal island flaps supplied by the dorsal cutaneous branches of the palmar digital artery. *Ann Plast Surg* 2001;46(04):444–449
- 16 Katerinaki E, Chakrabarty KH. Distally based dorsal metacarpal flaps: a review of a series of patients treated in a 6-month period. *Injury* 2004;35(11):1176–1181
- 17 Hu H, Chen H, Hong J, et al. Propeller perforator flaps from the dorsal digital artery perforator chain for repairing soft tissue defects of the finger. *BMC Surg* 2019;19(01):188
- 18 Samantaray SA, Kalathingal K, Muhammed H, Joseph S. Eponychial flap: a simpler way to achieve better aesthetic outcome in a fingertip amputation. *Indian J Plast Surg* 2022;55(04):391–395
- 19 Aggarwal K, Singh K. Utility of first dorsal metacarpal artery flap for thumb defects. *Indian J Plast Surg* 2022;55(04):368–375
- 20 Coleman SS, Anson BJ. Arterial patterns in the hand based upon a study of 650 specimens. *Surg Gynecol Obstet* 1961;113:409–424
- 21 Olave E, Prates JC, Gabrielli C, Mandiola E. Perforating branches: important contribution to the formation of the dorsal metacarpal arteries. *Scand J Plast Reconstr Surg Hand Surg* 1998;32(02):221–227
- 22 Karacalar A, Ozcan M. A new approach to the reverse dorsal metacarpal artery flap. *J Hand Surg Am* 1997;22(02):307–310
- 23 Dautel G, Merle M. Dorsal metacarpal reverse flaps. Anatomical basis and clinical application. *J Hand Surg [Br]* 1991;16(04):400–405
- 24 di Summa PG, Davies K, Hart A. The first dorsal metacarpal propeller perforator (FDMP) flap for finger reconstruction. *Case Reports Plast Surg Hand Surg* 2020;7(01):94–97