

CRANIOFACIAL SURGERY IN CROUZONS AND APERTS DISEASE

J. C. SHARMA, S. BISWAS, H. S. GILL, D. V. CHIBBER, A. S. BATH
B. B. DOGRA AND S. S. NESARGI

SUMMARY

The authors experience with three cases of craniofacial dysostoses and reconstruction in young children is presented. The literature on the subject has been briefly reviewed.

(Key Words : Crouzons, Aperts Syndrome)

Crouzons and Aperts Syndromes are rare hereditary anomalies resulting from premature closure of various sutures of cranial vault by a primary and active synostoses (Tessier, 1971). Most of these patients are considered monsters and as such are hidden by their families or shut in institutions by society, a possible cause of mental retardation. Aperts described the syndrome of Acrocephalo syndactylism in 1906. Crouzon in 1912 described craniofacial dysostoses.

Gillies and Harrison (1950) were first to achieve reasonable correction in these cases by total osteotomy and movement of facial mass but it was the pioneer work of Paul Tessier who started the systemic work of craniofacial surgery in 1961. It was demonstrated that most of the deformities of skull and face are now surgically correctable or at least can be significantly improved (Tessier, 1971). His work proved two facts which revolutionised the Orbitocraniofacial surgery. Large masses of craniofacial skeleton can be completely denuded without risk of necrosis on repositioning but the more important fact proved was that eyes can be translocated in any direction without impairing vision. Craniofacial dysostoses (CFD or Crouzon and Aperts Diseases) are characterized by cranial and facial deformities but the relationship between cranial and facial deformities have not been clearly established. Brachycephaly or oxycephaly are most

often observed but monstrous bregmatic bump is usually seen only in Aperts. A dominant characteristic in these cases is recession of the frontal bone caused by coronal synostosis. The supra-orbital rim is also recessed to a greater degree in Aperts and this recession may be greater than the retrusion of the front of the face thus aggravating the appearance of exorbitism (Tessier, 1971). Although involvement of coronal suture is commonest but sagittal, lambdoid, frontosphenoidal and frontoethmoidal sutural involvement can also occur resulting in various cranial deformities like scaphocephaly, trigonocephaly, plagiocephaly and turriccephaly.

The maxillae and Zygoma are generally hypoplastic but shallowness of orbit is the dominant orbital characteristic. The orbital depth is lessened by verticalisation of roof of orbit. There is progressive protrusion of eyeballs until they rest outside the orbital rim giving rise to exorbitism. The shape of nose, so called parrot's beak, is not specific or even usual in CFD. This appearance is caused by retrusion and vertical shortness of middle third of face. Palate is usually high arched and due to progressive disproportionate growth between maxilla and mandible, a class III malocclusion with an anterior open bite results.

Depending upon the severity of deformity, various types of osteotomies available for correction are LeFort III advancement osteotomy

and frontal bone advancement, LeFort III advancement osteotomy, LeFort III and LeFort I osteotomy, LeFort II osteotomy, etc. (Jackson, 1987). These procedures are exceptionally hazardous. Death, blindness, brain damage and disastrous infection (meningitis, osteomyelitis of skull) are some of the major complications. Hence this type of surgery should be undertaken only by considerably experienced craniofacial surgeons, neurosurgeons and neuro-anaesthetist (Munro, 1979). We have undertaken this complex surgery on three cases for the first time in our Armed Forces and this report is based on our experience in these cases.

Case Reports

Case No. 1

M. 2½ years old son of a serving soldier, was initially admitted to neurosurgical services of Command Hospital (SC), Pune with the complaints of repeated episodes of prolapse of eyeballs and delayed milestones. On examination child showed typical features of brachycephaly, maxillary hypoplasia with relative mandibular prognathism, bilateral exophthalmos, parrot beaked nose and high arched palate. There was no evidence of hydrocephalus. Fundus examination excluded papilloedema and X-ray skull revealed very shallow orbital cavities. Child developed exorbitism during his stay in the hospital. He was diagnosed as a case of Crouzons disease and had to be taken up for surgery as a semi emergency because of the real danger that he may lose his eye sight.

Case No. 2

S. S. 1½ years old son of a serving NCO was brought to us with the complaints of delayed milestones, very prominent forehead and deformities of both hands and feet. The child had brachycephaly with a bump over bregma. Supraorbital recession was quite prominent. Child had syndactyly of both hands and feet and was mentally retarded. He had under-

gone multiple strip craniectomies elsewhere before reporting to us, when he was diagnosed as a case of Aperts Syndrome.

Case No. 3.

M. A. 1½ yrs. old female child was initially admitted in Neurosurgical services of this hospital for hydrocephalus at the age of 1 year and underwent ventriculo-peritoneal shunt. Child was brought to us with the complaints of excessively protruding eyeballs and delayed milestones. On examination she was found to have brachycephalic defect of the skull. Both the orbital cavities were very shallow with exophthalmos. Maxillary hypoplasia was present and child had parrot beaked nose. Fundus exam. showed changes consistent with early papilloedema and X-ray skull confirmed shallow orbital cavities. She was diagnosed as a case of Crouzons. We follow Andre's Two stage procedure for the management of our cases.

Observations

We carried out frontal bone advancement using standard bicoronal approach in all the cases as stage I procedure. LeFort III osteotomy will be done at the age of five years as stage II procedure. Coronal flap was turned down to expose supra orbital rims and orbital contents were dissected free at the sub periosteal level. Bifrontal craniotomy was performed 2 cm above the superior orbital rim and immediately after exposure of dura, patients were given I. V. Mannitol to cause shrinkage of brain which greatly facilitated the manoeuvrability in the anterior cranial fossa. Osteotomy of the three walls of orbit was carried out about 1 cm behind the orbital rim and tongue-in-groove cuts were made in temporal bones on either side. Inverted 'V' cut of the fronto-nasal region and orbital roof cuts were then performed. While making the cuts around the orbit, we found the use of simple tea spoon as a very handy and useful instrument in protecting the eyeballs. Superior orbital rim was



Fig. 1A

Fig. 1A. Pre-operative front view Crouzons.

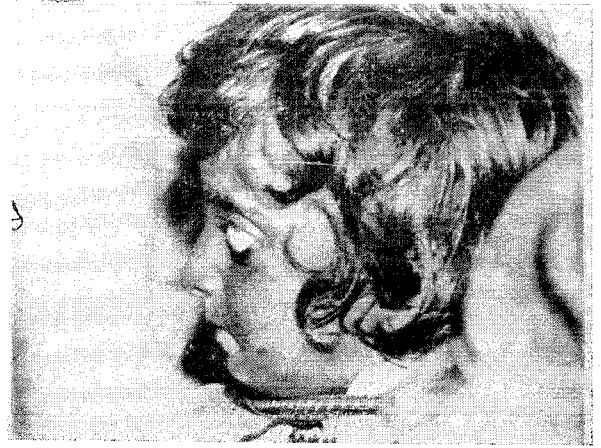

Fig. 1B

Fig. 1B. Pre-operative side view Crouzons.

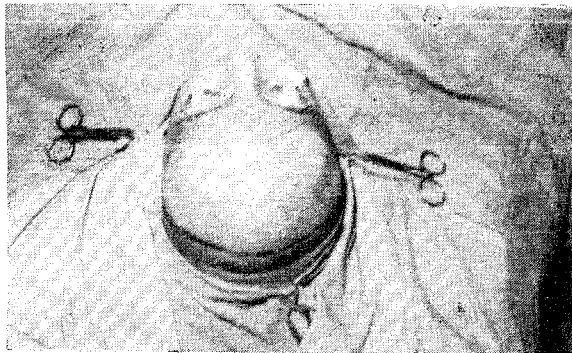


Fig. 2. Bicoronal incision marking.

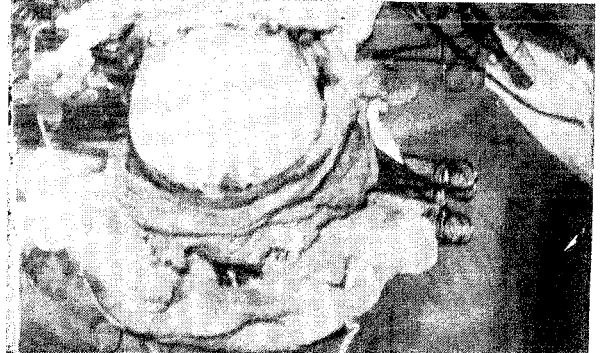


Fig. 3. Frontal bone exposed.

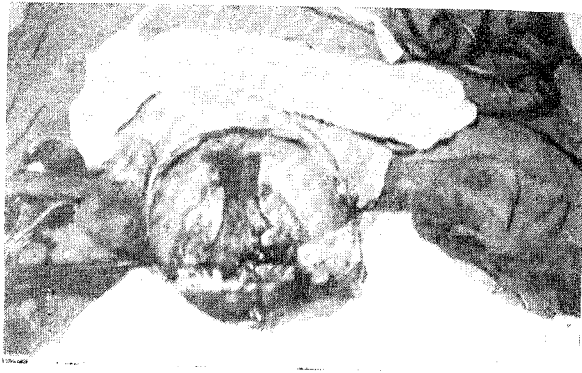

Fig. 4. Frontal bone removed, cottonoids protecting sagittal sinus.

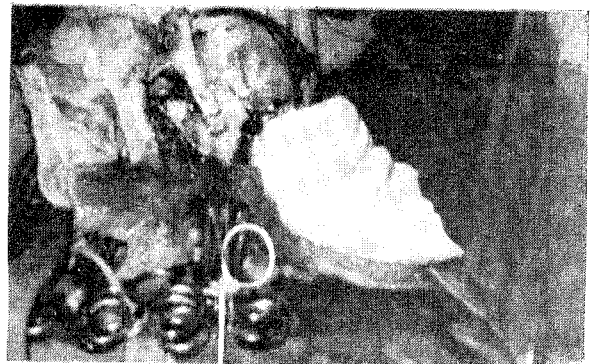

Fig. 5. Tongue in groove cuts and supra orbital rim advancement.

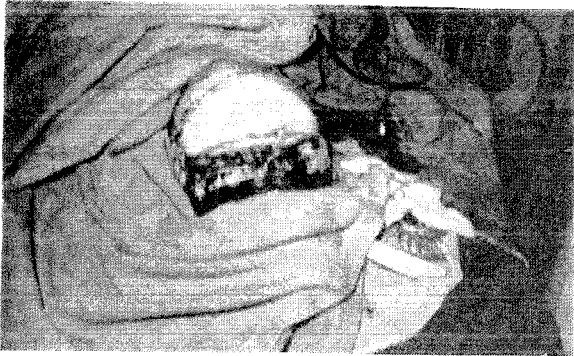


Fig. 6. Frontal bone replaced back, split rib grafts placed in bony gaps.

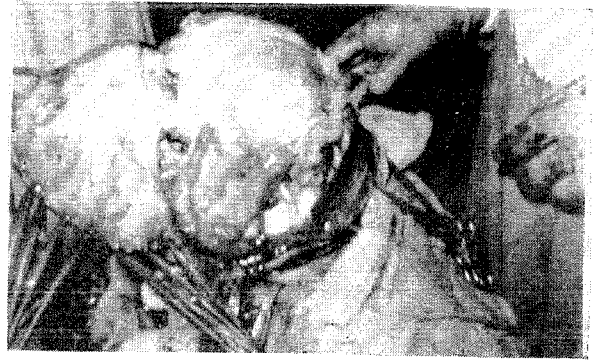

Fig. 7. Bone dust seen in bony gaps.

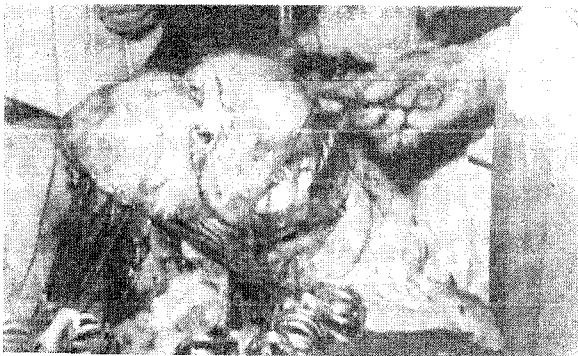


Fig. 8. Periosteal flap closure.

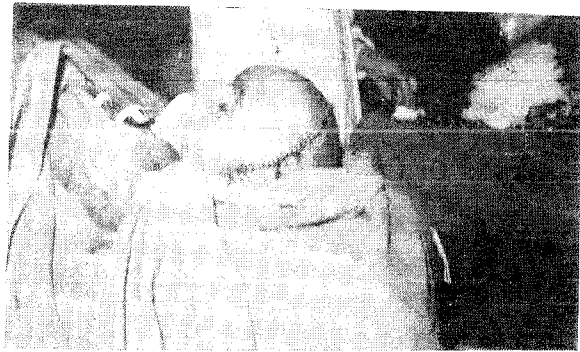

Fig. 9. Immediate post op. picture showing coronal flap closure.

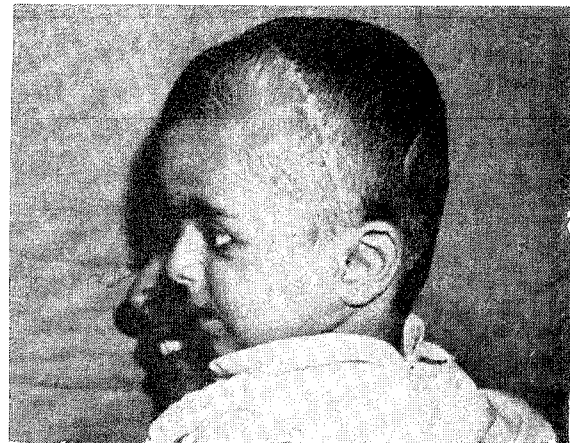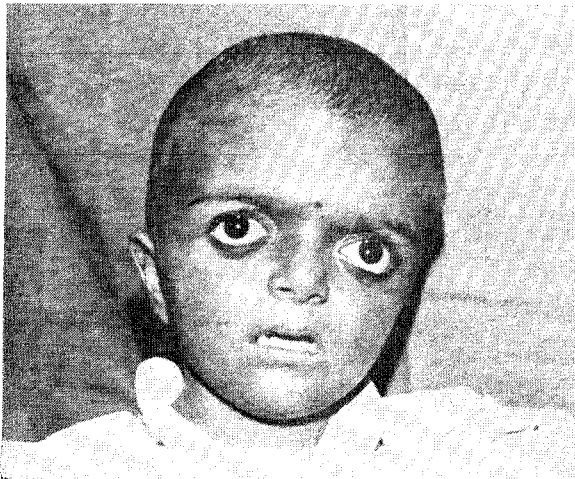


Fig. 10. Post op. picture (after 4 weeks) exorbitism corrected.

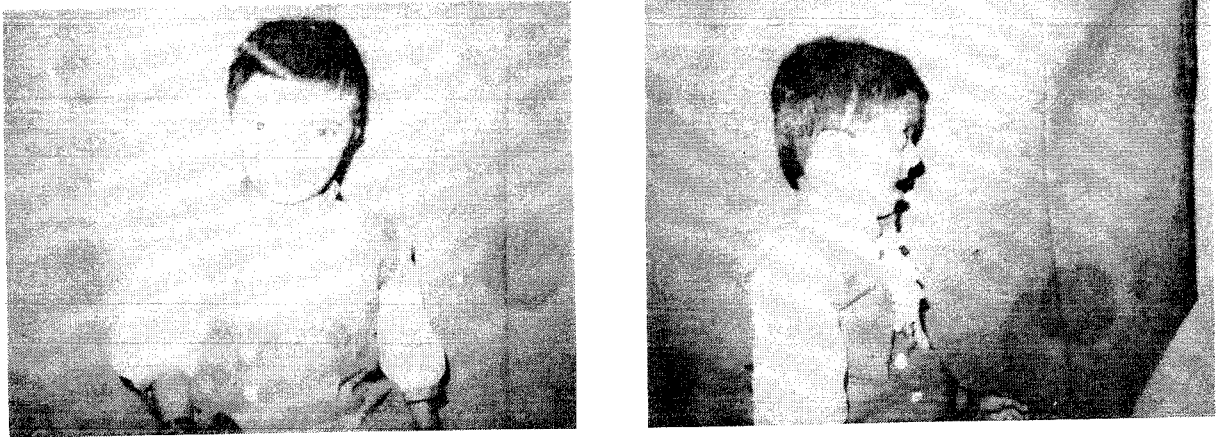

Fig. 10A. A. P. and lateral views post-op. after 1½ year

removed. We advanced the superior orbital rim by 1-1.5 cm and tongue in groove segments were fixed by interosseous wiring. We reversed the direction of the frontal bone to give better shape to the forehead, interosseous wire fixation was carried out over fronto zygomatic, frontonasal, superior orbital rim and parietal bones. All the bony gaps were filled with split rib bone grafts harvested from 6th and 7th ribs and bone dust collected at the time of making burn holes. Medial and lateral canthus ligaments were reanchored and bicoronal flap was repositioned back and stitched after keeping a subcutaneous Redivac negative suction. All the patients were put on broad spectrum antibiotics (Inj. Garamycin and Ampicillin) till removal of sutures on 10th post-operative day.

Discussion

Premature synostoses of the cranial sutures have been divided into three groups by Converse: Simple cranial synostoses, craniofacial dysostoses (Crouzon's disease) and acrocephalosyndactyly (Apert's Syndrome). It is estimated that approximately 10 per cent of patients with craniostenosis show significant facial deformity (Murray, 1976).

Best treatment for these deformities requires a radical and total osteotomy of the middle third of face to permit complete repositioning of the involved segments (Tessier 1971). These

total osteotomies frequently include the creation of a line of separation between anterior cranial base above and facial bones below and also between pterygoid processes behind and maxillae anteriorly.

The greatest risk is on and around the cribriform plate. There is danger of possible sloping of anterior cranial base, of possible prolapse of olfactory grooves and of a possible nasal meningo encephalocele (Tessier, 1971). These structures must be protected from injury before cutting deeply into the lower medial orbital angle.

Simultaneous advancement of frontal bones, orbit and face can lead to infection caused by opening the anterior cranial fossa to the nasal cavity and these complications can be avoided by, (i) Two stage procedure consisting of advancement of the upper orbit and frontal bone and a LeFort III osteotomy in a separate operation (Andrel, 1983), (ii) Protecting the nasal mucoperiosteum and so creating a barrier between cranium and nasal cavities, and (iii) Maintaining the bony structure of whole anterior cranial base with the supra orbital bar intact during the advancement and/or reshaping of the forehead, orbit and midface. Andrel et al. has described a new technique in craniofacial surgery by preserving the complete anterior cranial fossa while simultaneously correcting the forehead, orbit and face in CFD. With

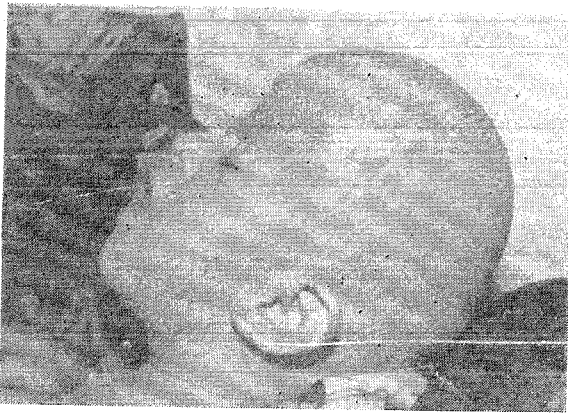

Fig. 11. Pre-op. picture of Apertis syndrome showing high prominent forehead, bregmatic bump, old scars of multiple strip craniectomies.

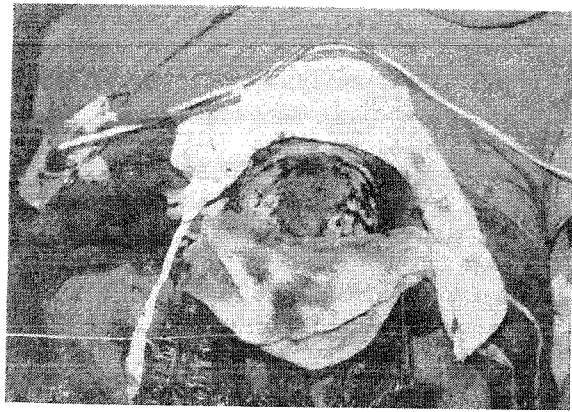


Fig. 12. Frontal bone removed, cottonoids protecting superior sagittal sinus.

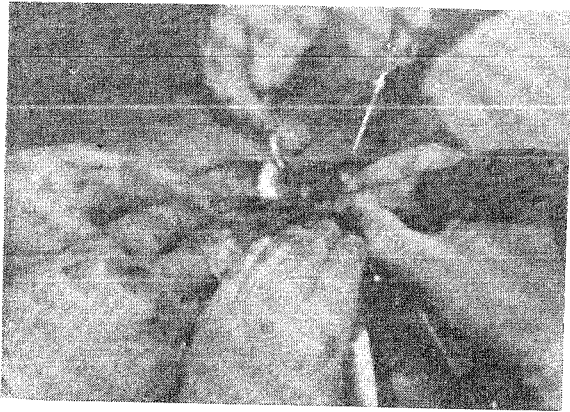


Fig. 13. Supra-orbital osteotomy in progress, tea spoon protecting eyeball.

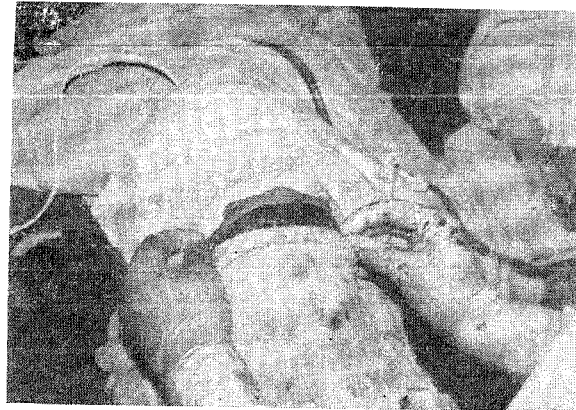


Fig. 14. Supra-orbital rim detached and advanced by 1 cm.

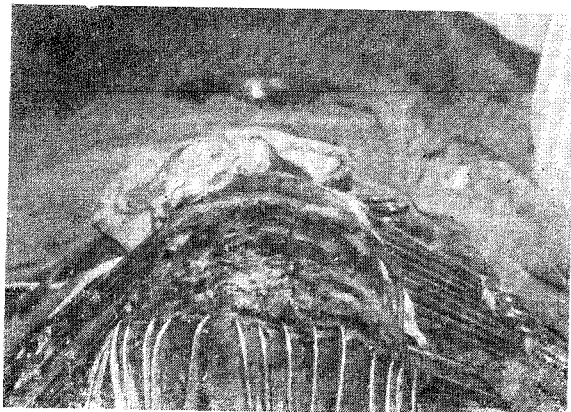


Fig. 15. Supra-orbital rim fixed in advanced position.

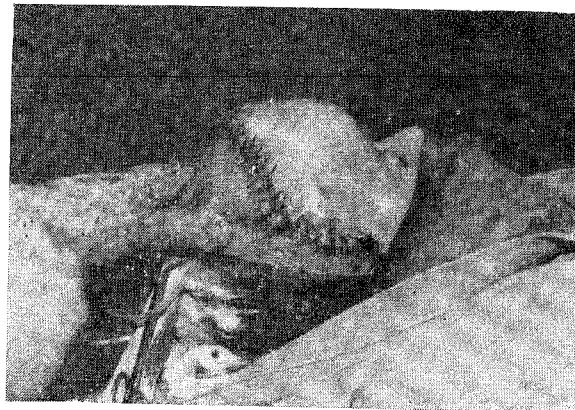

Fig. 16. Immediate post-op. picture.



Fig. 17 & 17A. Post-op. A. P. and lateral views after 1 year

this procedure the risk of infection spreading from nasal sinuses and cavities should get minimised (Andrel, 1983).

Munro employed this technique in 5 cases and has slightly modified the technique by making the horizontal cut of the frontal bone only 1 mm above the anterior edge of orbital roof. The frontal bar is advanced and lowered to produce a normal contour at the superior orbital rim. But these operations may be applicable only in adults or youngsters because intact and unreleased cranial base in young children could have a negative influence on sagittal growth by restricting the push of the expanding frontal lobe of the brain. The mental prognosis in cases of cranio synostosis operated within the first year is excellent. But after the age of 3 yrs., the value of operation is more questionable, because it may not give completely satisfactory results. Excellent neurological results are however possible. Infants and children less than 3 yrs. of age did well in withstanding the extensive surgery and pro-

longed anaesthesia (Edgerton, 1974). The improved team work from inter disciplinary management of these children produces reduction in operating time, better reconstruction and smooth post-operative period.

Results

During the immediate post-operative period, both pupils were found to be normally reacting to light. All the patients developed oedema over the face and eyelids which resolved within 7 days time. Patients were started on oral fluids on 1st post-operative day. Movements of eyeballs and eyelids were normal after the regression of oedema. There was no evidence of blindness or CSF rhinorrhea in any of our cases. Exorbitism regressed completely. One patient had low grade fever post-operatively for 3 weeks which subsided on its own. There was no evidence of meningitis or osteomyelitis of skull. There was no mortality or undue morbidity.

REFERENCES

1. ANDREL, H., MUHLBAUER, W., TWERDY, K. AND MARCHAO, D. : *Plastic Reconstructive Surgery*. 1983; 71 : 303.
2. EDGERTON, M. T., JANE, J. A. AND BERRY, F. A. : *Craniofacial osteotomies and Reconstruction in infants and young children*. *Plastic Reconstructive Surgery*. 1974; 54 : 13.
3. JACKSON, I. T., DUBIN, B., CHANDRA, R., CHABRA, D. K., SINGH, A. K. AND KUMAR, P. : *Cranio synostosis*. *Indian Journal of Plastic Surgery*. 1987; 20 : 1-7.

4. MUNRO, I. R. : Plastic Surgery edited by Grabb, W. C., Smith, J. W., 3rd Edition Boston : Little Brown and Company. 1979; 131-160.
5. MURRAY, J. E. AND SWANSON, L. T. : Reconstructive surgery for major craniofacial deformities. Surgical clinics of North America. 1976; 56 : 495.
6. TESSIER, P. : Relationship of craniostenosis to craniofacial dysostoses and to Facio-stenosis. Plastic Reconstructive Surgery. 1971; 48 : 224.
7. TESSIER, P. : Definitive Plastic Surgical treatment of the severe facial deformities of craniofacial dysostoses—Crouzons and Aperts diseases. Plastic Reconstructive Surgery. 1971; 48 : 419.

The Authors

COL. J. C. SHARMA, M.S., M.Ch., F.R.C.S., *Prof. and Head*, Deptt. of Plastic & Reconstructive Surgery, C.H. (S.C.), Pune-411040.

COL. S. BISWAS, M.S., M.S., M.Ch., *Senior Adviser in Neuro-surgery*, C.H. (S.C.), Pune-411040.

LT. COL. H.S. GILL, M.S., M.Ch., *Classified Specialist in Neuro-surgery*, C.H. (S.C.), Pune-411040.

LT. COL. D. V. CHIBBER, M.S., M.Ch., *Classified Specialist in Surgery*, Deptt. of Plastic and Reconstructive Surgery, C. H. (S.C.), Pune-411040.

LT. COL. A. S. BATH, M. S., *Classified Specialist in Surgery*, Deptt. of Plastic and Reconstructive Surgery, C.H. (S.C.), Pune-411040.

LT. COL. B. B. DOGRA, M.S., *Classified Specialist in Surgery*, Deptt. of Plastic and Reconstructive Surgery, C.H. (S.C.), Pune-411040.

LT. COL. S. S. NESARGI, D. A., M. D., *Classified Specialist in Anaesthesiology*, C. H. (S.C.) Pune-411040.

Request for Reprints

COLONEL J. C. SHARMA, M.S., M.Ch., F.R.C.S., *Prof. & Head of Plastic Surgery*, Armed Forces Medical College, Pune.