

**ISLAND TONGUE FLAP\***

S. BHATTACHARYA, A. CHATURVEDI, M. S. D. JAISWAL  
S. K. BHATNAGAR AND N. C. MISRA

**SUMMARY**

*In a clinico-anatomical study in ten cadavers and 24 patients of oral cancer a new island myomucosal flap, the "Island Tongue Flap" was designed and standardised in our unit. Based on the ipsilateral lingual artery and its venae comitantes this island flap was used to cover defects in the cheek, floor of mouth and oropharynx. Speech, swallowing and disposal of saliva were least affected post-operatively.*

(Key Words : Island flap, Oral cancer, Tongue flap)

The lingual artery is a long artery traversing a circuitous course between the Hyoglossus and the Genioglossus to reach the lateral side of the tongue. The arc of rotation of a flap based on this artery can be conveniently elongated if the artery with its accompanying veins can be straightened. Flaps of the required size can be obtained from the lateral surface of the tongue. Primary closure of the donor tongue defects was easier and resulted in less tethering of the tongue and a lesser loss of its mobility inside the mouth. Consequently, the post-operative articulation and speech was better and the overall morbidity was greatly reduced.

*Anatomy of the Flap*

The lingual artery (Fig. 1) is the principal vascular supply of the tongue and floor of mouth. It arises from the anteromedial surface of the external carotid artery opposite the tip of the greater cornu of the hyoid bone and between the superior thyroid and facial arteries. This first part of the lingual artery lies lateral to the middle constrictor in the carotid triangle, running obliquely upwards and medially at first and then curving downwards and forwards to the greater cornu of the hyoid bone, forming a characteristic loop. The artery now

passes medial to the posterior border of the hyoglossus and runs underneath it, along the upper border of the hyoid bone. This second

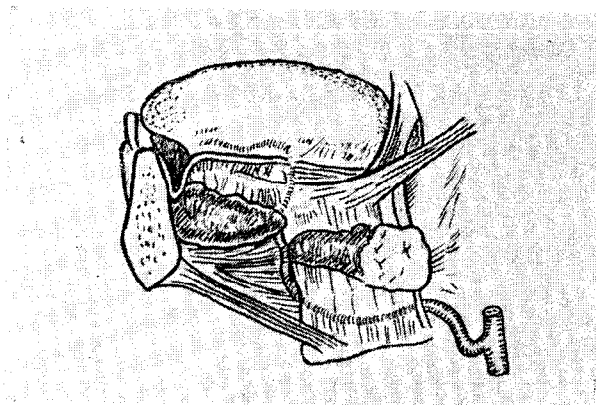


Fig. 1. The anatomy of the lingual artery.

part of the artery lies over the middle constrictor and is crossed by the stylohyoid ligament. The third part of the artery, the arteria profunda linguae bends sharply upwards near the anterior border of the hyoglossus, over the genioglossus muscle and then runs forward close to the inferior surface of the tongue accompanied by the lingual nerve to anastomose at the tip of the tongue with its counterpart of the opposite side.

The hyoglossus is cut at its hyoid attach-

\*Presented at the Annual conference of the Association of Plastic Surgeons of India, 1989 held at Varanasi and was awarded the Peet Prize.

ment and we identify the entire course of the lingual artery till it bends anteriorly to run forward near the inferior surface of the tongue, lift the artery and venae comitantes off the middle constrictor and genioglossus and fashion an island of myo-mucosal tissue on this isolated vasculature (Fig. 2). A thin sleeve of genioglossus is taken medial to the lingual artery

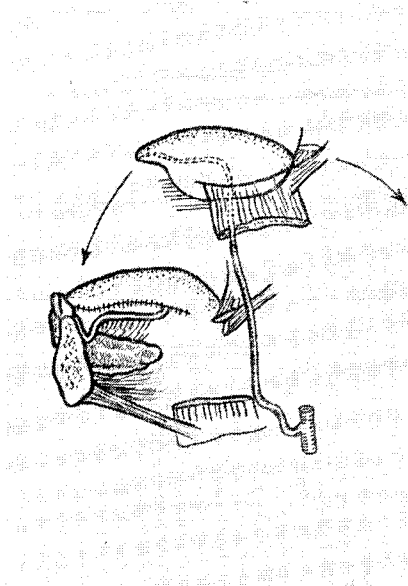


Fig. 2. The concept of the Island tongue flap with its pivot point at the site of origin of the artery from the external carotid artery. Note the arc of rotation and primary closure of the donor area.

and the island thus isolated is swung to the recipient site. Only those dorsal linguae branches are divided which are barely essential to give the flap an adequate reach and necessary are of rotation and an attempt is made to preserve as many of them as possible. The sublingual and the suprahyoid branches of the lingual artery are sacrificed in order to straighten the parent lingual artery.

### Material and Method

24 cases of advanced oral cancer ( $T_3$  &  $T_4$ ) were chosen for this study. 15 of them had palpable lymphnodes in the neck. The site of

lesion in all these patients is given in (Tab. 1) A hemimandibulectomy with functional neck dissection was done in all these patients. The

Table 1. Showing the site of lesion

Check	..	4
Alveolus	..	17
Tonsillar area	..	3
Total	..	24

lining mucosal defect produced in each of them was covered by an island tongue flap based on the ipsilateral lingual artery. The artery was identified at it originated from the external carotid artery and after dividing the hyoglossus muscle at the level of the hyoid it was lifted off the genioglossus and followed till it turned anteriorly into the substance of the tongue. The required dimension of the flap was harvested from the lateral margin of the tongue (Fig. 3) encroaching on the dorsal and ventral surfaces as required by dividing a sleeve of genioglossus medial to the lingual artery and the styloglossus muscle posteriorly. The donor area was primarily closed (Fig. 4) and the flap, now with a pivot point at the origin of the lingual artery, was taken to the recipient site and sutured with interrupted vicryl sutures. Tongue tissue takes sutures very poorly because the ventral orothelium is very thin. Buttressing of every suture with the cut muscles—hyoglossus and genioglossus is required to avoid sutures biting through the tongue mucosa.

If there was an associated covering skin defect, it was covered by either a limberg cervical skin flap or a sternomastoid myocutaneous flap. Bone was not replaced. The neck and submandibular dissections were both drained by suction drains and a nasogastric tube was introduced before reversal of anaesthesia. Post-operatively the suction drains were removed after 48-72 hours and regular antiseptic mouth washes were advocated.

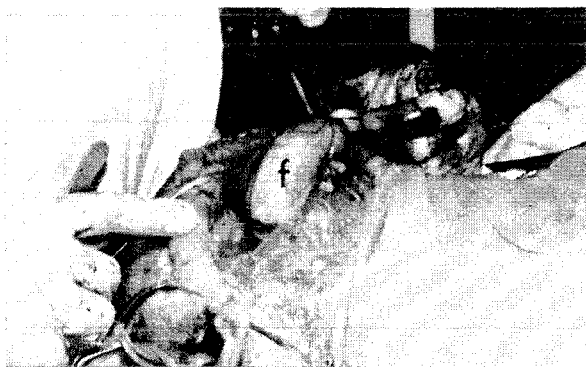

Fig. 3. Island tongue flap (f) being harvested from the perimeter of the tongue, encroaching both the dorsal and the ventral aspect of the tongue.

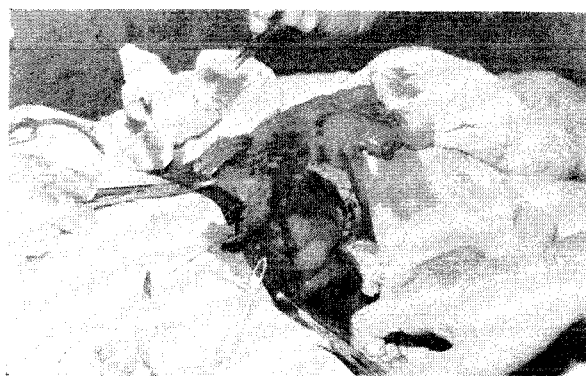

Fig. 4. The flap (f) has been harvested and the donor area is being primarily closed.

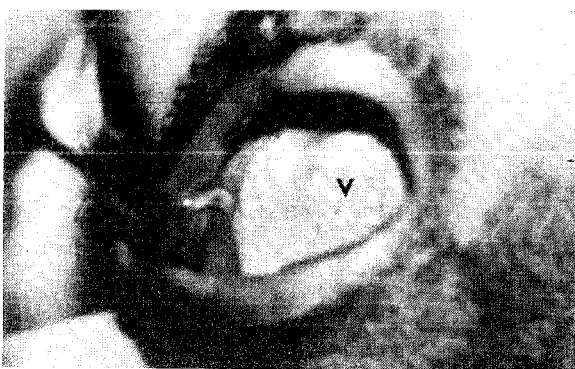


Fig. 5. The healed island tongue flap lining the buccal cavity and the oropharynx. Note the veins (v) on the pharyngeal wall which originally were on the ventral aspect of the tongue.

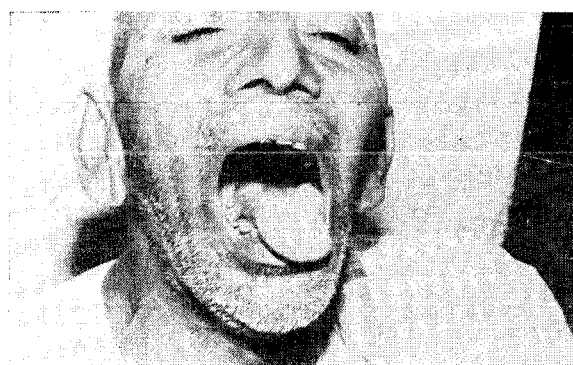


Fig. 6. The tongue from which an island tongue flap has been harvested from the left side. Note that it protrudes well beyond the incisors, but deviates to the affected side.

### Observations

All the 24 island tongue flaps healed without any haematoma, infection or necrosis (Fig. 5). The patients were allowed orally on the 8th to 10th post-operative day and there were no salivary fistulae in any of them. Three months after surgery 21 patients were able to protrude their tongue tip beyond the incisors (Fig. 6) and had no appreciable difference in speech. The remaining 3 patients with very large tongue flaps covering a defect from just inside their angle of mouth to the anterior tonsillar pillar could speak understandably well with perfect labiodental and labioalveolar articulations, but were unable to protrude

their tongue beyond the incisors. There was no appreciable change in perception of taste in any of these patients. However, the portion of the tongue used as a flap was neither able to perceive tactile sensations nor taste sensations. None of the patients complained of drooling of saliva or problems in swallowing post-operatively.

### Discussion

Before effective reconstructive procedures were envisaged intra-oral defects following ablative cancer surgery were invariably closed by primary closure. This often meant hitching the tongue to the margins of the defect

thus tethering it and rendering it incapable for free movement during speech, disposal of saliva and swallowing. As on most occasions the hemimandible too was removed, the cheek would collapse medially thus increasing the tongue mobility with the passage of time and thereby improving its functions partially.

The use of tongue flaps for intra-oral reconstruction was popularised by Conley et al. (1957), McGregor (1966), Papaioannou and Farr (1966), Som et al. (1971) and many other contemporary surgeons. Bakamjian (1971) raised anteriorly and posteriorly based flaps from the dorsum of the tongue and Calamel (1973) fashioned the median transit tongue flap for reconstructing defects in the floor of mouth. All these flaps lead to variable degree of tethering of the tongue and subsequent difficulty in speech. The best use of tongue flaps, thereby, was on occasions when it was either used to reconstruct palatal defects (Klop, 1956; Guerrero-Santos et al., 1966; Jackson, 1972 and Massangerill et al., 1970) or labial defects involving loss of vermillion (Bakamjian, 1964; Franca, 1971; Guerrero-Santos et al., 1964) as for both these sites no other alternative flap with so close a colour and texture match was easily available. Even congenital anomalies in lip and palate were reconstructed with the help of lingual tissue (Jackson, 1972) and for labial reconstruction, perimeter tongue flap still remains the flap of choice.

The conventional dorsal tongue flap (Bakamjian, 1971) whether anteriorly or posteriorly based has a large portion of it being used as the pedicle. Since this portion of the flap takes no part in covering the intra-oral defect a relatively larger flap is required for a small defect. Again by virtue of its anchoring action to the recipient area, it renders the donor tongue loose some amount of its mobility. Furthermore, because a relatively larger flap has to be harvested, there is more loss of muscular substance in the donor tongue, which further adds to its tethering. Prakash and Ramakrishnan (1980) modified the conven-

tional split tongue flap by cutting the base of the flap all around without traversing the musculature. Thus an island of tongue mucosa was based on its muscles, the later serving as its pedicle. This turn table tongue flap could be swung  $1/6$  to  $1/4$  of a circle and stitched to the edges of the mucosal defect. This modification reduced the tongue tethering to some extent, but as the donor tongue and the flap shared the same muscles tethering was not totally avoided. The Island tongue flap by virtue of its circumferential muscular division as well, minimizes tethering maximally. Again, because no part of the tongue mucosa or muscles are being used to form the pedicle only that portion of the tongue needs to be sacrificed which fits into the lining defect. Thus, the loss of substance of muscles and mucosa is minimal and in none of the 24 flaps did we sacrifice the tip of the tongue.

The tongue performs three important functions which are speech, disposal of saliva and swallowing. Of all the known flaps of tongue, the Island tongue flap interferes least with these three functions. Resection of any part of the tongue in order to harvest a flap results in denervation, loss of substance, loss of muscle origin and tethering. All these problems are least encountered with an Island tongue flap. The fact that 21 out of 24 donor tongues could be protruded in front of the incisors and none of them had any appreciable speech defect, drooling of saliva or difficulty in swallowing, is an eloquent testimony to the superiority of this flap over all other previously known flaps of the tongue. The protruded tongue deviates to the affected side (Fig. 6) by the unopposed action of the healthy genioglossus and a lemon drop may not be held by a concavity created on the dorsal aspect of the tongue as the hyoglossus is divided on the flap side, but these are small prices to pay.

Normally the tongue is a very mobile structure. It can be moved rapidly and precisely. When it functions in conjunction with other oral articulators, it participates in the produc-

tion of speech by channeling, impeding and obstructing the breath stream as it passes through the mouth. It also assists in modifying the resonance cavities used in speech. While in the case of vowels the only place where the breath stream is set into vibration is the larynx (Jhonson et al., 1967), in case of consonants the vocal tract is constricted or obstructed in a particular way at some location above the larynx forcing the breath stream, to be constricted, diverted or obstructed momentarily. For many consonants this constriction or obstruction of breath stream becomes a source of noise vibration which are hence added to the laryngeal sound. In an attempt to classify the consonants according to the place of articulation, i.e. according to the place where major constriction of articulators occur to obstruct or impede the breath stream, we find that the tongue is responsible for producing lingua-

dental (*there, thumb*), alveolar (*doll, tongue, zipper, soap, jar, chair, nose, leaf*) palatal (*rabbit*) and velar (*girl, kiss, ring*) sounds. Of these the linguadental, alveolar and palatal sound production requires the full length of the tongue, as it is produced by the tip of the tongue and distal  $\frac{1}{4}$  of the tongue. The Island tongue flap when fashioned from the perimeter succeeds in conserving the entire length of the tongue and does least damage to its mobility, thus preserving the effortless production of these sounds.

### Results

22 patients have been followed up from 3 months to 18 months. 7 of them have had a recurrence between 9-13 months following surgery and 4 of them have died. 15 patients are having disease free survival, 3 of them being disease free after 1 year.

### REFERENCES

1. BAKAMJIAN, V. : Use of tongue flap in lower lip reconstruction. *Brit. J. Plast. Surg.* 1964; 17 : 76.
2. BAKAMJIAN, V. : Anteriorly and posteriorly based flaps from the dorsum of the tongue. In: J. Conley and J. T. Dickinson (Eds.), *Proceedings of the First International Symposium on Plastic and Reconstructive Surgery of the Face and Neck.* Stuttgart : Thieme, 1971; 2 : 158.
3. BRACA, A. : The blood supply of dorsal tongue flaps. *Brit. J. Plast. Surg.* 1981; 34 : 379.
4. CADENT, H., COMBELLE, R. AND FABIC, M. : Lambeaux de langue vascularisation, morphologie et utilisation. *Ann. Chir. Plast.* 1973; 18 : 223.
5. CALAMEL, P. M. : The median transit tongue flap. *Plast. Reconstr. Surg.* 1973; 51 : 315.
6. CONLEY, J. J., DE AMESTI, F. AND PIERCE, M. K. : Use of tongue flap in Head and Neck Surgery. *Surgery*; 1957, 41 : 745.
7. FRANCA, J. G. : Lip reconstruction using lingual graft. *Rev. Assoc. Med. Bras.* 1971; 17 : 123.
8. GUERRERO-SANTOS, J. AND ALTAMIRANO, J. T. : The use of lingual flaps in repair of fistula of hard palate. *Reconstr. Surg.* 1966 : 38 : 123.
9. GUERRENO-SANTOS, J., VAZQUEZ PALLARES, R., VERA STRATHMANN, A., MACHAIN, P. AND CASTANEDA, A. : Tongue flap in reconstruction of lip. *Transactions of 3rd International College of Plastic Surgeons, Amsterdam, Excerpta Medica Foundation*, 1964; 1055.
10. JACKSON, I. T. : Use of tongue flaps to resurface lip defects and close palatal fistula in children. *Plast. Reconstr. Surg.* 1972 ; 49 : 537.
11. JHONSON, W., BROWN, S. F., CURTIS, J. F., EDNEY, C. W. AND KEASTER, J. : *Speech Handicapped School Children*, New York, Harper and Brothers, 1967.
12. KLOPP, C. T. AND SCHURTER, M. : Reconstruction of palate with tongue flap and repair of tongue. *Cancer*, 1956; 9 : 1.
13. MASSANGERILL, R., PICKERELL, K. AND MALDICK, R. : Lingual flaps; Effect on speech articulation and physiology. *Ann. Otol. Rhinol. Laryngol.* 1970; 79 : 853.
14. MC GREGOR, I. A. : The tongue flap surgery. *Brit. J. Plast. Surg.* 1966; 19 : 253.
15. PAPAIOANNOU, A. AND FARR, H. : Reconstruction of the floor of mouth by a pedicle tongue flap. *Surg. Gynecol. Obstet.* 1966; 122 : 807.

16. PRAKASH, S. AND RAMAKRISHNAN, K. : Turntable and a two staged forked flap in primary reconstruction after excision of oral carcinomas. *Plast. Reconstr. Surg.* 1980; 65 : 580.

**The Authors**

- DR. S. BHATTACHARYA, *Pool Officer, Surgery (Oncology), K. G.'s Medical College, Lucknow, India.*  
DR. A. CHATURVEDI, *Lecturer, Surgery (Oncology), K. G.'s Medical College, Lucknow, India.*  
DR. M. S. D. JAISWAL, *Reader, Surgery, K. G.'s Medical College, Lucknow, India.*  
DR. S. K. BHATNAGAR, *Reader, Plastic Surgery, K. G.'s Medical College, Lucknow, India.*  
DR. N. C. MISRA, *Professor, Surgery (Oncology), K. G.'s Medical College, Lucknow, India.*

**Request for Reprints**

DR. S. BHATTACHARYA, C-907, Mahanagar, Lucknow-226 006, India.