



# Medial Shoulder Instability: Prevalence and Treatment Outcomes in 17 Poodles and 31 Dogs of Other Breeds

E.L.E. Woolley<sup>1</sup> T.A. Collyer<sup>2</sup> S.J. Finch<sup>3</sup> A.K. House<sup>1</sup>

<sup>1</sup>Department of Surgery, Peninsula Vet Emergency and Referral Hospital, Mornington, Victoria, Australia

<sup>2</sup>Peninsula Clinical School, Monash University Peninsula Campus, Frankston, Victoria, Australia

<sup>3</sup>Statistical Consulting Centre, School of Mathematics and Statistics, The University of Melbourne, Victoria, Australia

**Address for correspondence** E.L.E. Woolley, BVM&S, MRCVS, MANZCVS (Surgery), Department of Surgery, Peninsula Vet Emergency and Referral Hospital, Unit 2 161 Mornington-Tyabb Road, Mornington, Victoria 3931, Australia (e-mail: eleanor@penvetreferral.com.au).

VCOT Open 2023;6:e107–e113.

## Abstract

**Objective** The aim of this retrospective multicenter study was to investigate whether poodles were overrepresented in a cohort of dogs with medial shoulder instability (MSI), and to compare the incidence of spontaneous (nontraumatic) MSI and treatment outcome in poodles and non-poodle dogs.

**Study Design** Medical records (2009–2019) of dogs with MSI from five surgical referral centers were reviewed.

**Results** Forty-eight dogs with confirmed MSI were enrolled; 17 (35%) of which were poodles and 31 (65%) were of other breeds (including 11 [23%] poodle crossbreeds). Poodles were more than 10 times overrepresented in the MSI populations ( $p < 0.0001$ ) compared with other breeds. MSI occurred spontaneously in 82% of poodles and 52% of non-poodles; the odds of presenting with spontaneous MSI for poodles were four times greater than that for non-poodle breeds. There were no differences in terms of treatments and outcomes.

**Conclusion** Poodles were significantly overrepresented in the cohort of dogs presenting with MSI and were more likely to have spontaneous rather than traumatic MSI.

## Keywords

- ▶ dogs
- ▶ medial shoulder instability
- ▶ poodle

## Introduction

Approximately a third of all canine forelimb joint lameness cases occur due to shoulder pathology, with 17.7% of those being caused by instability<sup>1</sup> and 64 to 80% of shoulder instabilities occurring medially.<sup>2–4</sup> Medial shoulder instability (MSI) is characterized by medial glenohumeral ligament (MGHL) pathology, including tears, laxity or avulsion, as seen in the majority of cases,<sup>5</sup> subscapularis tendinopathy, and labral or capsular tears. Cases of MSI can be classified as either traumatic or spontaneous in etiology, with 49% reported in one study as a traumatic tearing of the MGHL.<sup>6</sup> A grading system has been described for the severity of MSI, classifying cases into grade 1 to 4, which correlate to

mild, moderate, severe, and luxated, respectively,<sup>7,8</sup> see **▶ Appendix A**. The accepted “normal abduction angle” has been shown to be approximately 30 degrees<sup>9</sup> and, although past studies suggested that abduction angles could be used to diagnose MSI, it has since been shown that significant variation occurs between observers measuring abduction angles, that abduction angles do not closely correlate to arthroscopic pathology, and that abduction angles of up to 75 degrees may be observed in normal joints.<sup>10–13</sup> Hence a diagnosis of MSI cannot be based upon abduction angle measurement alone. In cases of instability/subluxation (MSI grade 1–3), arthroscopy is required to confirm the diagnosis; luxation (MSI grade 4) can be diagnosed from radiographs.

received  
November 23, 2022  
accepted after revision  
July 12, 2023

DOI <https://doi.org/10.1055/s-0043-1774372>.  
ISSN 2625-2325.

© 2023. The Author(s).

This is an open access article published by Thieme under the terms of the Creative Commons Attribution License, permitting unrestricted use, distribution, and reproduction so long as the original work is properly cited. (<https://creativecommons.org/licenses/by/4.0/>)  
Georg Thieme Verlag KG, Rüdigerstraße 14, 70469 Stuttgart, Germany

**Table 1** Nonsurgical and surgical treatment options for medial shoulder instability

Treatment category	Options
Nonsurgical	<ul style="list-style-type: none"> <li>• Rest</li> <li>• Nonsteroidal anti-inflammatory drugs</li> <li>• External coaptation</li> <li>• Physiotherapy</li> <li>• Intra-articular treatments:               <ul style="list-style-type: none"> <li>–Platelet-rich plasma (PRP)</li> <li>–Hyaluronic acid</li> <li>–Corticosteroids</li> </ul> </li> </ul>
Surgical stabilization of medial instability	<ul style="list-style-type: none"> <li>• Radiofrequency-induced thermal capsulorrhaphy (RITC)</li> <li>• Subscapularis imbrication</li> <li>• Prosthetic reconstruction of medial glenohumeral ligament               <ul style="list-style-type: none"> <li>–Open/arthroscopically guided techniques</li> <li>–Implant choice with bone screws/bone anchors/bone tunnels, e.g., Arthrex SutureTak anchor with FiberWire suture<sup>a</sup>, Arthrex Mini Tightrope<sup>b</sup> via bone tunnels</li> </ul> </li> <li>• Biceps tendon transposition (BTT)</li> <li>• Supraspinatus tendon transposition</li> </ul>
Surgical salvage	<ul style="list-style-type: none"> <li>• Shoulder arthrodesis</li> <li>• Excisional arthroplasty of glenoid or humeral head</li> <li>• Forequarter amputation</li> </ul>

<sup>a</sup>FiberWire suture, Arthrex Inc., Naples, FL.

<sup>b</sup>ACL Tightrope System, Arthrex Inc., Naples, FL.

Study populations to date have consisted predominantly of large and medium breed dogs, often performance dogs, with poodles and their crossbreeds appearing to be consistently overrepresented in the few small-breed subjects included.<sup>6,9,14–16</sup> Based on a literature search (PubMed, search criteria: “medial shoulder instability, medial glenohumeral ligament, abduction angle, subluxation, and poodle”), few data points were identified that characterized the etiology of MSI in dogs with respect to breed.

Current described treatment options include both nonsurgical and surgical management (see ►Table 1).<sup>6,7,14,15,17–24</sup> Surgery aims to reconstruct medial stability via tendon augmentation or prosthesis implantation. There are variations in MGHL reconstruction techniques and implants, with the consistent aim to reconstruct the medial support for the glenohumeral joint,<sup>14,15,19–22,25</sup> maintaining joint alignment and normal biomechanics. Biceps and supraspinatus tendon transpositions have independently been shown to provide improved medial stability.<sup>6,26</sup> However, biceps tendon transposition (BTT) has been shown to result in increased external rotation of the joint and an increased abduction angle in comparison to placing a MGHL prosthesis, and both tendon transpositions have, in time, been shown to cause such altered shoulder biomechanics and congruity that degenerative changes will develop.<sup>22,23</sup>

In our experience, poodles and their crossbreeds appear to be at elevated risk of MSI, with a high proportion of cases presenting spontaneously (without having sustained significant trauma) and having an unpredictable outcome in response to treatment. This led us to undertake this study.

We hypothesize that poodles may be overrepresented in the local investigated population of dogs presenting with MSI. Additionally, we hypothesize that poodles exhibit higher rates of spontaneous MSI than non-poodle breeds.

Finally, we wanted to investigate whether poodles may end up with a generally poorer treatment outcome, either through conservative or surgical management, as compared with non-poodle breed dogs.

## Materials and Methods

### Data Collection

Data were obtained retrospectively from the clinical records spanning 2009 to 2019 from five referral small animal veterinary hospitals in Melbourne, Australia. Records were searched for all dogs presenting with lameness attributable to MSI, with database searches performed using the following search terms: canine, medial shoulder instability, medial glenohumeral ligament, abduction angle, subluxation, and luxation, in RxWorks, EzyVet, and CiderHouse software programs. For each dog, data were collected regarding the signalment, affected limb, abduction angle if noted, the level of inciting trauma, the initial treatment, arthroscopic and surgical findings, postoperative outcome, and follow-up treatments. The grade of MSI was recorded for each case; cases that had not been graded were retrospectively assigned according to the previously described grading system.<sup>7,8</sup>

Breeds were classified as poodle (P) and non-poodle (NP). Where the dog was recorded as a poodle-cross or mixed breed it was allocated to the NP group. For the means of analysis of injury data, bilaterally affected animals were included only as one case, with their first diagnosis of MSI as their indexed event, and their subsequent presentation was excluded. Classification of the etiology of the instability was recorded as either spontaneous (dogs with no known trauma or whose lameness occurred during normal physiological activity, such as jumping off one step or a couch, or pawing at the carpet) or traumatic (dogs known to have

sustained a low impact trauma such as having been chasing a ball or at agility training when the lameness occurred). Cases with medial shoulder luxation after sustaining high impact trauma such as being hit by a car or falling from a height were deemed to have traumatic shoulder luxation rather than shoulder instability and hence excluded. Other exclusion criteria included glenohumeral dysplasia and comorbidities that may contribute to glenohumeral instability such as immune-mediated polyarthritis. Cases were included if forelimb lameness was present, a diagnosis of MSI was confirmed via shoulder arthroscopy visualizing pathology in the MGHL and/or subscapularis tendon, or via radiographic confirmation of medial luxation of the humeral head without having sustained high impact trauma, consistent with grade 4 MSI.

Treatment was classified as either conservative, reconstructive surgical (included MGHL reconstruction or BTT), or treatment with a salvage procedure (excisional arthroplasty, glenohumeral arthrodesis, or forequarter amputation). Given the multi-center cohort study, conservative management was considered as a combination of rest, nonsteroidal anti-inflammatory drugs, intra-articular steroid/stem cell/platelet-rich plasma treatments, physical therapy, use of hobbles, orthopaedic braces, splints, or slings.

The conclusion for each case was recorded as full (restoration to/maintenance of full intended level and duration of activities and performance from preinjury or pre-disease status, without medication), acceptable (restoration to/maintenance of intended activities and performance from preinjury or pre-disease status that is limited in level or duration and/or requires medication to achieve), or unacceptable (all other outcomes), as described by Cook et al,<sup>27</sup> according to examination by the primary clinician and/or assessment by the owner. Any dog where conservative management resulted in an unacceptable outcome that went on to have surgical treatment was allocated to the surgical treatment category. For dogs with incomplete postoperative follow-up documentation, owners were contacted by telephone/email to obtain postoperative outcome information. All data were retrospectively collected and no attempt made to assess individual limb function beyond interpreting clinical records and owner reports.

### Statistical Analysis

Breeds were grouped as poodles (P) and non-poodles (NP) for analysis.

The age and sex distribution between the injured P and NP groups were compared using independent samples *t*-test with unequal variance and  $\chi^2$  test, respectively.

### Breed Prevalence

To evaluate breed prevalence, a control population was generated by searching the records of a general practice group of veterinary clinics in the same geographical area to determine the breeds of dogs registered. A one sample proportion test was used to test the null hypothesis that the MSI group breed prevalence was consistent with the control population breed prevalence.

Relationship between grade of MSI and breed was explored via univariate linear regression, with grade as outcome and breed as the independent variable.

### Cause

A logistic regression was used to estimate the relative odds of a spontaneous cause of the MSI according to breed type.

### Outcome

Case numbers were too few to allow analysis of outcome according to breed or treatment. Descriptive statistics are provided.

A 95% confidence interval (CI) is reported for each estimate of the relative odds, along with a *p*-value for a test of the null hypothesis that the relative odds are one.

All analysis was undertaken in Stata V16 (StataCorp. 2019. Stata Statistical Software: Release 16. College Station, TX: StataCorp LLC).

## Results

Seventy-four dogs were identified with MSI, including 12 bilaterally affected (3P, 9NP). Of these, 13 were excluded: 6 due to evidence of high impact trauma (1P, 5NP), 4 due to glenohumeral dysplasia (1P, 3NP), and 3 due to potentially contributing comorbidities (3NP), leaving 61 dogs with presumed MSI, diagnosed in clinical records by a combination of abduction angle assessment, radiographs, and arthroscopic assessment. Given the limitation of diagnosis of grade 1–3 MSI based on palpation and radiographic assessment alone,<sup>10–13</sup> inclusion criteria required confirmation via arthroscopic examination for all grade 1–3 cases ( $n = 11$ ; 2P, 9NP) and/or radiographic evidence of medial luxation of the humeral head for grade 4 MSI ( $n = 37$ ; arthroscopic diagnosis in 18 = 7P, 11NP; radiographic diagnosis in 19 = 8P, 11NP). Lack of confirmation of diagnosis by these methods excluded a further 13 dogs. The 48 dogs that met the criteria for study inclusion were divided according to breed, P ( $n = 17$ ) and NP ( $n = 31$ , see ►Table 2). An independent samples *t*-test and  $\chi^2$  test revealed no statistically significant difference in mean age or sex respectively between the two resulting groups (estimated mean age difference (P – NP) = 0.70 years, 95% CI = -1.96–3.35,  $p = 0.60$ ; Pearson,  $\chi^2 = 1.95$ ,  $p = 0.58$ ).

### Breed Prevalence

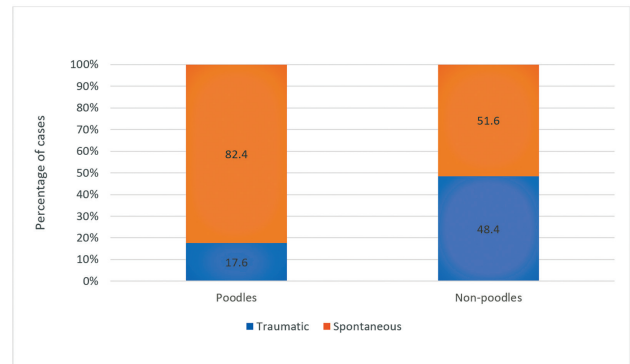
In the control population, 82,956 dogs were identified, within which there were 2,267P, representing a control population prevalence of 2.73% P (95% CI: 2.62–2.85%). Poodles represented 35.4% (95% CI: 21.9–48.9%) of the MSI population (see ►Fig. 1). Utilizing a one sample test that the true proportion was that of the control population, we found that P were 12.9 times overrepresented in the MSI population, *p*-value less than 0.0001.

There were 4 dogs with grade 2 MSI (1P, 3NP), 7 with grade 3 (1P, 6NP), and 37 with grade 4 (15P, 22NP), see ►Fig. 2. Linear regression showed that although P were more likely to present with higher grade MSI than NP, the difference was not significant ( $p = 0.26$ ).

**Table 2** Breed distribution of MSI cases

Group	Total number of dogs	Breeds included
Poodle "P"	17	Poodle (miniature/toy; n = 17)
Non-poodle "NP"	31	Australian Shepherd (1) Border Collie (3) Boxer (1) Cavalier King Charles Spaniel (1) Chihuahua (1) Fox Terrier (1) Greyhound (1) Jack-Russell Terrier-cross (1) Japanese Spitz (2) Kelpie (1) Maltese-cross (1) Pomeranian (1) Poodle-cross (Cavalier King Charles Spaniel, Cocker Spaniel, Labrador, Maltese Terrier, unknown; n = 11) Rottweiler (1) Shih-tzu-cross (1) Staffordshire Bull Terrier (1) West Highland White Terrier (1) Whippet (1)

Abbreviation: MSI, medial shoulder instability.



**Fig. 3** Graph showing percentage of each breed group presenting with traumatic and spontaneous MSI. MSI, medial shoulder instability.

**Cause**

For 30 of the 48 dogs (62.5%), the MSI was spontaneous. This included 14 of 17P, and 16 of 31NP (see ►Fig. 3).

Poodles were more likely to suffer spontaneous than traumatic MSI, with 82.4% of P (95% CI: 56.6–96.2%) suffering spontaneous MSI.

A logistic regression was used to estimate the relative odds of spontaneous MSI.

For P, the odds of MSI occurring spontaneously were four times greater than NP ( $p=0.04$ , odds ratio: 4.38, 95% CI: 1.04–18.32).

**Outcome**

Cases that did not represent for assessment and for whom no response was obtained through telephone/email communication were deemed lost to follow-up ( $n=11$ ; 5P, 6NP).

Overall, outcome information was available for 37 dogs (see ►Table 3): 17 dogs had return to full function (4P, 13NP; 45.9%), 13 acceptable (6P, 7NP; 35.1%), and 6 unacceptable (2P, 4NP; 16.2%). One animal was euthanised due to unrelated comorbidities (1NP; 2.7%).

Return to full, acceptable, and unacceptable function for P was seen in 4 (33.3%), 6 (50.0%), and 2 (16.7%) respectively, and for NP was seen in 13 (54.2%), 7 (29.2%), and 4 (16.7%), respectively (see ►Fig. 4).

Conservative management was selected for 25 dogs (9P, 16NP), while MGHL reconstruction was performed in 14 dogs (5P, 9NP), BTT in 7 dogs (3P, 4NP), and salvage procedures as first choice surgery in 2 dogs (2NP).

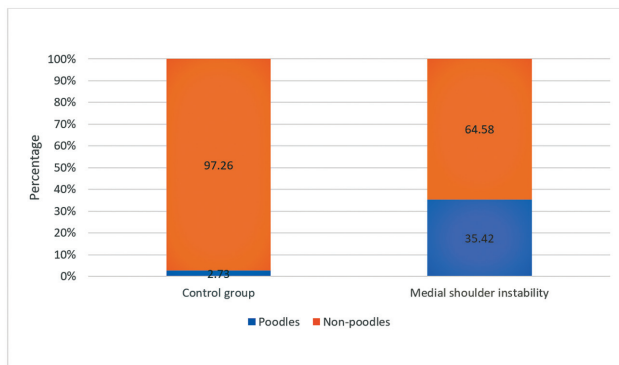
Conservative management resulted in full function in 8 cases (47.0%; 1P, 7NP) and acceptable function in 9 (52.9%; 4P, 5NP).

Surgical management had the following outcomes:

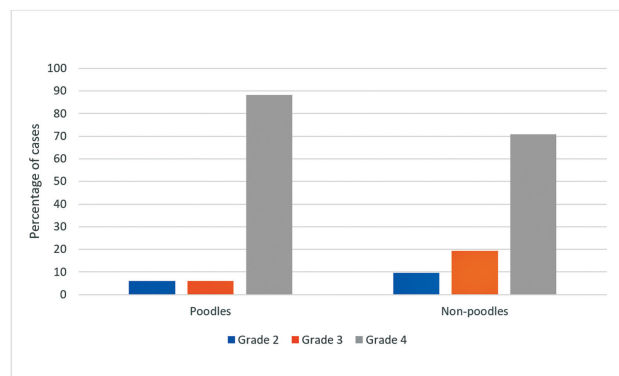
MGHL reconstruction achieved full function in 4 cases (36.4%; 4NP), acceptable in 3 (27.3%; 2P, 1NP), and unacceptable in 4 (36.4%, 2P, 2NP).

BTT achieved full function in 5 cases (83.3%, 3P, 2NP) and acceptable in 1 (16.7%, 1NP).

Overall, surgical stabilization (MGHL or BTT) resulted in full function in 9 cases (52.9%; 3P, 6NP), acceptable in 4 (23.5%; 2P, 2NP), and unacceptable in 4 (23.5%; 2P, 2NP).



**Fig. 1** Graph showing percentage of poodles and non-poodles in the control group and MSI cohort. MSI, medial shoulder instability.

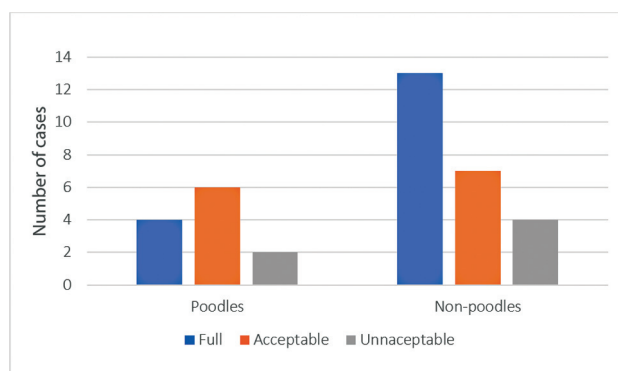


**Fig. 2** Graph showing MSI grade distribution within each breed population. MSI, medial shoulder instability.

**Table 3** Outcome by treatment type and breed for all cases of MSI

Treatment type	Breed population	Cases with follow-up, n	Full function, n (%)	Acceptable function, n (%)	Unacceptable function, n (%)
Overall	Poodles	12	4 (33.3)	6 (50.0)	2 (16.7)
	Non-poodle	24	13 (54.2)	7 (29.2)	4 (16.7)
Conservative	Overall	17	8 (47.0)	9 (52.9)	0 (0)
	Poodles	5	1 (20.0)	4 (80.0)	0 (0)
	Non-poodle	12	7 (58.3)	5 (41.7)	0 (0)
Surgical	Overall	17	9 (52.9)	4 (23.5)	4 (23.5)
	Poodles	7	3 (42.8)	2 (28.5)	2 (28.5)
	Non-poodle	10	6 (60.0)	2 (20.0)	2 (20.0)
	MGHL reconstruction overall	11	4 (36.4)	3 (27.3)	4 (36.4)
	Poodles	4	0 (0)	2 (50.0)	2 (50.0)
	Non-poodle	7	4 (57.1)	1 (14.3)	2 (28.6)
	BTT overall	6	5 (83.3)	1 (16.7)	0 (0)
	Poodles	3	3 (100.0)	0 (0)	0 (0)
	Non-poodle	3	2 (66.6)	1 (33.3)	0 (0)

Abbreviations: BTT, biceps tendon transposition; MGHL, medial glenohumeral ligament.



**Fig. 4** Graph showing overall outcome percentages for poodles and non-poodles.

Within the 31 NP dogs there were 11 poodle crossbreeds, of which 9 presented with spontaneous MSI, showing a similar trend of overrepresentation and high incidence of spontaneous MSI to that seen with poodles (see ► **Table 4**).

## Discussion

Our data show that poodles presenting with MSI are overrepresented in the local population of dogs, and that they are over four times as likely to present with spontaneous MSI than other breeds. Why poodle breeds are overrepresented is unknown. When considering joint instability, two variables need to be considered: soft tissue laxity and joint anatomy. These factors have the potential to cause instability independently, though the possibility of an interplay between the two exists, as seen with other polygenic, multifactorial traits in dogs such as hip dysplasia<sup>28</sup> and patellar luxation.<sup>29</sup> The absence of glenoid

dysplasia shows that this is not the cause of MSI in our population, and hence, without note of other orthopaedic anatomical variations, suggests that an increase in soft tissue laxity is the likely explanation for the joint instability affecting these dogs. Whether or not this is due to an underlying hypermobility syndrome warrants further investigation.

While a higher percentage of P presented with grade 4 MSI than NP, there was not a statistically significant difference in the grades by breed. This may be a statistical power problem, with too few P cases to be compared with the NP or may reflect a true lack of difference. More testing would need to be performed to investigate this.

Our results showed that 82.4% of P affected by MSI within our local dog population occurred spontaneously, while 51.6% of NP MSI occurred spontaneously (48.4% traumatic). The latter rate of incidence is consistent with previous findings of 49% of MSI cases being reported as a traumatic tearing for the MGHL,<sup>6</sup> likely reflecting the breed populations within previous studies and reinforcing the notion that poodles are different to other breeds.

The high number of poodle crossbreeds within the NP group, of which the vast majority presented with spontaneous MSI, suggests that poodle crossbreeds, often bred to be at least 50% poodle genome,<sup>30</sup> are similarly at risk as poodles. Further studies into this are warranted.

Our data suggests that P are associated with a higher risk of a poorer outcome following management of MSI. Outcome following management of MSI would benefit from further investigation with prospective studies evaluating standardized approaches.

There are shortcomings of this study, such as the retrospective nature inheriting a selection bias and the high number of



**Table 4** Summary of MSI case numbers by breed (showing poodle crossbreeds separated out from non-poodles), cause, grade, treatment, and outcome

Breed group	Number of cases		Cause		MSI grade				Treatment				Outcome					
	Control group	Cases included	Cases confirmed	Traumatic	Spontaneous	1	2	3	4	Conservative	MGHL	BTT	Salvage	Full	Acceptable	Unacceptable	Lost	Other
Poodles	2,267	20	17	3	14	0	1	1	15	9	5	3	0	4	6	2	5	0
% of total	2.73		35.42															
Poodle crossbreeds	5,827	14	11	2	9	0	0	3	8	4	4	1	2	3	3	3	2	0
% of total	7.02		22.91															
Non-poodles	74,862	27	20	13	7	0	3	3	14	12	5	3	0	10	4	1	4	1
% of total	90.25		41.67															
Totals	82,956	61	48	18	30	0	4	7	37	25	14	7	2	17	13	6	11	1

Abbreviations: BTT, biceps tendon transposition; MGHL, medial glenohumeral ligament; MSI, medial shoulder instability.

cases lost to follow-up. The study was also limited by the relatively small dataset, enhanced by the fact that many clinicians were willing to diagnose MSI based on palpation and radiographs alone which led to exclusion of 13 potential grade 1–3 MSI cases. Larger studies are warranted.

### Conclusion

Our data show that poodles were overrepresented in the local population of dogs presenting with MSI in general as well as with spontaneously occurring MSI. This has significant clinical relevance, placing MSI higher up on the differential list for poodles presenting with forelimb lameness, irrespective of whether they have sustained trauma or not.

### Note

This study received data contributions from Advanced Vet Care, 26 Robertson St., Kensington VIC 3031; CARE Veterinary Hospital, 5 Hood St., Collingwood VIC 3066; Peninsula Vet Emergency and Referral Hospital, 161/2 Mornington-Tyabb Road, Mornington VIC 3931; Southpaws Specialty Surgery 3 Roper St., Moorabbin VIC 3189; and Veterinary referral Hospital 36 Lonsdale St, Dandenong VIC 3175.

### Conflict of Interest

None declared.

### References

- Johnson JA, Austin C, Breur GJ. Incidence of canine appendicular musculoskeletal disorders in 16 veterinary teaching hospitals from 1980 through 1989. *Vet Comp Orthop Traumatol* 1994;7:56–69
- Bardet JF. Shoulder diseases in dogs. *Vet Med* 2002;97:909–918
- Cogar SM, Cook CR, Curry SL, Grandis A, Cook JL. Prospective evaluation of techniques for differentiating shoulder pathology as a source of forelimb lameness in medium and large breed dogs. *Vet Surg* 2008;37(02):132–141
- Cook JL, Cook CR. Bilateral shoulder and elbow arthroscopy in dogs with forelimb lameness: diagnostic findings and treatment outcomes. *Vet Surg* 2009;38(02):224–232
- Bardet JF. Diagnosis of shoulder instability in dogs and cats: a retrospective study. *J Am Anim Hosp Assoc* 1998;34(01):42–54
- Pucheu B, Duhautois B. Surgical treatment of shoulder instability. A retrospective study on 76 cases (1993–2007). *Vet Comp Orthop Traumatol* 2008;21(04):368–374
- Canapp SO Jr, Kirkby K. Disorders of the canine forelimb: veterinary diagnosis and treatment. In: Zink MC, van Dyke JB, eds. *Canine Sports Medicine and Rehabilitation*. Iowa: John Wiley and Sons; 2013:223–249
- Canapp SO Jr, Saunderson DG. Physical rehabilitation of the athletic patient. In: Millis D, Levine D, eds. *Canine Rehabilitation and Physical Therapy*. Philadelphia, PA: Elsevier; 2013:582–594
- Cook JL, Renfro DC, Tomlinson JL, Sorensen JE. Measurement of angles of abduction for diagnosis of shoulder instability in dogs using goniometry and digital image analysis. *Vet Surg* 2005;34(05):463–468
- von Pfeil DJF, Davis MS, Liska WD, George C, Secret S. Orthopedic and ultrasonographic examination findings in 128 shoulders of 64 ultra-endurance Alaskan sled dogs. *Vet Surg* 2021;50(04):794–806
- Devitt CM, Neely MR, Vanvechten BJ. Relationship of physical examination test of shoulder instability to arthroscopic findings in dogs. *Vet Surg* 2007;36(07):661–668

- 12 Jones SC, Howard J, Bertran J, et al. Measurement of shoulder abduction angles in dogs: an ex vivo study of accuracy and repeatability. *Vet Comp Orthop Traumatol* 2019;32(06):427–432
- 13 Livet V, Harel M, Taroni M, et al. Stress radiography for the diagnosis of medial glenohumeral ligament rupture in canine shoulders. *Vet Comp Orthop Traumatol* 2019;32(06):433–439
- 14 O'Donnell EM, Canapp SO Jr, Cook JL, Pike F. Treatment of medial shoulder joint instability in dogs by extracapsular stabilization with a prosthetic ligament: 39 cases (2008–2013). *J Am Vet Med Assoc* 2017;251(09):1042–1052
- 15 Fitch RB, Breshears L, Staatz A, Kudnig S. Clinical evaluation of prosthetic medial glenohumeral ligament repair in the dog (ten cases). *Vet Comp Orthop Traumatol* 2001;14:222–228
- 16 Campbell JR. Shoulder lameness in the dog. *J Small Anim Pract* 1968;9(04):189–198
- 17 Marcellin-Little DJ, Levine D, Canapp SO Jr. The canine shoulder: selected disorders and their management with physical therapy. *Clin Tech Small Anim Pract* 2007;22(04):171–182
- 18 Pettitt RA, Clements DN, Guilliard MJ. Stabilisation of medial shoulder instability by imbrication of the subscapularis muscle tendon of insertion. *J Small Anim Pract* 2007;48(11):626–631
- 19 Franklin SP, Devitt CM, Ogawa J, Ridge P, Cook JL. Outcomes associated with treatments for medial, lateral, and multidirectional shoulder instability in dogs. *Vet Surg* 2013;42(04):361–364
- 20 Penelas A, Gutbrod A, Kühn K, Pozzi A. Feasibility and safety of arthroscopic medial glenohumeral ligament and subscapularis tendon repair with knotless anchors: a cadaveric study in dogs. *Vet Surg* 2018;47(06):817–826
- 21 Penelas A, Pozzi A, Stańczyk E, Gutbrod A. Arthroscopic-assisted stabilization of medial shoulder instability in a Miniature Poodle [in German]. *Schweiz Arch Tierheilkd* 2018;160(09):533–538
- 22 Ringwood PB, Kerwin SC, Hosgood G, Williams J. Medial glenohumeral ligament reconstruction for ex-vivo medial glenohumeral luxation in the dog. *Vet Comp Orthop Traumatol* 2001;14:196–200
- 23 Vasseur PB, Moore D, Brown SA. Stability of the canine shoulder joint: an in vitro analysis. *Am J Vet Res* 1982;43(02):352–355
- 24 Fitzpatrick N, Yeadon R, Smith TJ, et al. Shoulder arthrodesis in 14 dogs. *Vet Surg* 2012;41(06):745–754
- 25 Llido M, Livet V, Carozzo C, Viguier É, Cachon T. Treatment of medial shoulder joint instability by stabilization with an arthroscopically guided prosthetic ligament: a cadaveric feasibility study in dogs. *Vet Comp Orthop Traumatol* 2023;36(01):1–9
- 26 Vasseur PB, Pool RR, Klein K. Effects of tendon transfer on the canine scapulohumeral joint. *Am J Vet Res* 1983;44(05):811–815
- 27 Cook JL, Evans R, Conzemius MG, et al. Proposed definitions and criteria for reporting time frame, outcome, and complications for clinical orthopedic studies in veterinary medicine. *Vet Surg* 2010;39(08):905–908
- 28 Alexander JW. The pathogenesis of canine hip dysplasia. *Vet Clin North Am Small Anim Pract* 1992;22(03):503–511
- 29 Maeda K, Inoue M, Tanaka M, Momozawa Y. Evidence of genetic contribution to patellar luxation in Toy Poodle puppies. *J Vet Med Sci* 2019;81(04):532–537
- 30 Ali MB, Evans JM, Parker HG, et al. Genetic analysis of the modern Australian labradoodle dog breed reveals an excess of the poodle genome. *PLoS Genet* 2020;16(09):e1008956