



Multiple Symptomatic Spinal Intradural Arachnoid Cysts: A Case Report

Vikrant Sharma¹ Suryanarayanan Bhaskar¹ Sarbesh Tiwari²

¹Department of Neurosurgery, All India Institute of Medical Sciences, Jodhpur, Rajasthan, India

²Department of Diagnostic and Interventional Radiology, All India Institute of Medical Sciences, Jodhpur, Rajasthan, India

Address for correspondence Vikrant Sharma, DNB, Senior Resident, Department of Neurosurgery, All India Institute of Medical Sciences, Jodhpur, Rajasthan, 342005, India (e-mail: vikrant_snmc@yahoo.co.in).

Asian J Neurosurg 2023;18:696–697.

Abstract

A spinal arachnoid cyst is a rare entity representing only 1 to 3% of spinal canal lesions. Very few of them are reported to be symptomatic. Moreover, occurrence in multiples is even rarer. Extradural type is more common than intradural. In the spine, it is rare in the sacral region. Other common pathologies, such as a dermoid or epidermoid cyst, are often considered at presentation. Even magnetic resonance imaging can miss the diagnosis sometimes. We report a case with symptoms of paraparesis and incontinence at presentation, initially misdiagnosed as a dermoid cyst, later found to be multiple intradural arachnoid cysts located in the sacral region. Spinal arachnoid cysts may cause debilitating symptoms. The disease is completely curable if the detection and classification are early as in our case.

Keywords

- ▶ arachnoid cyst
- ▶ dermoid
- ▶ intradural
- ▶ multiple
- ▶ spinal

Introduction

Spinal arachnoid cysts are more frequent in the thoracic region, especially the dorsal aspect.¹ Thoracic cysts occur in young adolescents and lumbar and lumbosacral cysts occur in adults.² Multiple cysts occur most frequently in females, especially in the second decade. Intradural variety is rare³ moreover, its multiples are not yet reported to our knowledge.

On Magnetic Resonance Imaging, there is a well-defined interface between the cyst wall and the surrounding dura mater in case of an extra-dural cyst, which is lost in intradural variety.⁴ Identifying communicating dural defect is important preoperatively, which may be difficult even on MRI. Here, Miyamoto et al opined MR myelogram to be a useful technique, but it is not used in many centers across the globe.⁵

Clinical features are sphincter dysfunction, radiculopathy, low back or perineal pain, impotence, and gluteal neuralgia. Laminoplasty, surgical exploration, and total cyst excision and

repair of the dural defect are the treatment of choice for symptomatic and conservative management of asymptomatic cysts.² Other options are cyst resection, incision, drainage, plication, lumbar-peritoneal shunt placement, laminectomy and decompression, and endoscopic closure of the defect.

Case Presentation

A 9-year-old male child presented with gradually progressive bilateral lower limb weakness for 2 months with fecal and urinary incontinence for 1.5 months. No h/o trauma, fever, or weight loss was reported. Exam revealed sensory system intact, tone decreased in bilateral lower limbs and anus, power in bilateral lower limbs—plantar flexion 3/5, dorsiflexion 1/5, Extensor Hallucis Longus (EHL) 0/5, knee joint 4/5, and hip joint 5/5. Deep Tendon Reflexes (DTR) were 2+ in all except bilateral ankle jerks which were 1+, plantars were bilaterally extensor. Noncontrast computed tomography spine suggested extradural

article published online
September 13, 2023

DOI <https://doi.org/10.1055/s-0043-1774376>.
ISSN 2248-9614.

© 2023. Asian Congress of Neurological Surgeons. All rights reserved.

This is an open access article published by Thieme under the terms of the Creative Commons Attribution-NonDerivative-NonCommercial-License, permitting copying and reproduction so long as the original work is given appropriate credit. Contents may not be used for commercial purposes, or adapted, remixed, transformed or built upon. (<https://creativecommons.org/licenses/by-nc-nd/4.0/>)

Thieme Medical and Scientific Publishers Pvt. Ltd., A-12, 2nd Floor, Sector 2, Noida-201301 UP, India

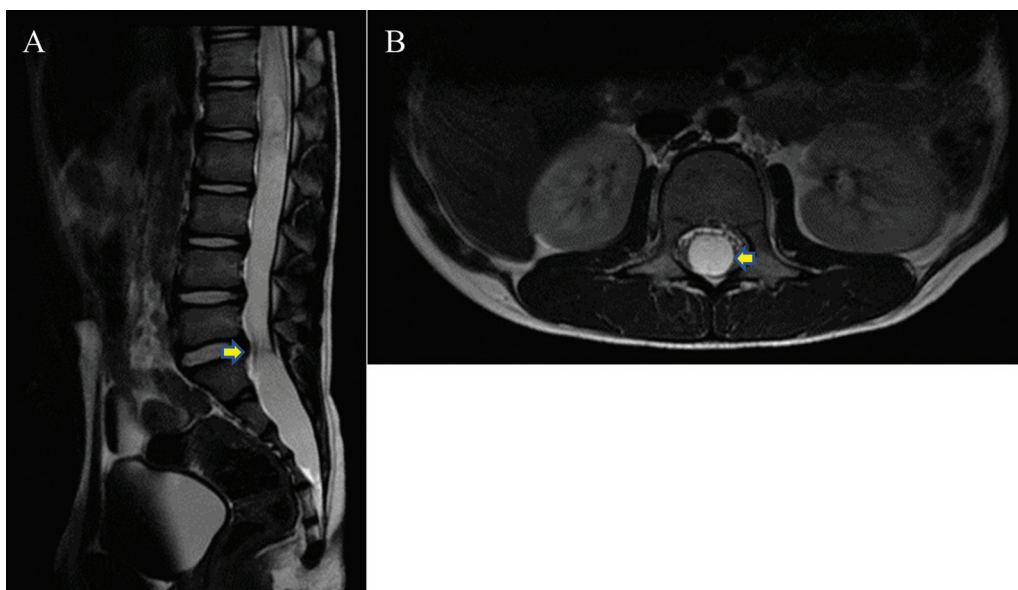


Fig. 1 T2-weighted magnetic resonance imaging (sagittal [A] and axial [B]) showing two intradural spinal arachnoid cysts. The extent is T12-L5 for the first and S1-S5 for the second.

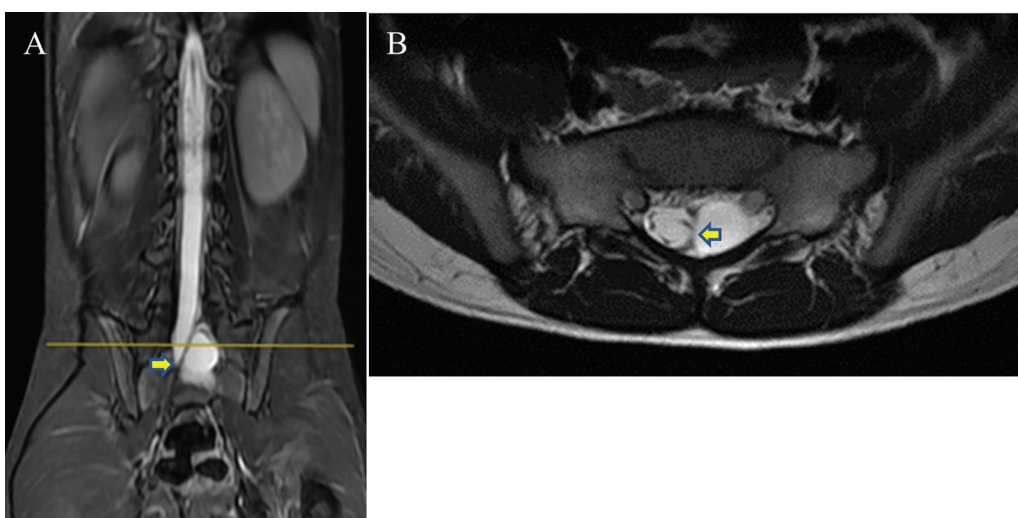


Fig. 2 T2-weighted magnetic resonance imaging of the same patient in coronal (A) and axial (B) views. A clear interface between the two cysts. Note the displacement of the cord by the cyst in coronal view.

arachnoid cyst L5-S4. MRI suggested two intradural cysts—one extending from T12 to L5/S1 level, another from S1-5 displacing nerve roots laterally (► **Fig. 1** and ► **Fig. 2**). L1-5 laminoplasty and surgical excision of the cyst were done, leaving part of the cyst wall stuck to the roots. Part adherent to the filum below was coagulated near the conus and excised along with the cyst. On postoperative day 1 (POD-1), patient regained sphincter function. On POD-3, he was able to walk with minimal support. On subsequent follow-up, he attained full functionality, without signs of recurrence or deformity.

Source(s) of Support
None.

Conflicting Interest
None declared.

References

- 1 Sadek AR, Nader-Sepahi A. Spinal arachnoid cysts: presentation, management and pathophysiology. *Clin Neurol Neurosurg* 2019; 180:87–96
- 2 Bitaraf MA, Zeinalizadeh M, Meybodi AT, Meybodi KT, Habibi Z. Multiple extradural spinal arachnoid cysts: a case report and review of the literature. *Cases J* 2009;2:7531
- 3 Ergun E, Börcek AÖ, Cemil B, Doğulu F, Baykaner MK. Should we operate all extradural spinal arachnoid cysts? Report of a case. *Turk Neurosurg* 2008;18(01):52–55
- 4 Chen HJ, Chen L. Traumatic interdural arachnoid cyst in the upper cervical spine. Case report. *J Neurosurg* 1996;85(02): 351–353
- 5 Miyamoto M, Kim K, Matsumoto R, Isobe M, Isu T. Utility of preoperative magnetic resonance imaging myelography for identifying dural defects in patients with spinal extradural arachnoid cysts: case report. *Neurosurgery* 2006;59(04):E941, discussion E941