

# An Asymptomatic Posttraumatic Intracranial Epidermal Inclusion Cyst: Avoiding the Maslow Hammer

Salman T. Shaikh<sup>1</sup> Manoj Kumar<sup>1</sup> Zairah Shamshad<sup>1</sup> Rahim Hussain<sup>1</sup>

<sup>1</sup>Department of Neurosurgery, University Hospital Coventry & Warwickshire, Coventry, United Kingdom

Asian J Neurosurg 2023;18:692–695.

Address for correspondence Salman T. Shaikh, MCh FRCS Neurosurgery, University Hospital Coventry & Warwickshire, Clifford Bridge Road, Coventry, CV2 2DX, United Kingdom (e-mail: shaikhsalman25@gmail.com).

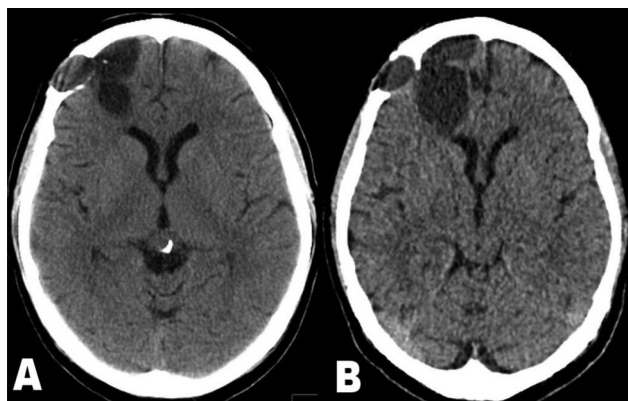
Epidermal inclusion cysts are rare, well-defined, extra-axial benign lesions, with less than 5% showing intra-axial extension.<sup>1</sup> We report a conservatively managed adult with a posttraumatic, asymptomatic, intra-axial plus intradiploic epidermoid cyst.

A 59-year-old man was referred with a history of alcohol withdrawal seizure. Computed tomography (CT) scan showed a right frontal 4 × 3 cm trilobed cystic lesion with bony scalloping without any mass effect at the site of

childhood trauma (►Fig. 1A). Magnetic resonance imaging (MRI) showed a T1-weighted hypointense intra-axial plus extra-axial cystic lesion with homogenous hyperintensity and multilobulated septations on T2-weighted sequence (►Fig. 2). On examination, there was a linear scar in the forehead extending into the hairline with no palpable swelling. He remained asymptomatic till 12 years later when he had another alcohol withdrawal seizure. Repeat imaging showed a 1-cm increase in the size with diffusion restriction, without marked mass effect, representing a chronic post-traumatic epidermal inclusion cyst (►Fig. 3). Imaging after 8 months showed no change (►Fig. 4). On latest follow-up, 53 years after his trauma and 13 years after his radiological diagnosis, he remains clinically well.

A PubMed literature search using MeSH terms “epidermoid cyst,” “trauma,” and “intracranial” with Boolean operator “AND” revealed only nine cases of posttraumatic intracranial epidermoid cysts, which were surgically removed (►Table 1).<sup>2–10</sup> The sine quo non for epidermal inclusion cyst is the presence of marked diffusion restriction. The complications to be aware of are hemorrhage, rupture leading to aseptic meningitis, and rare pathological progression to dermoid cyst or squamous cell carcinoma.<sup>11,12</sup>

Many of the case reports mention complete surgical excision as the goal in symptomatic cases presenting with mass effect. However, a posttraumatic cyst as a consequence of childhood implantation injury can be conservatively managed as long as the patient shows no localizing symptoms and there is no evidence of radiological progression.



**Fig. 1** (A) Plain computed tomography (CT) of the head from 2008 showing a 4 × 3 cm trilobed cystic structure occupying the right frontal lobe with associated frontal bone erosion suggestive of a long-standing pathology. (B) Plain CT of the head from 2020 showing the marginally increased 5.4 × 4.2 cm hypointense cystic lesion suggestive of a benign etiology.

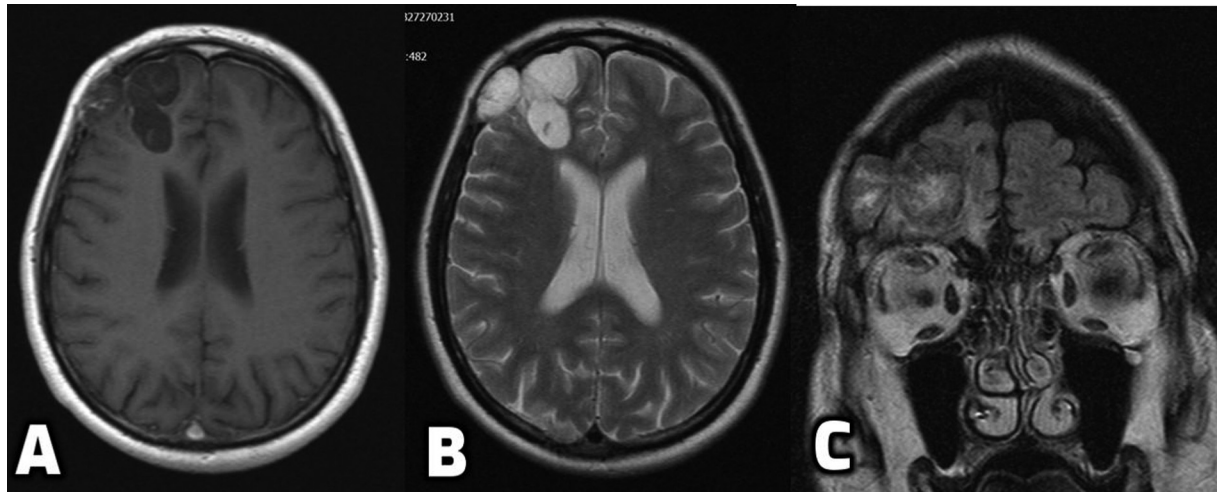
article published online  
September 13, 2023

DOI <https://doi.org/10.1055/s-0043-1774396>.  
ISSN 2248-9614.

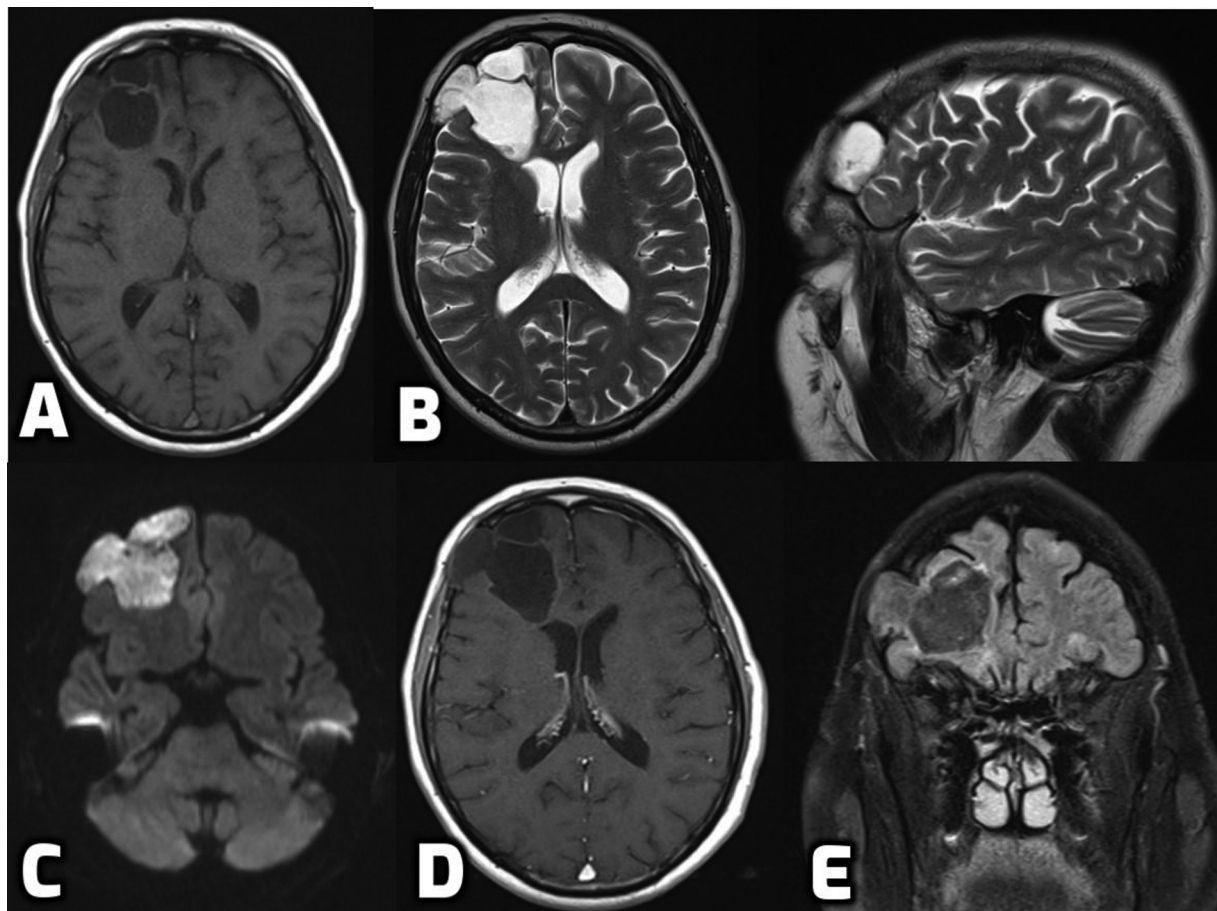
© 2023. Asian Congress of Neurological Surgeons. All rights reserved.

This is an open access article published by Thieme under the terms of the Creative Commons Attribution-NonDerivative-NonCommercial-License, permitting copying and reproduction so long as the original work is given appropriate credit. Contents may not be used for commercial purposes, or adapted, remixed, transformed or built upon. (<https://creativecommons.org/licenses/by-nc-nd/4.0/>)

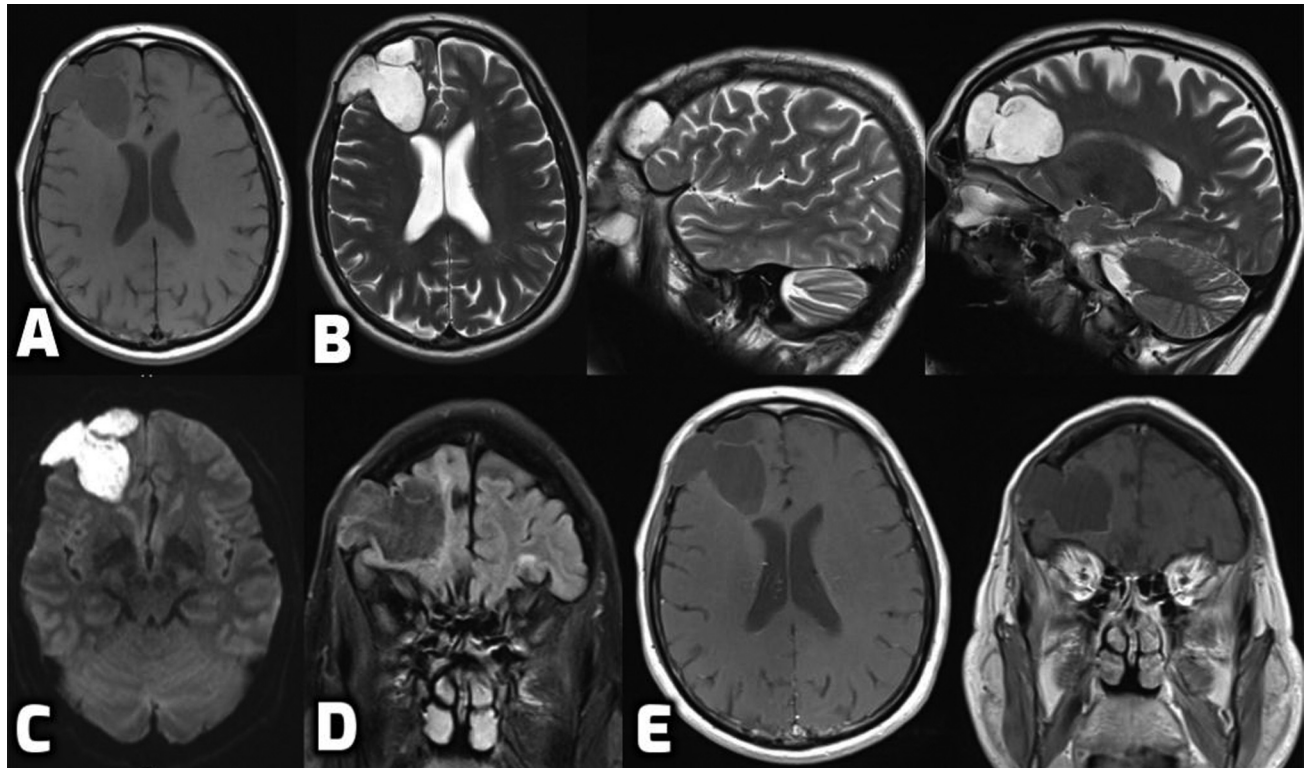
Thieme Medical and Scientific Publishers Pvt. Ltd., A-12, 2nd Floor, Sector 2, Noida-201301 UP, India



**Fig. 2** (A) T1-weighted axial magnetic resonance imaging (MRI) of the brain from 2008 showing the hypointense intra-axial plus extra-axial cystic lesion. (B) T2-weighted axial MRI of the brain from 2008 showing the homogenous hyperintense multilobulated lesion with septations within. (C) Fluid-attenuated inversion recovery (FLAIR) coronal MRI of the brain showing the frontal intradiploic extension of the lesion with no perilesional edema.



**Fig. 3** (A) T1-weighted axial magnetic resonance imaging (MRI) of the brain from 2020 showing the marginally increased hypointense cyst. (B) T2-weighted axial and sagittal MRI of the brain showing the homogenous multiseptated cyst with involvement of the frontal bone. (C) Diffusion-weighted MRI of the brain showing marked restriction within the lesion. (D) T1-weighted postcontrast axial MRI of the brain showing the absence of enhancement within the lesion. (E) Fluid-attenuated inversion recovery (FLAIR) coronal MRI of the brain denoting the intracerebral and extra-axial extension with no perilesional edema.



**Fig. 4** (A) T1-weighted axial magnetic resonance imaging (MRI) of the brain, (B) T2-weighted axial and sagittal, (C) diffusion-weighted image, (D) fluid-attenuated inversion recovery (FLAIR) coronal image, and (E) postcontrast axial and coronal images, from last follow-up showing no change in the characteristics of the lesion.

**Table 1** Cases of posttraumatic intracranial epidermoid cysts in literature

Study	Age at injury (y)	Age at presentation (y)	Symptoms	Location of trauma/cyst	Treatment	Recurrence/complication/follow-up
Fliedner and Hinzpeter <sup>2</sup>	NA	35	Fistula	Temporal injury since childhood trauma	Surgery	Recurrence with raised ICP after 9 y and after 28 y. Death due to pulmonary embolism
Lee et al <sup>3</sup>	13	16	Seizure and headache	Parieto-occipital	Surgery	NA
Karadag et al <sup>4,a</sup>	NA	NA	NA	NA	NA	
Green et al <sup>5</sup>	22	45	Seizure and headache	Parietal	Surgery	Death from unrelated cause in few months
Locatelli et al <sup>6</sup>	15	23	Nonhealing frontal wound	Frontal	Surgery	No recurrence at 18 mo of follow-up
Enchev et al <sup>7</sup>	5	54	Headache, vomiting, and imbalance	Occipital-infratentorial	Surgery	NA
Kalfas et al <sup>8</sup>	34	54	Imbalance, tinnitus	External ear: mastoid and petrous bone	Surgery	No recurrence at 2 mo of follow-up
Samdani et al <sup>9</sup>	NA	24	Frontal swelling and restricted eye movements	Frontal scar since childhood trauma	Surgery	NA
Dupre et al <sup>10</sup>	NA	34	Dizziness and blurred vision	Occipital papule since childhood trauma	Surgery	No recurrence at 4 mo of follow-up
This study	6	59	Alcohol withdrawal seizures	Frontal	Conservative	No complaints at 13 y of follow-up

Abbreviations: ICP, intracranial pressure, y, years;

<sup>a</sup>Full text unavailable.

**Conflict of Interest**

None declared.

**References**

- 1 Osborn AG, Preece MT. Intracranial cysts: radiologic-pathologic correlation and imaging approach. *Radiology* 2006;239(03):650–664
- 2 Fliedner E, Hinzpeter T. An intracranial epidermoid caused by trauma (author's transl). *J Neurol* 1976;211(02):183–188
- 3 Lee VS, Provenzale JM, Fuchs HE, Osumi A, McLendon RE. Post-traumatic epidermoid cyst: CT appearance. *J Comput Assist Tomogr* 1995;19(01):153–155
- 4 Karadag D, Tuba Karagülle A, Erden A, et al. Post-traumatic intradiploic epidermoid cyst. A case report. *J Neurosurg Sci* 2001;45(04):224–227, discussion 227
- 5 Green AJ, Roberts DR, Swanson RA. Post-traumatic epidermoid cyst presenting with headache. *Neurology* 2005;64(09):1657
- 6 Locatelli M, Alimehmeti R, Rampini P, Prada F. Intradiploic frontal epidermoid cyst in a patient with repeated head injuries: is there a causative relationship? *Acta Neurochir (Wien)* 2006;148(10):1107–1110, discussion 1110
- 7 Enchev Y, Kamenov B, William A, Karakostov V. Posttraumatic giant extradural intradiploic epidermoid cysts of posterior cranial fossa : case report and review of the literature. *J Korean Neurosurg Soc* 2011;49(01):53–57
- 8 Kalfas F, Ramanathan D, Mai J, Schwartz S, Sekhar LN. Petrous bone epidermoid cyst caused by penetrating injury to the external ear: case report and review of literature. *Asian J Neurosurg* 2012;7(02):93–97
- 9 Samdani S, Kalra GS, Rawat DS. Posttraumatic intradiploic epidermoid cyst of frontal bone. *J Craniofac Surg* 2013;24(02):e128–e130
- 10 Dupre DA, Pu C, Yu A, Tomycz N. Traumatic intradiploic epidermoid cyst manifest as scalp papule. *BMJ Case Rep* 2015;2015:bcr2014207968
- 11 Pampliega-Pérez A, Martín-Estefanía C, Caballé-Tura M, Portilla-Sogorb J, Alvarez-Saúco M. Aseptic meningitis caused by the rupture of an epidermoid cyst. *Rev Neurol* 2003;37(03):221–224
- 12 Balasundaram P, Garg A, Prabhakar A, Joseph Devarajan LS, Gaikwad SB, Khanna G. Evolution of epidermoid cyst into dermoid cyst: embryological explanation and radiological-pathological correlation. *Neuroradiol J* 2019;32(02):92–97