

Nasopharyngoscopic Study In Velopharyngeal Incompetence

**Dr. Sanjeev N. Deshpande,
M.S., M.Ch. (Plastic)**

KEY WORDS

Velopharyngeal incompetence, pharyngoplasty, Nasopharyngoscopy.

SUMMARY

Superiorly based pharyngeal flap is used in eight patients of cleft palate of Velopharyngeal Incompetence. Hypernasality and nasal escape in use of oral explosives was substantially reduced following surgery. These patients were subjected to flexible Fibreoptic nasopharyngoscopy to study the morphology of the pharyngeal flap and the role it plays in reducing the amount of velopharyngeal incompetence. Movements of the soft palate and the lateral pharyngeal walls decided the outcome of the result of the Superior Pharyngeal flap surgery. Preoperative Nasopharyngoscopy plays a very important role in deciding the type of Pharyngoplasty to be performed.

INTRODUCTION

Velopharyngeal Incompetence is treated by various methods like pharyngoplasty, Speech therapy & Speech Prosthesis. Various Pharyngoplasties have been described (i) Inferiorly based pharyngeal flap (Rosenthal 1924), (ii) Superiorly based pharyngeal flap (Sanvenero Roselli 1935), (iii)

Hynes pharyngoplasty (1950), (iv) Lateral Pharyngeal flaps (Skoog 1965), (v) Sphincter Pharyngoplasty (Orticochea 1968), (vi) Lateral Port control (Hogan 1973). Most of the pharyngoplasties have been described in the era when direct viewing of the velopharyngeal Sphincter was not possible and hence there were no guidelines for selection of the type of the pharyngoplasty.

Velopharyngeal sphincter can be assessed by various methods like (1) Videofluoroscopy, (2) Basal radiography, (3) Air flow studies and more recently by (4) Nasopharyngoscopy (Sinclair S W et al 1982).

Nasopharyngoscopy has become a standard method for the assessment of the Velopharyngeal Sphincter and is well documented by several authors (Pigott R. W. et al 1982, D'Antonio L. et al 1988, Ibuki K. et al 1981, Karnell M. P. et al 1983).

Flexible Fiberoptic Nasopharyngoscopy allows direct transnasal observation of the anatomy and dynamic activity of the Velopharyngeal Sphincter. Use of Nasopharyngoscopy with video-recording has been used recently as a visual feedback therapeutic tool by many authors (Shelton R L et al 1978, Witzel M. A. et al 1988, Yamaoka M et al 1983, Witzel M. A. et al 1989).

MATERIAL AND METHOD

This study was carried out in the Department of Plastic and reconstructive Surgery at Lokmanya Tilak Municipal Medical College and General Hospital, Sion, Bombay.

Eighth patients of operated Cleft palate with Velopharyngeal Incompetence, between 6 years and 20 years of age, of either sex were included in this study. The distribution of age, sex, cleft type and the degree of hypernasality & nasal escape in the speech is given in Table 1.

All the patients were assessed jointly by a Plastic Surgeon and Speech Therapist. All the patients had Velopharyngeal Incompetence of varying degrees.

TABLE - 1

S. N.	Patient	Age	sex	Cleft Type	Nasal Escape	Hypernasality
1.	PN	7 Yrs	F	UCLP	++	++
2.	ND	18 Yrs	F	UCLP	+++	+++
3.	AB	19 Yrs	F	UCLP	+++	+++
4.	MK	20 Yrs	M	BCLP	+++	+++
5.	AC	16 Yrs	M	UCLP	++	++
6.	CT	6 Yrs	M	UCLP	++	++
7.	ND	19 Yrs	F	SCP	++	++
8.	AS	8 Yrs	M	BCLP	+++	+++

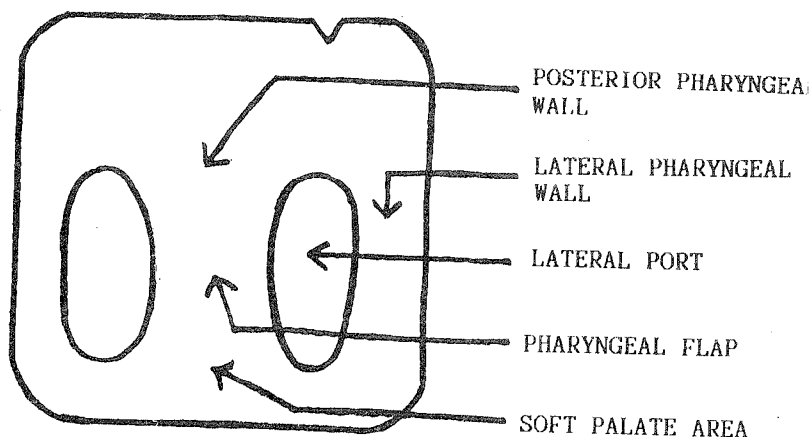
UCLP : Unilateral Cleft Lip & Palate +++ : Severe

BCLP : Bilateral Cleft Lip & Palate ++ : Moderate

SCP : Secondary Cleft Palate.

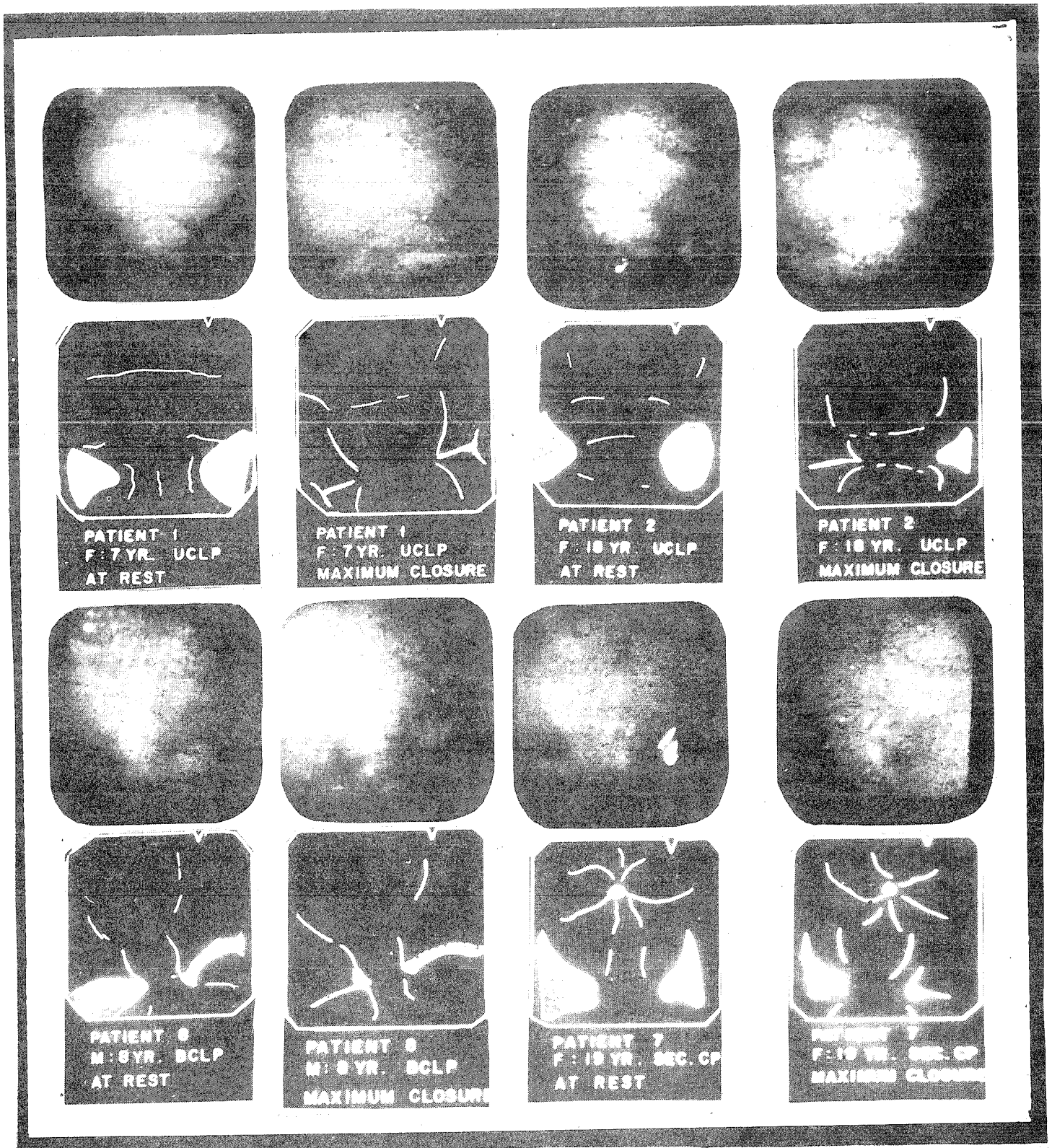
Three to six months after the flap surgery, all the patients were subjected to Nasopharyngoscopy using Flexible Fiberoptic Nasopharyngoscopy of Olympus ENF Type-II. Nasopharyngoscopy was performed under topical anaesthesia (4% Xylocaine) with the patient in sitting posture.

Sketch 1



Sketch Showing Nasopharyngoscopic View of Pharyngeal Flap

PHOTOGRAPHS (1-16)



Figures :

1. (a,b,c,d)
Complete Closure of Velopharyngeal Sphincter
2. (a,b,c,d)
Incomplete Closure of Velopharyngeal Sphincter with Defect Noticed in (R) Lateral Port Area.
3. (a,b,c,d)
Narrow and Short Pharyngeal Flap.
(R) Lateral Port Obliterates at Rest. Complete Closure of Both Ports
4. (a,b,c,d)
Incomplete Closure of Velopharyngeal Sphincter with Small Defect in (R) Lateral Port Area and Large Defect in (L) Lateral Port Area.

The Pharyngeal flap was observed for its location, size and quality. The closing pattern of the Velopharyngeal sphincter was noted. The movements of the soft palate, lateral pharyngeal walls and the posterior wall were noted. Patients were asked to say certain words containing "a", "e", "n", "ng". Efforts were made to achieve maximum closure of the velopharyngeal sphincter by asking the patient to say word "eeh".

OBSERVATIONS AND DISCUSSION

In this study, out of 8 subjects, three were children between 6-8 years of age while five were adults between 16-20 years of age.

geal wall. The pharyngeal flap was placed slightly higher above the contact of soft palate and posterior wall. The pharyngeal flap help the closure of the Velopharyngeal sphincter by reducing the gap between the soft palate and the posterior pharyngeal wall. The narrow size of the flap did not seem to matter in the closure of the velopharyngeal sphincter. In patient 8 also, the pharyngeal flap was very narrow and looked quite short in length causing contact of the soft palate and the posterior pharyngeal wall even at rest with narrow lateral ports. The complete closure of the velopharyngeal sphincter was caused by combined movements of the soft palate and lateral pharyngeal walls achieving cir-

TABLE :

S.N.	Patient	Type of Cleft	Age/Sex	Type of Closure of	Pattern of Closure	Movements of			Flap Size
						Soft Palate	Lateral walls	Post Wall	
1.	PN	UCLP	7 yr.F	Complete	Coronal	+++	+	+	Broad
2.	ND	UCLP	18 yr.F	Incomplete	Circular	++	+	+	Broad
3.	AB	UCLP	19 yr.F	Incomplete	Coronal	++	+	+	Broad
4.	MK	BCLP	20 yr.F	Incomplete	Coronal	++	+	+	Broad
5.	AC	UCLP	16 yr.F	Complete	Circular	++	++	+	Broad
6.	CT	UCLP	6 yr.F	Complete	Coronal	++	+	+	Narrow
7.	ND	SCP	19 yr.F	Complete	Coronal	+	+	+	Broad
8.	AS	BCLP	8 yr.F	Complete	Coronal	++	++	+	Narrow

All the three children had significant improvement in Hypernasality and Nasal escape after Superior Pharyngeal flap surgery. All children showed complete closure as shown. Two children had coronal pattern of closure in which the Soft palate movement dominated while one child had circular or sphincter type of closure with good movements of soft palate and lateral pharyngeal walls.

In patient 1, pharyngeal flap was situated at the site where the soft palate and the posterior pharyngeal wall meet. In this patient there was good movement of the soft palate while lateral wall movements were slight. In patient 6 the pharyngeal flap was quite narrow and looked like a fibrous band anchoring the soft palate to the posterior pharyn-

geal wall. During complete closure of the sphincter the flap looked above the level of the contact of the soft palate and posterior pharyngeal wall.

In adult group, 4 out of 5 patients post pharyngoplasty had significant hypernasality and nasal escape in the speech. Only one patient benefited from the Superior pharyngeal flap surgery. Patient 5 who had complete closure of the velopharyngeal sphincter had a broad and healthy pharyngeal flap. The soft palate and the lateral pharyngeal wall movements were good causing a circular or sphincter type of closure. The pharyngeal flap was situated at a correct level.

Patient 2 had incomplete closure of the velopharyngeal sphincter with lateral port defect on left side. The pharyngeal flap was broad and healthy. The soft palate movement was more on right side

than the left side. The lateral wall movements on both the sides were not adequate enough to cause closure of the sphincter. The closure pattern was more like coronal type.

Patient 3 had incomplete closure of the velopharyngeal sphincter with lateral port defect on left side. The pharyngeal flap was broad and healthy. The soft palate movement was good and equal on both sides.

Lateral wall movement was less on left side as compared to right side. The closure pattern was coronal type.

Patient 7 again had incomplete closure of the velopharyngeal sphincter with large defects noted in both the lateral port areas. The soft palate was rigid and the lateral walls had very minimal movement. The closure pattern would be more like a circular or sphincteric one.

RESULTS

Although there was some degree of improvement in the speech of all the 8 patients. Only 4 patients had dramatic improvement, others continued to have indistinct speech and hypernasality.

All the 3 children showed significant improvement following surgery. Presence of supple soft palate and movements of lateral pharyngeal wall was an important contributory factor in their success.

Those who did not benefit from the pharyngeal flap in fact showed very poor movement of the soft palate and the lateral walls hardly had movement that would help in causing closure of the sphincter. Although flap was broad and attached at the right level to soft palate.

CONCLUSION :

Level at which superiorly based flap is attached to the soft plate, its surviving width after 6 months, movements of soft palate and lateral walls and age, significantly decide the outcome of the procedure. In patients, when it fails to improve hypernasality, sphincter pharyngoplasty as an alternative procedure can be considered to achieve success.

REFERENCES :

1. Alberty E.H., Bennett J.A., Pigott R.W., Simmons R.M. The results of 100 operations for Velopharyngeal Incompetence - selected on the findings of endoscopic on the findings of endoscopic and radiologic examination. Br. J. Plastic Surgery 1982. 35: 118-126.
2. D'Antonio L., Muntz H., Marsh J. et al. Practical application of Flexible Fiberoptic Masopharyngoscopy for evaluating velopharyngeal functions. Plas. Recons. Surg. 1988. 82: 611-618.
3. Ibuki K., Karnell M.P., Morris H.L. Reliability of Nasopharyngeal Fibrescope for assessing Velopharyngeal function. Cleft Palate J. 1983. 20: 199-208.
4. Karnell M.P., Ibuki K., Morris H.L., Van Demark D.R. Reliability of the nasopharyngeal Fibrescope for assessing Velopharyngeal function : analysis by judgement. Cleft Palate J. 1983. 20: 199-208.
5. Jackson I.T., Silverton J.S. The Sphincter Pharyngoplasty as a secondary procedure in Cleft Palates. Plas. Recons. Surg. 1977. 59(4) : 518-524.
6. Orticochea M. A review of 236 Cleft palate patients treated with Dynamic Muscle sphincter. Plas. Recons. Surg. 1983, 71(2): 180-188.
7. Pigott R.W., Makepeace A.P. Some characteristics of endoscopic and radiological systems used in elaboration of the diagnosis of Velopharyngeal Incompetence. Br. J. Plas. Surg. 1982. 35 : 19-32.
8. Shelton R.L., Beaumont K., Trier W.C., Furr M.L. Videendoscopic feedback in training Velopharyngeal closure. Cleft Palate J. 1978. 15: 6-12.
9. Shprintzen R.J., Lewin M.L., Croft C.B., Daniller A.I., Argamaso R.V., Ship A.G., Strauch B. A Comprehensive study of Pharyngeal flap surgery: Tailor made flap Cleft palate J. 1979. 16: 46-55.
10. Sinclair S.W., Davies D.M., Bracka A. Comparative reliability of Nasal Pharyngoscopy and Videofluoroscopy in the assessment of Velopharyngeal Incompetence. Br. J. Plas. Surg. 1982. 35: 113-117.
11. Witzel M.A., Tobe J., Salyer K.E. The use of Nasopharyngoscopy biofeedback therapy in the correction of inconsistent velopharyngeal closure. Int. J. Paediat. Otorhinolaryngol 1988, 15:137-142.
12. Witzel M.A., Tobe J., Salyer K.E. The use of Videonasopharyngoscopy for biofeedback therapy in adults after pharyngeal flap surgery. Cleft Palate J. 1989. 26 : 122-127.
13. Yamaoka M., Matsuya T., Miyazaki T., Nishio J., Ibuki K. Visual training for Velopharyngeal closure in Cleft Palate patients: a fiberoptic procedure: a preliminary report. J. Maxillofac. Surg. 1983. 11: 191-193.

AUTHOR'S NAME AND ADDRESS:

Dr. Sanjeev N. Deshpande, M.S.,
M.Ch. (Plastic),

#2, Unique Apartments, Irla,
Swami-Vivekanand Road,
Vile Parle (W), Bombay - 400 056.