Article published online: 2023-10-19



# Successful Treatment of Refractory Inspissated Bile Syndrome Using Gastrografin

Justin J. Guan[1] Mohammad A. Amarneh[2]

[1] Department of Radiology, Division of Interventional Radiology, Cleveland Clinic, Moreland Hills, Ohio, United States
[2] Department of Radiology, Division of Interventional Radiology, University of Iowa Hospitals and Clinics, Iowa City, Iowa, United States

**Address for correspondence** Justin J. Guan, MD, Department of Radiology, Division of Interventional Radiology, Cleveland Clinic, Moreland Hills, OH 44022, United States (e-mail: guanj@ccf.org).

J Clin Interv Radiol ISVIR 2024;8:56–59.

## Abstract

Inspissated bile syndrome (IBS) is a rare cause of obstructive jaundice in infants. Despite drainage and irrigation, obstruction may persist in some cases with limited further options. This report presents a case of persistent IBS in a 5-month-old female with worsening liver failure despite cholecystostomy and saline irrigation, and a last-ditch effort was made to irrigate with Gastrografin. Patient's bilirubin decreased from 15.5 to 8.3 mg/dL after 1 day. Her bilirubin and liver functions tests normalized by 2 weeks. Gastrografin's hyperosmolarity promotes intraluminal fluid shift and stimulates smooth muscle contraction, which may explain its effectiveness in treating refractory IBS.

**Keywords**
- inspissated bile syndrome
- IBS
- Gastrografin

## Introduction

Inspissated bile syndrome (IBS) is a rare cause of obstructive jaundice in infants that can lead to fulminant liver failure.[1] Standard treatment includes ursodiol followed by saline irrigation after cholecystostomy or transhepatic biliary drainage, but obstruction may persist in some cases with limited further options.[1–4] We present a case of persistent IBS with worsening liver failure despite cholecystostomy and saline irrigation, resolving only after irrigation using Gastrografin, a hyperosmolar contrast agent.

## Case Presentation

This case was exempted from Institutional Review Board approval as a case report. A 5-month-old female born at 37-week gestation with double-inlet left ventricle status-post multiple repairs was found to have rising liver enzymes and direct hyperbilirubinemia (T. bilirubin 9.4) despite ursodiol for 11 days. Ultrasound demonstrated extensive biliary sludge with bile duct dilation and gallbladder distension, consistent with IBS (►**Fig. 1**). Interventional radiology was consulted for cholecystostomy placement.

A 6-French cholecystostomy tube was placed under ultrasound and fluoroscopic guidance (►**Fig. 2**). Despite saline irrigation at 5 mL three times daily, subsequent upsizing to 8-French tube 3 days later with advancement of drain into duodenum to create a cholecystoduodenostomy, and increased irrigation rate to 10 mL every 3 hours, patient's bilirubin continued to rise to 15.5 mg/dL by 8 days after cholecystostomy (►**Figs. 3**, **4**). Due to liver failure, international normalized ratio increased to 5.5. At this point, patient also experienced status epilepticus, and head computed tomography (CT) showed worsening bilateral subdural hematomas.

**article published online**
October 19, 2023

**DOI** https://doi.org/10.1055/s-0043-1774721.
**ISSN** 2457-0214.


Thieme Medical and Scientific Publishers Pvt. Ltd., A-12, 2nd Floor, Sector 2, Noida-201301 UP, India

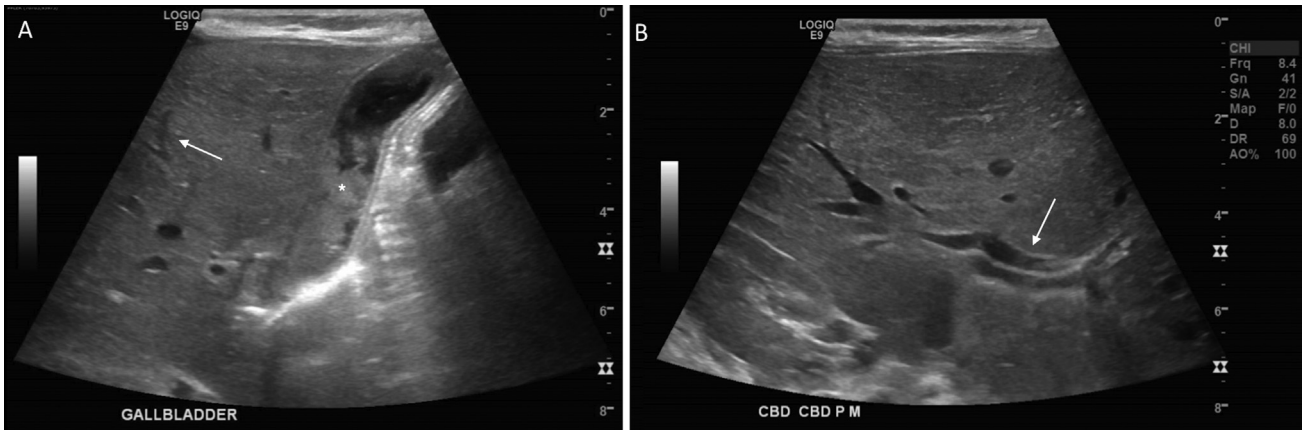


**Fig. 1** Initial right upper quadrant ultrasound showing distended gallbladder with biliary sludge(*) (**A**) and dilated intra- (arrow) and extrahepatic (arrow) bile ducts (**B**). CBD, common bile duct.

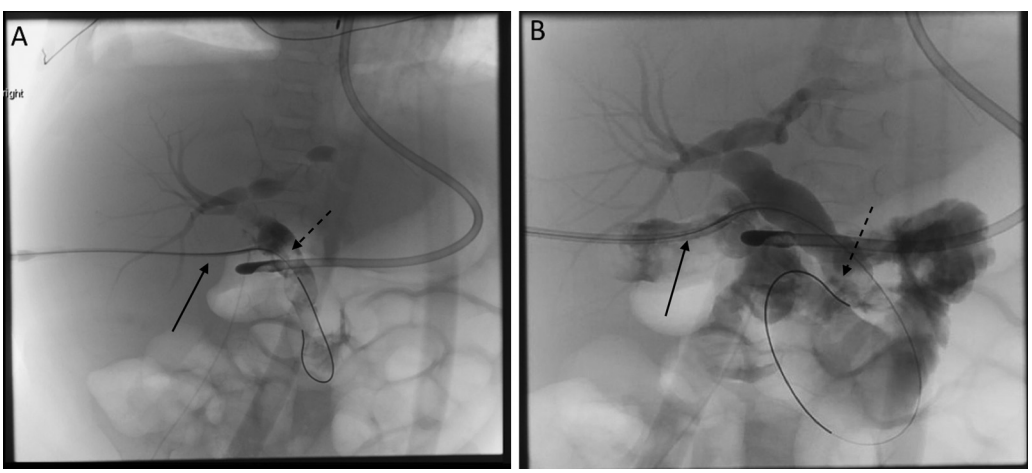


**Fig. 2** Cholecystostomy tube placement. Under ultrasound guidance, a 22-G micropuncture needle was used to cannulate the gallbladder, followed by advanced of a guidewire (arrow) under fluoroscopy (**A, B**). Initial cholecystogram showed extensive filling defects/debris (dotted arrow) within the gallbladder and common bile duct, likely biliary sludge (A, B). The soft tissue tract was dilated and a 6-French locking pigtail catheter (arrow) was placed within the gallbladder lumen, confirmed on post-procedural cholecystogram (**C**).

**Fig. 3** Due to continued rise in bilirubin, cholecystostomy tube was subsequently upsized and advanced into duodenum (arrow) for internalization. Irrigation frequency was also increased to 10 mL normal saline every 3 hours.

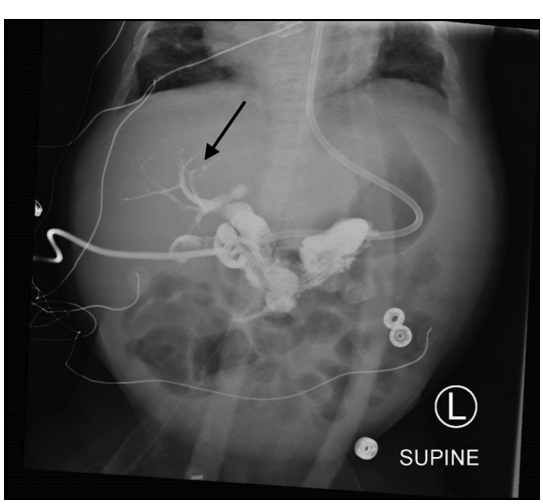


**Fig. 4** Gastrografin injection was attempted due to continued rise in bilirubin. Post-injection radiograph showed contrast filling the dilated intra- and extrahepatic biliary system (arrow).

 

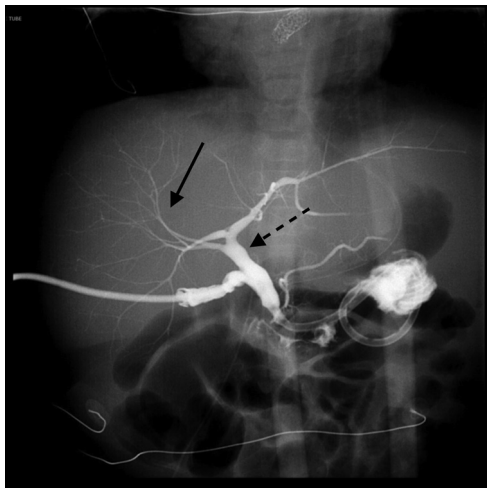

**Fig. 5** Drain check 3 days after first Gastrografin injection (1 day after second injection) shows resolution of intrahepatic bile duct dilation (arrow) and decreased caliber of common bile duct (dotted arrow).

Decision was made to attempt irrigation using the hyperosmolar contrast agent Gastrografin. This was done by injection 6 cc of Gastrografin diluted 1/3 with normal saline, followed by a 5 cc normal saline flush. One day after irrigation, patient's bilirubin decreased to 8.3 mg/dL with concurrent reduction in aspartate aminotransferase/alanine transaminase (AST/ALT). Gastrografin irrigation was repeated 2 days later, and bilirubin further decreased to 3.8 mg/dL the next day. Cholangiogram showed resolution of bile duct dilation with free flow of contrast into duodenum (►**Fig. 5**). At 2 weeks, bilirubin had decreased to 1.3 mg/dL, and the tube was capped (►**Fig. 6**). At 1 month after cholecystostomy, patient's bilirubin and AST/ALT normalized. The tube was downsized to 6-French, externalized to the gallbladder, and it was removed 4 days later. Patient had no further seizure activity and head CT at 2 months showed significant interval reduction of bilateral subdural hematomas. At 3.5 months after cholecystostomy, patient's liver enzymes remained normal and she continues to do well.

## Discussion

IBS is characterized by obstruction of the common bile duct by biliary sludge in infants who otherwise have no anatomical abnormalities or congenital chemical bile defects.[1,3] Though no predisposing causes are found in many cases, some can occur secondary to infection, hepatocellular damage, cystic fibrosis, or hemolytic disorders.[4]

In the past, IBS not resolving spontaneously or with ursodiol had been managed surgically with laparotomy and operative cholangiography and/or intraoperative irrigation of the biliary system with saline or N-acetylcysteine, a commonly-used mucolytic agent.[1–4] With the advent and improvement in percutaneous techniques in recent years, transhepatic biliary or cholecystostomy drain placement followed by saline irrigation has become the standard of care.[1,3]

But despite drainage and irrigation, biliary obstruction may persist in some cases; in such refractory IBS, further management options are extremely limited, and ongoing hepatic failure can be life-threatening.[1,3,4] Similar to previously-reported intraoperative injection of mucolytic agents, Berrani et al reported a case of refractory IBS successfully

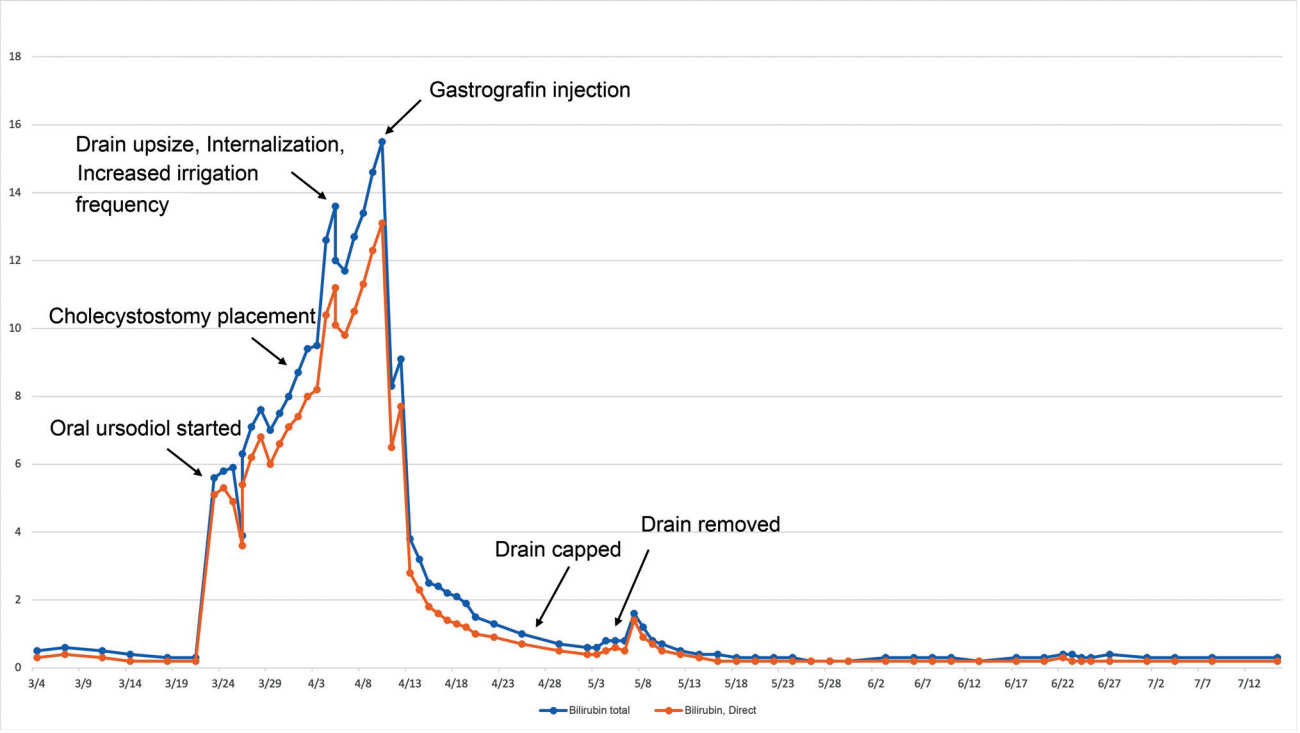


**Fig. 6** Trend of total and direct bilirubin over time.

 

treated after percutaneous cholecystostomy with injection of N-acetylcysteine and glucagon, which physiologically relaxes the sphincter of Oddi.[3] More recently, Jun et al reported the use of omega-3 polyunsaturated fatty acids (PUFAs) in treating persistent IBS.[4] By affecting bile acid and lipid metabolism, it is thought that omega-3 PUFAs can act as a choleretic agent.

To the authors' knowledge, the current report is the first published case of using Gastrografin to treat refractory IBS. Gastrografin is a water-soluble contrast agent with osmolarity of 1900 mOsml/L, approximately six times the serum osmolarity. It is commonly used for the management of distal intestinal obstruction syndrome in cystic fibrosis patients and in cases of adhesive small bowel obstruction.[5] Its hyperosmolar nature promotes intraluminal fluid shift in the gastrointestinal tract through osmosis and it is known to stimulate smooth muscle contraction. Both mechanisms may explain its success in treating refractory IBS.

## Conclusion

This case suggests that biliary irrigation using a hyperosmolar agent such as Gastrografin can be an effective treatment option for refractory IBS after ursodiol and percutaneous biliary drainage with saline irrigation. More research aimed at understanding the exact mechanisms of action of hyperosmolar contrast agents, specifically Gastrografin, in the context of the biliary system is warranted to better elucidate the therapeutic value of such agents in refractory IBS.

**Conflicts of Interest**
None declared.

## References

1 Bollu BK, Dawrant MJ, Thacker K, et al. Inspissated bile syndrome; safe and effective minimally invasive treatment with percutaneous cholecystostomy in neonates and infants. J Pediatr Surg 2016; 51(12):2119–2122
2 Berger S, Schibli S, Stranzinger E, Cholewa D. One-stage laparoscopic surgery for inspissated bile syndrome: case report and review of surgical techniques. Springerplus 2013;2:648
3 Berrani H, Vasies I, Cron J, Bachy B, Le Dosseur P, Mouterde O. Association of N-acetylcysteine and glucagon during percutaneous cholangiography in the treatment of inspissated bile syndrome. Arch Pediatr 2015;22(03):300–302
4 Jun WY, Cho MJ, Han HS, Bae SH. Use of Omega-3 polyunsaturated fatty acids to treat inspissated bile syndrome: a case report. Pediatr Gastroenterol Hepatol Nutr 2016;19(04):286–290
5 Ekladious A, Wheeler LP, Yamanaka M. Gastrografin: a diagnostic and therapeutic agent. Intern Med J 2018;48(12):1547–1549

 