



# Long-term Changes of Infrared Thermography in Successful Decompression of Carpal Tunnel Syndrome: a Case Report

## *Alterações a longo prazo da termografia infravermelha na descompressão bem-sucedida da Síndrome do Túnel do Carpo: relato de caso*

Matheus Henrique Oliveira Ferreira<sup>1</sup> Pedro Neves Borges<sup>1</sup> Paulo Roberto Bastos Fontinha<sup>1</sup>  
 Marcus André Acioly<sup>1,2</sup>

<sup>1</sup> Division of Neurosurgery, Fluminense Federal University (UFF), Niterói, Rio de Janeiro, Brazil

<sup>2</sup> Division of Neurosurgery, Federal University of Rio de Janeiro (UFRJ), Rio de Janeiro, Brazil

**Address for correspondence** Marcus André Acioly, MD, PhD, Division of Neurosurgery, Fluminense Federal University, Niterói, Rio de Janeiro, Brazil (e-mail: marcusacioly@yahoo.com.br).

Arq Bras Neurocir

### Abstract

**Introduction** Infrared thermography (IRT) has demonstrated high diagnostic accuracy for carpal tunnel syndrome (CTS) diagnosis in previous studies. However, the recovery of the autonomic function after treatment for CTS is rarely addressed in the literature, especially on the long-term.

**Case Presentation** A 59-year-old lady sought treatment for a long-term history of numbness, tingling, and hand and arm pain. CTS was diagnosed by clinical and electrophysiological means. After 6 months of conservative treatment, surgical treatment was offered. Preoperative IRT was performed by static and dynamic evaluations immediately and 5 minutes after the cold challenge test using the FLIR C2 camera with accuracy of 2°C or 2%. Fingers were consistently colder (mean of 3.76°C), which clearly represented an autonomic dysfunction in the patient's hand. The patient underwent mini-open carpal tunnel decompression and did great postoperatively. One year after surgery, the patient was fully recovered and completely asymptomatic. IRT imaging showed a remarkable improvement of fingers temperature (mean of 3.36°C).

**Conclusions** Our long-term results confirmed that functional recovery occurred concomitantly to autonomic recovery, which was demonstrated by consistent improvement in fingers' temperature. IRT has a strong potential at the evaluation of patients with CTS for both diagnosis and follow-up.

### Keywords

- carpal tunnel syndrome
- infrared thermography
- peripheral nerve
- cold challenge test

received  
February 20, 2023  
accepted  
July 5, 2023

DOI <https://doi.org/10.1055/s-0043-1774751>.  
ISSN 0103-5355.

© 2023. Sociedade Brasileira de Neurocirurgia. All rights reserved. This is an open access article published by Thieme under the terms of the Creative Commons Attribution-NonDerivative-NonCommercial-License, permitting copying and reproduction so long as the original work is given appropriate credit. Contents may not be used for commercial purposes, or adapted, remixed, transformed or built upon. (<https://creativecommons.org/licenses/by-nc-nd/4.0/>)

Thieme Revinter Publicações Ltda., Rua do Matoso 170, Rio de Janeiro, RJ, CEP 20270-135, Brazil

## Introduction

Carpal tunnel syndrome (CTS) is considered the most frequent nerve entrapment syndrome of the upper limb.<sup>1</sup> The combination of a clinically compatible history together with abnormal electrophysiological findings are generally considered for the diagnosis of CTS.<sup>1</sup> Conventional neurological examination includes testing of motor and sensory functions, as well as provocative tests.<sup>1</sup> Generally, median nerve sympathetic function is overlooked.<sup>2–4</sup> Such autonomic component controls peripheral vasomotor activity and, ultimately, regional temperature, which can be assessed by infrared thermography (IRT) as a result of peripheral nerve lesion.<sup>2–4</sup>

IRT has demonstrated high diagnostic accuracy for CTS diagnosis in previous studies.<sup>2–4</sup> However, the recovery of the autonomic function after treatment for CTS is rarely addressed in the literature,<sup>2</sup> especially on the long-term. Herein, we present a typical patient affected by CTS who underwent surgery and improved clinically. Such clinical improvement occurred concurrently to autonomic function improvement, which was represented by a temperature recovery in median nerve distribution area one year after surgery.

## Case Report

### History, Clinical Findings, and Diagnostic Assessment

A 59-year-old lady experienced bilateral paresthesias, tingling, numbness, and pain in median nerve territory for five years. Symptoms were worse on the right hand and at night, which sometimes forced her awakening. Neurological examination revealed hand weakness (Grade 4/5) without thenar wasting, decreased sensation at the radial fingers, and positive provocative testing (Tinel, Phalen, and Durkan signs). Cervical imaging showed degenerative findings. CTS diagnosis was confirmed by electrophysiological examination. The patient was referred for surgical consultation after six months of conservative treatment (physical therapy, medication, and splinting).

### Therapeutic Intervention, Follow up-and Outcomes

Bilateral staged carpal tunnel release was planned, in the way that the right hand was operated on first. Before proceeding with surgery in the left hand, the patient was examined with IRT with the following protocol: after acclimatization in a special room with stabilized temperature, thermal images were carried on a FLIR C2 camera (FLIR Systems, OR USA) with 2°C or 2% accuracy, and positioned ~50cm from the

hand. The regions of interest (ROIs) were the thenar region of the affected hand (Sp1), and the distal phalanx of the thumb (Sp2), forefinger (Sp3) and middle finger (Sp4). Temperature gradients ( $\Delta T$ ) were defined as the difference between the ROIs of the thenar region and the fingers (TSp1-TSpi). The cold challenge test (CCT) was used to provoke sympathetic sensitization, as previously described.<sup>5</sup> In short, the patient had her right lower limb immersed in a thermal container with cold water (between 11°C and 15°C for 5 minute). Thermal images of the left hand were obtained after acclimatization, immediately after CCT, and 5 minutes after CCT.

At baseline, fingers were consistently colder (mean  $\Delta T$  of 3.76°C). CCT generally increased such a gradient, which clearly represented an autonomic dysfunction in the patient's hand. The patient was then submitted to mini-open carpal tunnel release three months after the first surgery in an outpatient setting with mild sedation and local anesthesia. She made an uneventful recovery. After one year, the patient was asymptomatic with complete resolution of symptoms on the operative side. Thermal images were obtained on the long-term, thereby demonstrating clear improvement in temperature gradients from median nerve distribution area at baseline and after CCT evaluations. Thermal images and temperature parameters of the operated hand obtained before and after surgery are demonstrated on ►Table 1 and ►Fig. 1. The patient gave informed consent for the publication of this manuscript.

## Interpretation

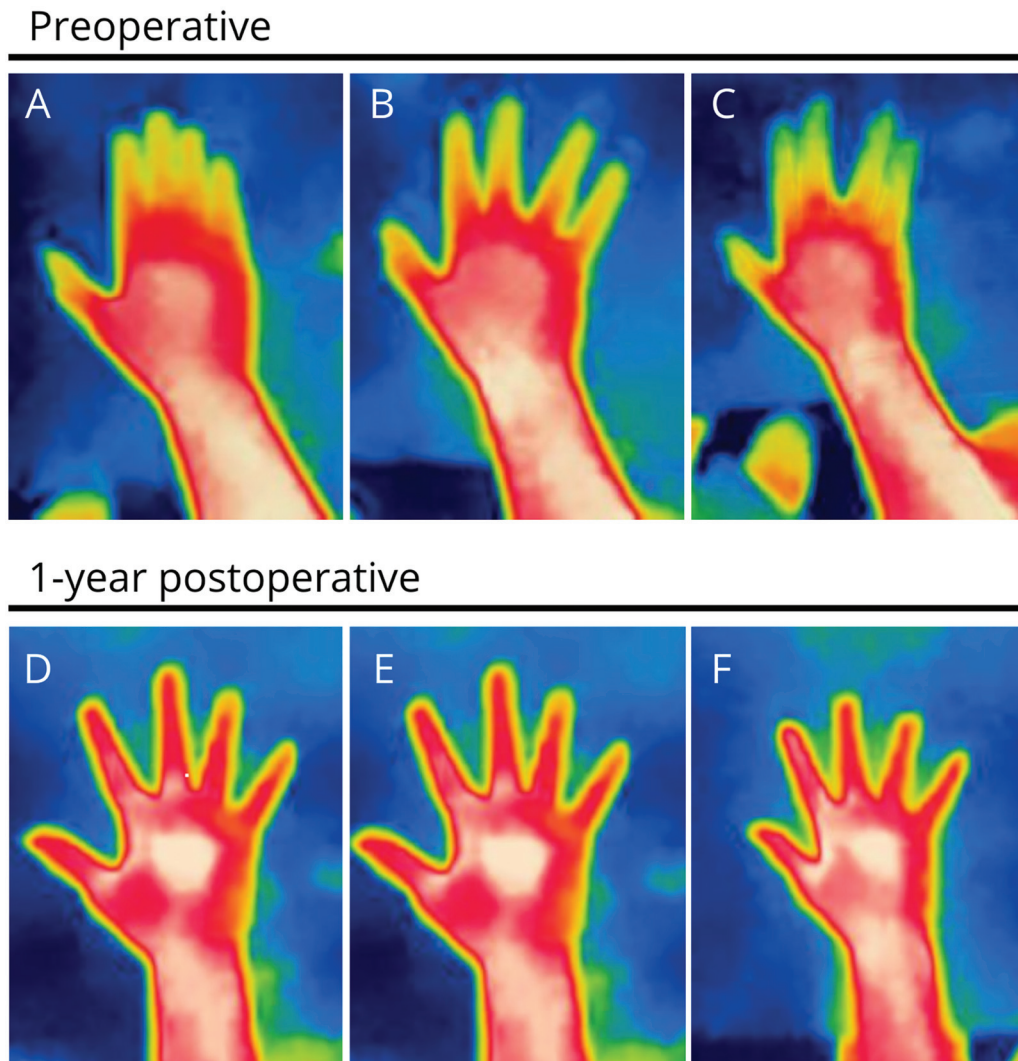
The assumption behind using IRT for an entrapment neuropathy consists in assigning the obtained thermographic responses to dysfunction of the autonomic nervous system. From the physiological standpoint, sympathetic nerves exist on the outer layer of the median nerve and are prone to compression injuries.<sup>3</sup> These fibers can be especially vulnerable in entrapment neuropathies because they are thin and unmyelinated.<sup>4</sup> Also, since the heat of the muscle or bone do not affect dermal tissue because of the dermal depth in most of the body, thermographic skin changes are presumed to occur as a result of the neurological status. Of note is that fingers are generally colder (mean of 0.3°C) than the thenar region and the shoulder in normal controls.<sup>2,3</sup>

The classical thermogram of a patient affected by CTS is a decreased area of vascular heating emission in median nerve territory.<sup>3</sup> In contrast, patients with severe or complete nerve injury generally demonstrate increased finger temperature.<sup>3</sup> The accuracy of IRT as a diagnostic method has been

**Table 1** Temperature gradients of the left hand obtained before and one year after surgery

	$\Delta T2$ (°C)		$\Delta T3$ (°C)		$\Delta T4$ (°C)	
	Preop	Postop	Preop	Postop	Preop	Postop
Baseline	4.5	0	3.2	-0.1	3.6	1.3
Immediately after CCT	3.1	0.1	4	0.1	4.8	0.4
5-minute recovery after CCT	3.7	0.6	4.9	0	5	1.6

Abbreviations: CCT, cold challenge test; ( $\Delta Ti$ ) is defined as TSp1, TSpi (°C); Preop, preoperative; Postop, postoperative.



**Fig. 1** Thermal images of the left hand obtained at baseline (A, D), immediately after the cold challenge test (B, E), and 5 minute after recovery (C, F) showing consistent improvement in fingers' temperature at the long-term (one year after surgery).

considered to be high, especially for patients with abnormal electrophysiological findings.<sup>3,4</sup> Major advantages of using IRT for CTS diagnosis are its non-invasiveness, it is less expensive than electrophysiological examination, and it can be used for screening, particularly in subclinical cases.<sup>3</sup>

IRT evaluations after carpal tunnel release are scarce in the literature. Baic et al. (X) studied 15 patients suffering from CTS and a control group. Thermographic examinations were performed before and 4 weeks after surgery. Baseline images demonstrated colder fingers (mean of 4.9°C), in comparison to thenar regions. Patients consistently recovered their hand temperatures after surgery (mean improvement of 4.5°C). At the end of their study, such temperatures were very similar to those observed in normal controls. Interestingly, the thumb presented a faster recovery in their evaluation.<sup>2</sup> This is not completely understood, since the authors suggested that the size of thenar musculature could have some impact in such recovery. Possibly, this is due to the position of the thumb, which is rather proximal than other fingers. Clinical outcomes were not cited, however.

Our thermographic results at baseline were in line with previous studies thereby suggesting the role of IRT in CTS diagnosis. Additionally, our long-term results confirmed that functional recovery occurred concomitantly to autonomic recovery. Interestingly, we have also observed that thumb thermal map presented the highest temperature improvement. CCT was found very useful to exacerbate autonomic dysfunction both before and after surgery. We are currently performing a study at our facility to confirm the findings we have demonstrated in this anecdotal case report.

In conclusion, we have evaluated the long-term changes of IRT in successful decompression of CTS demonstrating a consistent improvement in fingers' temperature, which might correlate to autonomic recovery. IRT has a strong potential at the evaluation of patients with CTS for both diagnosis and follow-up. However, more research is necessary to clarify the real usefulness of this technique.

#### Authors Contribution

All authors contributed to the study conception and design. Material preparation, data collection and analysis

were performed by [Matheus Henrique Oliveira Ferreira], [Pedro Neves Borges] and [Paulo Roberto Bastos Fontinha]. The first draft of the manuscript was written by [Marcus André Acioly] and all authors commented on previous versions of the manuscript. All authors read and approved the final manuscript.

#### Conflict of Interest

None.

#### References

- 1 Wainner RS, Fritz JM, Irrgang JJ, Delitto A, Allison S, Boninger ML. Development of a clinical prediction rule for the diagnosis of carpal tunnel syndrome. *Arch Phys Med Rehabil* 2005;86(04): 609–618
- 2 Baic A, Kasprzyk T, Rżany M, et al. Can we use thermal imaging to evaluate the effects of carpal tunnel syndrome surgical decompression? *Medicine (Baltimore)* 2017;96(39):e7982
- 3 Herrick RT, Herrick SK. Thermography in the detection of carpal tunnel syndrome and other compressive neuropathies. *J Hand Surg Am* 1987;12(5 Pt 2):943–949
- 4 Ming Z, Zaproudina N, Siivola J, Nousiainen U, Pietikainen S. Sympathetic pathology evidenced by hand thermal anomalies in carpal tunnel syndrome. *Pathophysiology* 2005;12(02): 137–141
- 5 Bruehl S, Lubenow TR, Nath H, Ivankovich O. Validation of thermography in the diagnosis of reflex sympathetic dystrophy. *Clin J Pain* 1996;12(04):316–325