



Venous Hemorrhagic Infarct Leading to Delayed Brain Abscess Formation: A Case Report

Anshu Warade¹ Alay V. Khandhar¹ Charulata Sankhla² Ketan I. Desai¹

¹Department of Neurosurgery and Gamma Knife Radiosurgery, P. D. Hinduja National Hospital and Research Center, Mumbai, India

²Department of Neurology, P. D. Hinduja National Hospital and Research Center, Mumbai, India

Address for correspondence Anshu Warade, DNB (Neurosurgery), Department of Neurosurgery & Gamma Knife Radiosurgery, P.D. Hinduja National Hospital and Research Center, Mumbai 400016, India (e-mail: dranshuwarade@gmail.com).

Indian J Neurosurg

Abstract

Keywords

- ▶ cerebral venous thrombosis
- ▶ infarct
- ▶ abscess

Venous sinus thrombosis is a common neurovascular problem with multifactorial etiology, infection being one of the common causes. Cerebral abscess causing thrombophlebitis and venous sinus occlusion is a known entity. In contrast, venous hemorrhagic infarct leading to abscess formation is extremely uncommon. We report a rare case of such delayed abscess formation in a venous hemorrhagic infarct secondary to superior sagittal sinus occlusion.

A 52-year-old man arrived in the emergency room with repeated episodes of generalized tonic-clonic seizures, right hemiparesis of power grade 1 on the Medical Research Council (MRC) scale and pure motor aphasia (Broca's aphasia). An urgent computed tomography (CT) scan of the brain revealed a large patchy area of hemorrhage in the left frontoparietal region of the brain. Magnetic resonance imaging (MRI) scan along with magnetic resonance venography (MRV) of the brain (▶**Fig. 1A**) confirmed hemorrhagic venous infarct in the left frontoparietal region of the brain secondary to occlusion of the anterior one-third superior sagittal sinus (SSS) and the anterior portion of the middle one-third SSS (▶**Fig. 1B**). He was treated with low-molecular-weight heparin, antiedema measures, and antiepileptics medications, and was discharged on oral warfarin. At discharge, his motor aphasia had improved and could verbalize monosyllabic words with the right hemiparesis of power grade 3 on the MRC scale.

A month later, he came to the emergency department with altered sensorium and right hemiplegia. CT scan of the brain (▶**Fig. 1C**) showed complete resolution of the hemorrhage with severe white matter edema in the left frontoparietal region of the brain. There was mass effect with a midline shift to the right of 16 mm. He was treated with antiedema measures. Over the period of 1-month, he became alert and had right hemiparesis of MRC power grade 3.

He presented again 4 months later with multiple episodes of right-sided focal seizures with hemiplegia. There was a history of high-grade fever for the last 1 week. MRI of the brain demonstrated two contiguous ring-enhancing lesions in the same area of previous bleed revealing diffusion restriction suggestive of abscess (▶**Fig. 1D, E**). A thorough checkup was done including 2D echocardiography, CT scan of the chest, ultrasonography of the abdomen, and blood cultures. All these investigations failed to demonstrate any septic focus elsewhere in the body. Dental and ENT (ear, nose, and throat) examination revealed no abnormality. He was operated on and a craniotomy drainage of the left frontoparietal abscess was performed. After draining the pus, the thick fibrous capsule was also radically excised (▶**Fig. 1F**). The pus culture failed to demonstrate any growth of organisms. Histopathological examination (▶**Fig. 1G, H**) revealed foamy macrophages, multinucleated giant cells, and fibrous scarring suggestive of chronic abscess. At discharge, the patient was ambulatory without support with right hemiparesis of MRC power grade 3. A 6-week course of antibiotics—linezolid and ceftriaxone—were given. At 6 weeks of follow-up, his hemiparesis had improved (grade 4 MRC) and motor aphasia had completely recovered. A follow-up contrast MRI of the brain showed near-complete resolution of the abscess with a small area of enhancement in the left deep frontal region (▶**Fig. 1I, J**).

DOI <https://doi.org/10.1055/s-0043-1774816>.
ISSN 2277-954X.

© 2024. The Author(s).

This is an open access article published by Thieme under the terms of the Creative Commons Attribution License, permitting unrestricted use, distribution, and reproduction so long as the original work is properly cited. (<https://creativecommons.org/licenses/by/4.0/>)

Thieme Medical and Scientific Publishers Pvt. Ltd., A-12, 2nd Floor, Sector 2, Noida-201301 UP, India

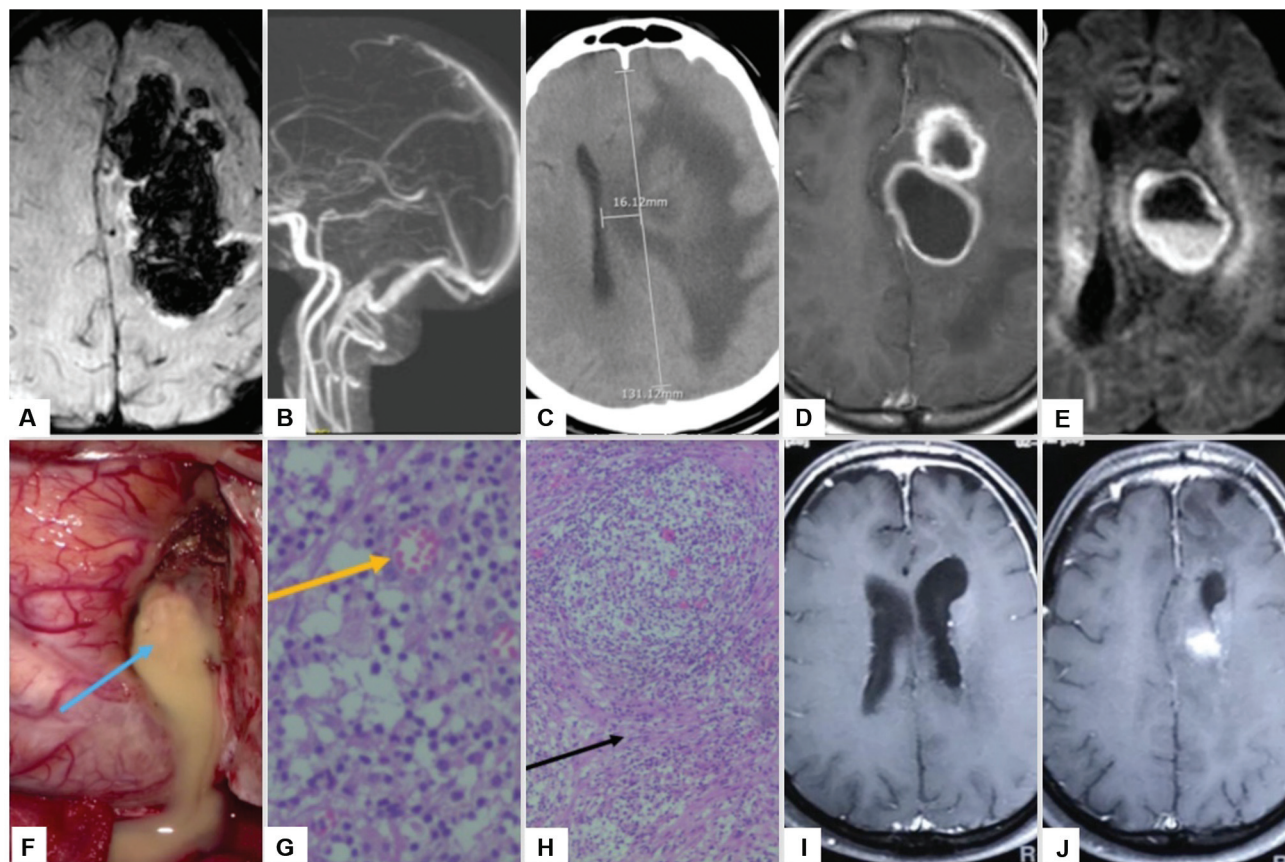


Fig. 1 Magnetic resonance imaging (MRI) of the brain (A) susceptibility weighted imaging (SWI) and (B) venogram showing large hemorrhagic infarct in the left frontoparietal region and occlusion of the anterior portion of the middle one-third of superior sagittal sinus (SSS). (C) Computed tomography (CT) of the brain plain scan at 1-month showing resolution of bleed with increase in edema in the left frontoparietal region with midline shift to right. (D) Contrast MRI of the brain reveals two contiguous ring-enhancing lesions in the left frontal region and (E) diffusion-weighted MRI reveals diffusion restriction of the lesions with fluid level. (F) The intraoperative image reveals dark yellow pus (blue arrow) and thick fibrous capsule being excised. (G, H) Hematoxylin and eosin staining revealed foamy macrophages with multinucleated giant cells (yellow arrow) and fibrous scarring with spindle cells (black arrow) suggestive of chronic abscess with extensive fibrosis. (I, J) Follow-up contrast-enhanced MRI of the brain at 6 weeks showing near-complete resolution of abscess with a small area of enhancement in the deep left frontal region.

Discussion

Cerebral venous thrombosis is a rare cerebrovascular disorder affecting 5 per million people and accounting for nearly 0.5% of all strokes.¹ It presents commonly with headache, seizures, altered sensorium, focal neurological deficit, and raised intracranial pressure. Thrombosis of the transverse sinus and SSS is more common than that of the straight sinus, cortical veins, and deep venous sinuses.² Hemorrhagic infarction due to venous thrombosis is a fairly known entity and approximately 30 to 40% of cerebral venous thrombosis present with intracranial hemorrhage.³

Risk factors for development of cerebral venous thrombosis are prothrombotic conditions, namely, antithrombin III deficiency, protein C and S deficiency; hematological disorders like polycythemia and thrombocythemia; pregnancy; oral contraceptives; and parameningeal infections of the ear, paranasal sinuses or mastoid sinus, dental, oral, or of neck origin.³

Cerebral venous thrombosis secondary to brain abscess is a known entity with the primary source of infection being otitis media, mastoiditis, or cardiac origin, and occurs due to thrombophlebitis as a result of infection in the venous sinus,

leading to venous sinus occlusion.⁴ On the contrary, in our case, there was abscess formation in the hemorrhagic infarct due to venous sinus thrombosis.

Brain abscess complicating an arterial infarct not associated with either surgical or endovascular procedure is rare and only 12 such cases have been reported.⁴ However, only one case of venous infarct complicated by intracranial abscess with source of infection being cutaneous hand infection has been reported in the literature.⁵ In our patient, all investigations done failed to reveal any primary source of infection. He presented to us with a large intracranial abscess 4 months after the primary insult (► **Table 1**).

We propose that the formation of such abscess can be due to blood–brain barrier disruption of the involved region due to hemorrhage, thereby making the area vulnerable to seeding of infection from a distant unknown source, which is similar in case of arterial infarct. Another hypothesis is that it can be due to persistent inflammatory response to blood products or an autoimmune response to the long-standing inflammation causing liquefactive necrosis of the involved neural tissue, further leading to the formation of abscess.

Table 1 Brief summary of previously reported case and our case of brain abscess in a venous infarct

Study	Age/sex	Venous infarct	Fever	Source of infection	Time interval to abscess formation	Species	Management	Outcome
Boukobza ⁵	52/male	Ischemic	+	Skin infection	4 wk	<i>Staphylococcus aureus</i>	Antibiotics + anticoagulation	Favorable
This study	52/male	Hemorrhagic	+	–	5 mo	–	Surgery + antibiotics + anticoagulation	Favorable

The diagnosis of such abscess may remain concealed as it occurs in the same area of infarct, leading to similar neurological deficits.⁶ One should have a high index of suspicion to diagnose such cases when the patient presents with worsening neurology associated with fever. Timely diagnosis and management of these cases is warranted to prevent further worsening of the neurological deficits and to achieve a good outcome.

Conclusion

Cerebral abscess causing cerebral venous thrombosis is a known entity, but venous hemorrhagic infarct complicated by brain abscess is extremely rare. A diagnosis of such atypical brain abscess should be considered if the patient presents lately with deteriorating neurological deficits along with fever. Regular follow-up with serial imaging is highly recommended, which leads to early diagnosis and favorable outcome.

Conflict of Interest

None declared.

References

- 1 Bousser MG, Ferro JM. Cerebral venous thrombosis: an update. *Lancet Neurol* 2007;6(02):162–170
- 2 Ferro JM, Canhão P, Stam J, Bousser MG, Barinagarrementeria FISCVT Investigators. Prognosis of cerebral vein and dural sinus thrombosis: results of the International Study on Cerebral Vein and Dural Sinus Thrombosis (ISCVT). *Stroke* 2004;35(03):664–670
- 3 Saposnik G, Barinagarrementeria F, Brown RD Jr, et al; American Heart Association Stroke Council and the Council on Epidemiology and Prevention. Diagnosis and management of cerebral venous thrombosis: a statement for healthcare professionals from the American Heart Association/American Stroke Association. *Stroke* 2011;42(04):1158–1192
- 4 Boukobza M, Nahmani S, Deschamps L, Laissy JP. Brain abscess complicating ischemic embolic stroke in a patient with cardiac papillary fibroelastoma: case report and literature review. *J Clin Neurosci* 2019;66:277–279
- 5 Boukobza M. Brain abscess complicating venous ischemic stroke: a rare occurrence. *Neurocrit Care* 2021;34(02):682–685
- 6 Kaplan M, Ozveren MF, Erol FS, Kaplan S, Bilge T. Brain abscess developing at the site of preceding stroke. *Neurosurg Q* 2005;15:17–20