



Factors Associated with Intradiscal Vacuum Phenomenon after Traumatic Thoracolumbar Fracture

Takeshi Sasagawa¹ Hiroyuki Hayashi² Yasutaka Takagi²

¹Department of Orthopedic Surgery, Toyama Prefectural Central Hospital, Toyama City, Toyama Prefecture, Japan

²Department of Orthopedic Surgery, Tonami General Hospital, Tonami City, Toyama Prefecture, Japan

Address for correspondence Takeshi Sasagawa, MD, Department of Orthopedic Surgery, Toyama Prefectural Central Hospital, 2-2-78 Nishinagae, Toyama City, Toyama Prefecture, 930-8550, Japan (e-mail: sasagawawagasasa@yahoo.co.jp).

Asian J Neurosurg 2023;18:621–625.

Abstract

Introduction Posttraumatic kyphosis of the thoracolumbar spine is a possible cause of deterioration of activities of daily living. Thus, postoperative kyphosis is an important issue in treating traumatic thoracolumbar fractures. The intradiscal vacuum phenomenon (IVP) after a traumatic thoracolumbar fracture is considered an important predictor of severe kyphosis after implant removal. However, the associated factors are not yet clear.

Methods The study included data from 94 intervertebral discs on the cephalocaudal side of 47 fractured vertebrae of 45 patients for traumatic thoracolumbar fracture due to high-energy trauma. We assessed the demographics of patients (age, sex, cause of injury, location of injured vertebra, fracture type, cephalocaudal side), imaging finding (kyphosis angle of fractured vertebra at the injury, endplate fracture on computed tomography [CT], intervertebral injury on magnetic resonance image [MRI]), and IVP on CT conducted more than 6 months after surgery. We divided the intervertebral discs into an IVP group and a non-IVP group. To identify factors associated with an IVP, univariate analysis and multivariate logistic regression analysis were conducted.

Results IVP was observed in 27 (29%) of 94 intervertebral discs on CTs conducted at an average of 14.0 months postoperatively. In univariate analysis, the IVP group ($n = 27$) had a significantly more cephalic side of the injured vertebra, endplate fracture on CT, and disc injury on MRI compared with the non-IVP group ($n = 67$). A multivariate logistic regression analysis was conducted to identify factors associated with IVP. The cephalic side (odds ratio [OR] = 4.183, 95% confidence interval [CI] = 1.269–13.785) and endplate fracture on CT (OR = 9.564, 95% CI = 1.940–47.143) were identified as independent factors associated with IVP.

Conclusions IVP was observed in 27 (29%) of 94 intervertebral discs. The cephalic side and endplate fracture on CT were identified as independent factors associated with IVP.

Keywords

- ▶ thoracolumbar fracture
- ▶ intervertebral disc
- ▶ degeneration
- ▶ vacuum phenomenon
- ▶ kyphosis
- ▶ associated factor

article published online
September 27, 2023

DOI <https://doi.org/10.1055/s-0043-1775551>.
ISSN 2248-9614.

© 2023. Asian Congress of Neurological Surgeons. All rights reserved.

This is an open access article published by Thieme under the terms of the Creative Commons Attribution-NonDerivative-NonCommercial-License, permitting copying and reproduction so long as the original work is given appropriate credit. Contents may not be used for commercial purposes, or adapted, remixed, transformed or built upon. (<https://creativecommons.org/licenses/by-nc-nd/4.0/>)

Thieme Medical and Scientific Publishers Pvt. Ltd., A-12, 2nd Floor, Sector 2, Noida-201301 UP, India

Introduction

Posttraumatic kyphosis of the thoracolumbar spine is a possible cause of deterioration of activities of daily living. Severe posttraumatic kyphosis requires highly invasive corrective surgery.¹⁻³ Thus, postoperative kyphosis is an important issue in treating traumatic thoracolumbar fractures. Intervertebral disc degeneration is considered the main cause of kyphosis deformity after thoracolumbar fracture.⁴⁻⁶ The intradiscal vacuum phenomenon (IVP) is an imaging finding indicative of disc degeneration.⁷ IVP after a traumatic thoracolumbar fracture is considered an important predictor of severe kyphosis after implant removal.⁸ Therefore, predicting at the time of injury whether IVP will occur is important in determining a treatment plan. However, the associated factors are not yet clear. We sought to investigate the factors associated with IVP after a traumatic thoracolumbar fracture.

Materials and Methods

The medical ethics committee of our hospital approved the present retrospective study, and informed consent to use patient data was obtained from all patients. The study included data from 94 intervertebral discs on the cephalocaudal side of 47 fractured vertebrae of 45 patients who underwent posterior spinal stabilization between December 2012 and March 2022 for traumatic thoracolumbar fracture due to high-energy trauma, such as a fall from a height, traffic accident, sports, or blow from a heavy object. Exclusion criteria included age over 70 years, osteoporotic or

pathological vertebral fracture, vertebral fracture with adjacent vertebral fracture, dislocation fracture, and lack of data. Surgery was indicated for fractures associated with a neurological deficit, more than 5 points of load sharing classification score,⁹ posterior tension band disruption, or polytrauma. We assessed the demographics of patients (age, sex, cause of injury, location of injured vertebra, fracture type [AO classification],¹⁰ cephalocaudal side), imaging finding (kyphosis angle of fractured vertebra at the injury, endplate fracture on computed tomography [CT], intervertebral injury on magnetic resonance imaging [MRI]), and IVP on CT conducted more than 6 months, but less than 36 months after surgery (►Fig. 1). The kyphosis angle of the fractured vertebra was measured as the angle between the superior and inferior endplates of the vertebral body. The endplate fracture on CT was defined as a gap or step of more than 2 mm, or irregularity in the endplate (►Fig. 1). Intervertebral injury on MRI was measured using the methodology described by Sander et al¹¹ (►Fig. 2). This method defines four categories of intervertebral disc injuries, from grade 0 to grade 3. Grade 0 indicates no difference between the injured disc and a comparable uninjured disc. Grade 1 is defined as hyperintense appearances in T2-weighted images indicating edema. The exclusion criteria for grade 1 are vascularization of the disc due to chronic spondyloarthropathy and fibrovascular endplate changes, but a loss of disc height or facet, or ligamenta flava hypertrophy. Grade 2 is defined as a decrease in signal intensity with a perifocal hyperintense appearance in T2-weighted images and isointense-to-hyperintense appearance in T1-weighted images, suggesting a disc rupture with intradiscal bleeding. Grade 3

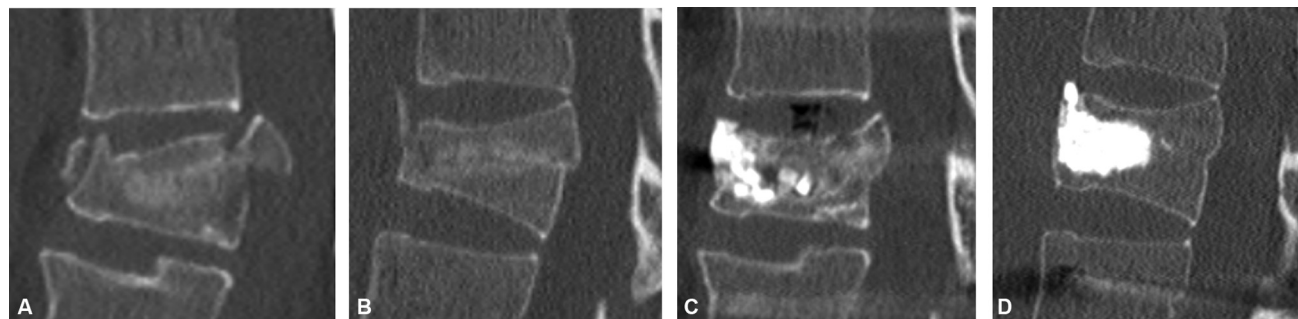


Fig. 1 Illustrative computed tomography findings of endplate fracture and intradiscal vacuum phenomenon (IVP). (A) Illustrative case with endplate fracture. (B) Illustrative case without endplate fracture. (C) Illustrative case with IVP. (D) Illustrative case without IVP.

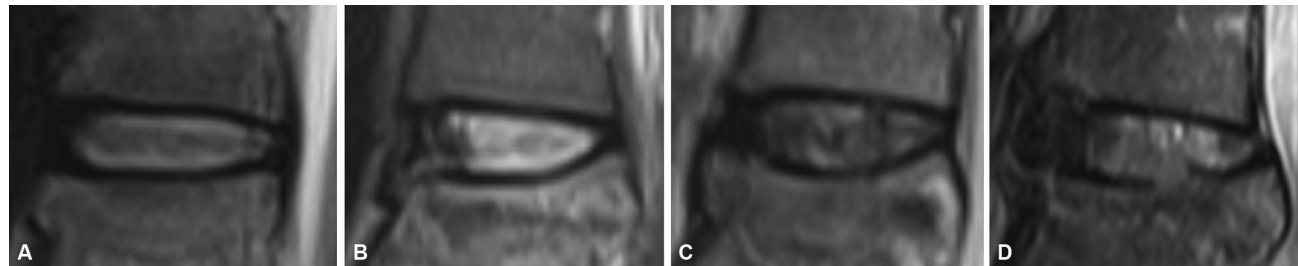


Fig. 2 Classification of traumatic intervertebral disc lesions on magnetic resonance imaging.¹¹ (A) Grade 0 is defined as an uninjured disc. (B) Grade 1 is defined as a disc with edema. (C) Grade 2 is defined as a disc rupture with intradiscal bleeding. (D) Grade 3 is defined as an infarct of the disc into the vertebral endplate.

is defined as an infract of the disc into the vertebral body, annular tears, or herniation into the endplate. Because the timing of postoperative CT may affect IVP, the time between CTs was also investigated. We divided the intervertebral discs into an IVP group and a non-IVP group. We compared the two groups for age, sex, cause of injury, location of the injured vertebra, fracture type, cephalocaudal side, kyphosis angle of the fractured vertebra, endplate fracture on CT, and intervertebral injury on MRI. To identify factors associated with an IVP, a multivariate logistic regression analysis was conducted in which the presence or absence of an IVP was used as a dependent variable, and items that were significantly different by univariate analysis were independent variables.

Statistical Analyses

All data are expressed as mean ± standard deviation. A Mann–Whitney U test, chi-squared test, or Fisher’s exact test were used to compare each item. A multivariate logistic regression analysis was used to identify the factors associated with IVP. Differences with *p*-value less than 0.05 were considered significant. All statistical analyses were conducted using IBM SPSS Statistics for Windows (version 22; IBM Corp, Armonk, New York, United States).

Results

There were 30 men and 15 women with a mean age of 43.1 ± 16.7 years (range, 12–69 years). The cause of injury was a fall from a height in 27 cases, a traffic accident in 10 cases, sports in 5 cases, and blows by a heavy object in 3 cases. The level of fractured vertebrae was 1 vertebra in T6, 1 in T11, 3 in T12, 22 in L1, 12 in L2, 2 in L3, 5 in L4, and 1 in L5. The AO classification was A1 with 2 vertebrae, A3 with 17, A4

with 8, B1 with 4, and B2 with 16. The kyphosis of the fractured vertebra at the time of injury averaged 13.9 ± 8.7 degrees. In 94 intervertebral discs, endplate fracture on CT was observed in 47 (50%), and intervertebral injury on MRI in 78 (83%). Of the 78 intervertebral discs with intervertebral injury on MRI, 20 discs were classified as grade 1, 34 were grade 2, and 24 were grade 3. IVP was observed in 27 (29%) of 94 intervertebral discs on CTs conducted at an average of 14.0 months postoperatively. IVP (*n* = 27) and non-IVP (*n* = 67) groups were compared using univariate analysis. The IVP group had a significantly more cephalic side of the injured vertebra, endplate fracture on CT, and disc injury on MRI compared with the non-IVP group (► **Table 1**). A multivariate logistic regression analysis was conducted to identify factors associated with IVP. The cephalic side (odds ratio [OR] = 4.183, 95% confidence interval [CI] = 1.269–13.785) and endplate fracture on CT (OR = 9.564, 95% CI = 1.940–47.143) were identified as independent factors associated with IVP (► **Table 2**).

Discussion

IVP is the collection of gas within an intervertebral disc and is mainly perceived as a sign of degenerative disc disease. The presence of IVP represents one of the signs of disc ruptures with a significant structural change.⁷ IVP occurs significantly more often in traumatic thoracolumbar fractures and may lead to disc degeneration due to nutritional supply disturbances via the vertebral endplate.¹² The incidence of IVP after thoracolumbar fracture is reported to be 23 to 49%.^{8,12} In this study, we found the rate was 29%, as consistent with previous reports. In traumatic thoracolumbar fractures, the presence of IVP causes severe kyphosis at the intervertebral

Table 1 Demographic data and the imaging findings between the IVP group and non-IVP group

Variable	IVP group (<i>n</i> = 27)	Non-IVP group (<i>n</i> = 67)	<i>p</i> -Value
Sex (male/female)	20/7	44/23	0.43
Age (years)	47.5 ± 15.7	42.4 ± 17.0	0.21
Time between CTs (months)	13.4 ± 6.0	14.0 ± 7.5	0.80
Cause of injury			0.83
Fall from height/traffic accident/sports/blow by a heavy object	16/7/2/2	42/13/8/4	
Location of the injured vertebra T6/T11/T12/L1/L2/L3/L4/L5	0/1/1/14/7/1/1/2	2/1/5/30/17/3/9/0	0.28
Fracture type (AO classification) A1/A2/A3/A4/B1/B2	1/0/10/6/1/9	3/0/24/10/7/23	0.80
Cephalocaudal side Cephalic/caudal	22/5	25/42	<0.01
Kyphosis angle of the fractured vertebra	12.2 ± 11.0°	14.6 ± 7.5°	0.71
Endplate fracture on CT Yes/No	24/3	23/44	<0.01
Intervertebral injury on MRI Yes/No	26/1	52/15	0.03

Abbreviations: CT, computed tomography; IVP, intervertebral vacuum phenomenon; MRI, magnetic resonance image.

Table 2 Data for each associated factor using binomial logistic regression analysis

Factor	p-Value	Odds ratio	95% Confidence interval
Cephalic side	0.02	4.183	1.269–13.785
Endplate fracture on CT	<0.01	9.564	1.940–47.143
Intervertebral injury on MRI	0.86	1.254	0.100–15.653

Abbreviations: CT, computed tomography; MRI, magnetic resonance image.

disc, which is the mainspring for posttraumatic kyphosis.⁸ Thus, the presence of IVP can be considered a result of severe disc degeneration. In determining a treatment plan at the time of injury to prevent posttraumatic kyphosis, it is important to predict whether IVP will occur. This study investigated the factors associated with IVP. We identified the cephalic side and endplate fracture on CT as independent factors associated with IVP.

Generally, disc degeneration after thoracolumbar fracture is more likely to occur in the cephalad disc.¹³ We found the cephalad side of the injured vertebra was also an independent factor associated with the occurrence of IVP. In thoracolumbar fractures, mechanical stress is more likely to be applied on the cephalad side of the vertebra.¹⁴ Similarly, in the intervertebral discs at the time of injury, the cephalad endplate is considered to have more extensive damage than the caudal endplate. At the time of injury, posttraumatic disc degeneration is attributed to the injury, and kyphosis reoccurrence is considered inevitable.¹⁵ In other words, the cephalad disc, which is more vulnerable to damage at the time of injury, is thought to be more prone to degeneration and the occurrence of IVP.

Endplate fractures are associated with disc degeneration.^{13,16} Annulus tears and endplate fractures are common lesions in damaged intervertebral discs. Przybyla et al reported that outer annulus tears have fewer effects on intradiscal compressive stresses than endplate fracture and concluded that endplate fracture provides a greater stimulus for disc degeneration.¹⁷ In this study, an endplate fracture was an independent factor associated with IVP. There exists an opinion that endplate degeneration is responsible for the occurrence of IVP.¹⁸ The endplate fracture may result in degeneration of the endplate, suggesting that it is involved in IVP occurrence. Based on the results of this study, because CT is commonly used for the initial evaluation of trauma and clearly depicts endplate fracture, it is a useful modality in predicting IVP.

In this study, cases in which CT and MRI were obtained at the time of injury were considered. We found the presence of endplate fracture on CT was an independently associated factor, while disc injury findings on MRI were not an independently associated factor. MRI findings of disc injury are not associated with eventual disc degeneration.¹⁹ Sander et al reported that traumatic disc injury findings on MRI were present in 71% of patients.¹¹ Consistently, the present results showed MRI findings of disc injury in 83% of the patients. Furthermore, in the non-IVP group, 78% also had disc injury

findings on MRI. In other words, disc injury findings on MRI were not an independently associated factor of IVP because the imaging would have depicted disc injuries that did not lead to degeneration as abnormal findings. Based on the results of this study, CT is more useful at the time of injury than MRI disc findings to predict the occurrence of IVP, and is more likely to reveal endplate fractures.

There are some limitations to this study. Because this study included patients who had CT and MRI at the time of injury and CT 6 months or later after the injury, the sample size was small, and there is a possibility of selection bias. Some patients did not have implants removed, so it is not possible to determine any association between IVP and the kyphosis angle or back pain after implant removal. Further study is necessary to understand further the factors associated with IVP after a thoracolumbar fracture.

Conclusions

IVP was observed in 27 (29%) of 94 intervertebral discs. The cephalic side and endplate fracture on CT were identified as independent factors associated with IVP.

Authors' Contributions

Takeshi Sasagawa contributed to conception and design of the study, collection and analysis of data, and critical revision of the article for important intellectual content. Yasutaka Takagi and Hiroyuki Hayashi were involved in collection of data.

Ethical Approval

The study has been performed in accordance with the ethical standards in the 1964 Declaration of Helsinki. This study was approved by Toyama Prefectural Central Hospital review board (No.6456).

Informed Consent

Informed consent was obtained by all participants in this study.

Conflict of Interest

None declared.

References

- Gertzbein SD, Harris MB. Wedge osteotomy for the correction of post-traumatic kyphosis. A new technique and a report of three cases. *Spine* 1992;17(03):374–379

- 2 Munting E. Surgical treatment of post-traumatic kyphosis in the thoracolumbar spine: indications and technical aspects. *Eur Spine J* 2010;19(Suppl 1):69–73
- 3 El-Sharkawi MM, Koptan WM, El-Miligui YH, Said GZ. Comparison between pedicle subtraction osteotomy and anterior corpectomy and plating for correcting post-traumatic kyphosis: a multicenter study. *Eur Spine J* 2011;20(09):1434–1440
- 4 Peng Z, Cui Z, Kuang X, et al. Intervertebral disc injury is the mainspring for the postoperative increase in Cobb Angle after thoracolumbar burst fracture. *J Orthop Surg (Hong Kong)* 2022;30(02):10225536221088753
- 5 Aono H, Tobimatsu H, Ariga K, et al. Surgical outcomes of temporary short-segment instrumentation without augmentation for thoracolumbar burst fractures. *Injury* 2016;47(06):1337–1344
- 6 Spiegl UJ, Josten C, Devitt BM, Heyde CE. Incomplete burst fractures of the thoracolumbar spine: a review of literature. *Eur Spine J* 2017;26(12):3187–3198
- 7 Murata K, Akeda K, Takegami N, Cheng K, Masuda K, Sudo A. Morphology of intervertebral disc ruptures evaluated by vacuum phenomenon using multi-detector computed tomography: association with lumbar disc degeneration and canal stenosis. *BMC Musculoskelet Disord* 2018;19(01):164
- 8 Hirahata M, Kitagawa T, Yasui Y, et al. Vacuum phenomenon as a predictor of kyphosis after implant removal following posterior pedicle screw fixation without fusion for thoracolumbar burst fracture: a single-center retrospective study. *BMC Musculoskelet Disord* 2022;23(01):94
- 9 McCormack T, Karaikovic E, Gaines RW. The load sharing classification of spine fractures. *Spine* 1994;19(15):1741–1744
- 10 Vaccaro AR, Oner C, Kepler CK, et al; AOSpine Spinal Cord Injury & Trauma Knowledge Forum. AOSpine thoracolumbar spine injury classification system: fracture description, neurological status, and key modifiers. *Spine* 2013;38(23):2028–2037
- 11 Sander AL, Laurer H, Lehnert T, et al. A clinically useful classification of traumatic intervertebral disk lesions. *AJR Am J Roentgenol* 2013;200(03):618–623
- 12 Schömig F, Palmowski Y, Nikiforov I, et al. Burst fractures lead to a fracture-associated intervertebral vacuum phenomenon: a case series of 305 traumatic fractures of the thoracolumbar spine. *Eur Spine J* 2021;30(10):3068–3073
- 13 Wang J, Zhou Y, Zhang ZF, Li CQ, Zheng WJ, Liu J. Radiological study on disc degeneration of thoracolumbar burst fractures treated by percutaneous pedicle screw fixation. *Eur Spine J* 2013;22(03):489–494
- 14 Guo LX, Li WJ. A biomechanical investigation of thoracolumbar burst fracture under vertical impact loads using finite element method. *Clin Biomech (Bristol, Avon)* 2019;68:29–36
- 15 Aono H, Ishii K, Tobimatsu H, et al. Temporary short-segment pedicle screw fixation for thoracolumbar burst fractures: comparative study with or without vertebroplasty. *Spine J* 2017;17(08):1113–1119
- 16 Su Q, Li Y, Feng X, et al. Association and histological characteristics of endplate injury and intervertebral disc degeneration in a rat model. *Injury* 2021;52(08):2084–2094
- 17 Przybyla A, Pollintine P, Bedzinski R, Adams MA. Outer annulus tears have less effect than endplate fracture on stress distributions inside intervertebral discs: relevance to disc degeneration. *Clin Biomech (Bristol, Avon)* 2006;21(10):1013–1019
- 18 Li FC, Zhang N, Chen WS, Chen QX. Endplate degeneration may be the origination of the vacuum phenomenon in intervertebral discs. *Med Hypotheses* 2010;75(02):169–171
- 19 Fürderer S, Wenda K, Thiem N, Hachenberger R, Eysel P. Traumatic intervertebral disc lesion—magnetic resonance imaging as a criterion for or against intervertebral fusion. *Eur Spine J* 2001;10(02):154–163