

Associated Anomalies With Those Of The Hands

Prof. F.M. Tripathi
Dr. R. Atam
Dr. A.K. Rai
Prof. S.K. Gupta

ABSTRACT

The present study is based on the observations of associated anomalies with those of the 50 cases of congenital hand anomalies. 15 cases had associated anomalies of feet and 4 had anomalies of the other parts of the body like face and genito urinary tract.

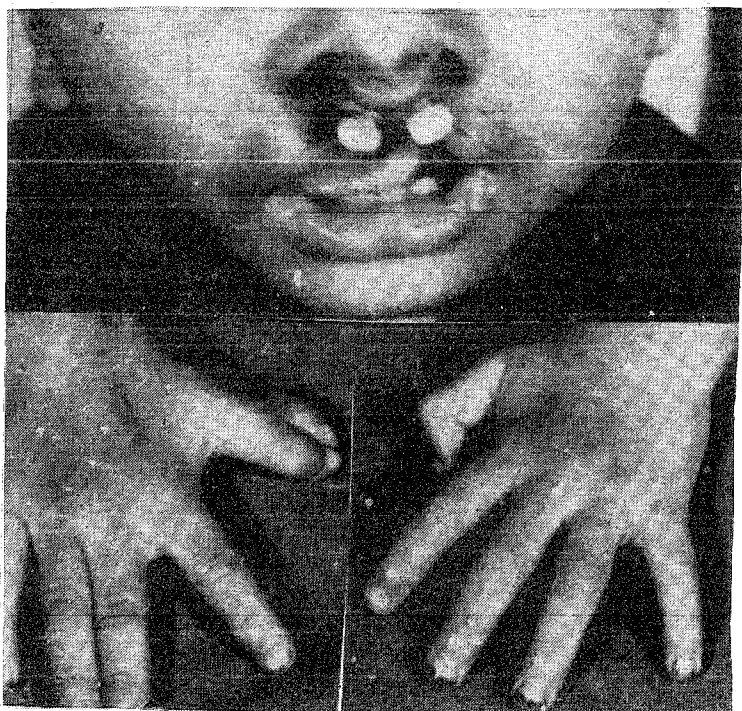
CHROMOSOMAL ABERRATIONS :

Trisomy 21. is one of the severe chromosomal aberration which inflicts the hand. In about half the subjects with this complex, palm possesses a four finger line or simian crease, the middlephalanx of fifth digit is short and rhomboid in shape and its distal segment inclines in a radial direction; less commonly, thumb is clasped in the palm. In trisomy 13-15, the finger nails are hyperconvex, and there is usually an extra digit. In trisomy 18, the fingers are contracted and overlap, and the radius may be missing.

OROMALIC COMPLEXES

Development of the oral cavity, its contents, and surrounding structures coincides with that of the upper extremity. In both instances, organogenesis is initiated around the fourth post ovulatory week, and structures attain definitive shape by the end of seventh week (Kelikian, 1974). The upper limb, in particular the hand, develops by the process of formation of solid mass of tissue,

while the mouth attains the final form by the fusion of separate parts. So the congenital anomalies of hand and forearm may be due to absent or excessive segmentation, while those of mouth result from failure of fusion of different parts (Kelikian, (1974). Cleft lip and palate is known to be accompanied by excessive longitudinal segmentation of embryonic hand plate - polydactyly, or failure of longitudinal fusion results in syndactaly.



OCULOMELIC COMPLEXES :

Probably more abnormalities are known of the hand than any other part of the body except eye (Gates, 1946). Usually both are associated with each other. In acrocephalosyndactyly the fingers are confluent, there is atrophy of the optic nerves. In Ehlers - Danlos syndrome fingers are hyperflexible and accompanying anomalies of eye like microcornea or keratoconus are associated. In facial diplegia synbrachydactyly with ptosis or proptosis is present. Polydactyly and retinitis pigmentosa are two main features of Laurence-Moon-Bardet-Biedl syndrome. (Kelikian, 1974). Occulodentodigital dysplasia consists of microcorned, enamel hypoplasia and soft tissue syndactyly of ring and little finger; the involved digits are deviated in ulnar direction. In trisomy 13-15 polydactyle coexists with microphthalmia. In trisomy 18, the fingers overlap, the cornea is opaque and the eye lids droop.

Split hand is also reported with congenital cataract. Similarly, many other complexes are also reported in association with hand anomalies. (Haim, 1974).

OTOMELIC COMPLEXES

In embryo, the auditory pit makes its appearance about a week earlier than limb bud. Formation of joint between malleus, incus, and stapes and formation of joint of two consecutive phalanges begins around eighth or ninth week of embryonic development. So conductive deafness (otosclerosis) is not an uncommon accompaniment of symphalangism.

Sensorineural deafness at times accompanies ectodermal dysplasia with polydactyly or syndactyly. In Otopalatodigital (OPD) syndrome, there is deafness, dwarfism, cleftpalate, dislocation of the radial head and clinodactyly of the little finger.

CARDIOMELIC COMPLEXES

The limb buds and the primitive heart tube appear about the same time in the embryo and develop simultaneously, so there is preferential association of heart and upper limb anomalies. Usually these anomalies are associated with radial ray defects. Occasionally polydactyly and syndactyly are seen in connection with congenital heart diseases. Atrial septal defect and nonopposable triphalangeal thumb are the main features of the Holt-Oram syndrome. In trisomy 13-15, postaxial polydactyly is associated with ventricular septal defect. In Marfan's syndrome, fingers are long, thin and tapered and at times associated with aortic regurgitation.

HAND AND FOOT COMPLEXES

Serial homology is often seen in polydactyly and syndactyly. In almost all cases of split hand the feet are cloven. Brachydactyly, symphalangism, the congenital clubbing of digits are usually associated with hand anomaly (Kummer, 1974). In Hand- foot anomalies the first metacarpal is dwarfed, the hallux is short, terminal phalanx, and os calcis is fused with cuboid bone. Hand foot syndrome with sickle cell anemia is characterized by painful swelling of the hand and feet of infants.

HEMATOMELIC DEFICIENCIES

Primitive blood cells begin to form in the yolk sac during the fourth week of embryonic development at about the time of the appearance of the limb bud. Hematopoiesis starts within the body mesenchyme and the liver during the fifth or sixth week around the time of critical differentiation of the radial ray. The most common hand and forearm anomaly seen in association with congenital blood dyscrasia is radial ray defect.

Radial ray defect is most commonly seen in panmyelopathy and in platelet hypoplasia. Triphalangeal thumb is occasionally seen in infants with hypoplastic anemia. In hand and foot syndrome sickle cell anemia is also seen

OBSERVATION AND DISCUSSION

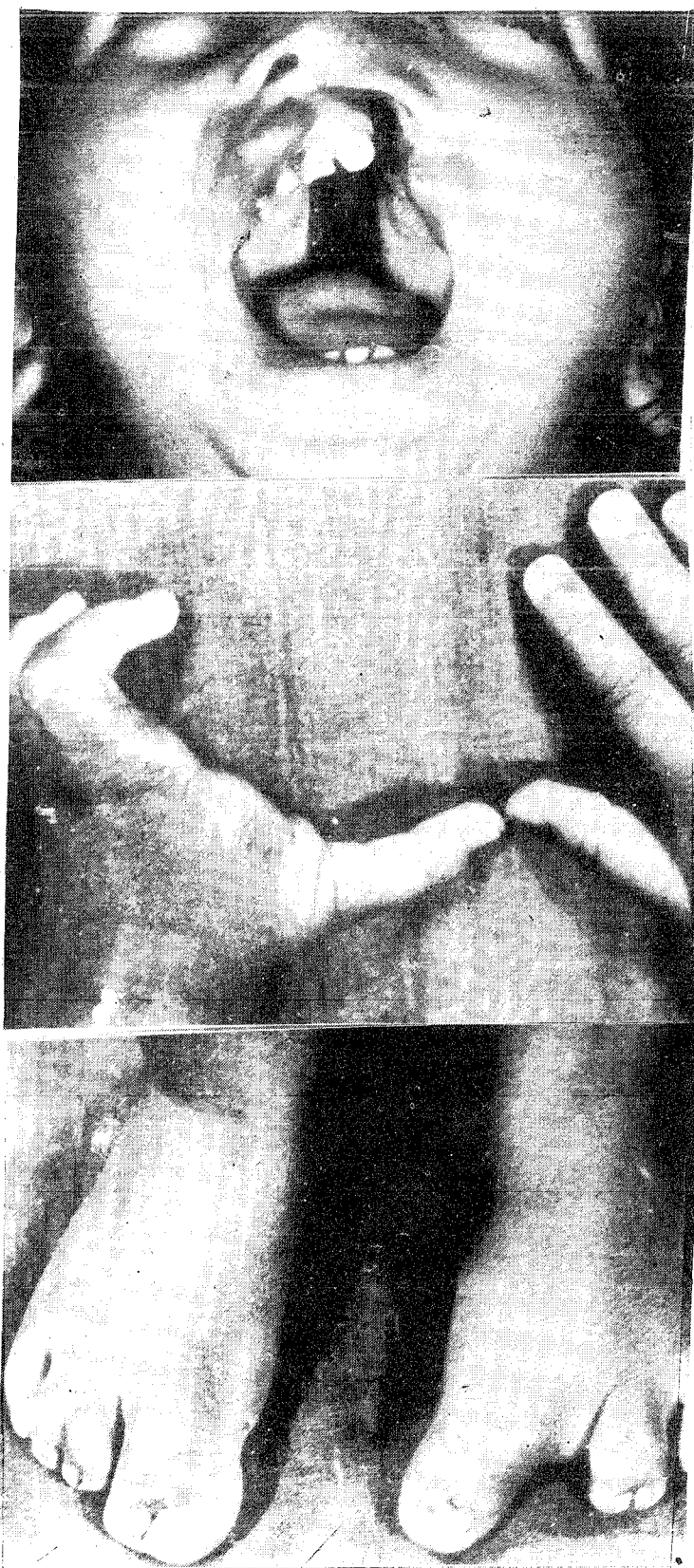
Table : I showing other associated anomalies in the body

Total cases with hand anomaly	Associated anomalies of the lower limb		Congenital anomalies in other parts of the body,	
	No.	%	No.	%
50	15	30	4	8

Table - I shows 15 patients (30.0%) with simultaneous congenital anomaly of lower limbs and 4 (8.0 %) patients with congenital anomalies of the other parts of the body. Patients with other anomalies of the body are as follows :

Case I (P.K.) had bilateral complete and simple syndactyly of II and III digits with bilateral cleft lip and bilateral cleft palate.

Case II (P.K.) bilateral simple and completely syndactyly of index and middle finger with hypospadias.



Case IV (R) had ectrodactyly of II and III digits in which all the phalanges were absent with intact metacarpals. There was bilateral syndactyly of the foot between I and II toe and III and IV toes of right foot; and between I and II toe in the left foot. He also had right cleft lip with bilateral cleft palate.

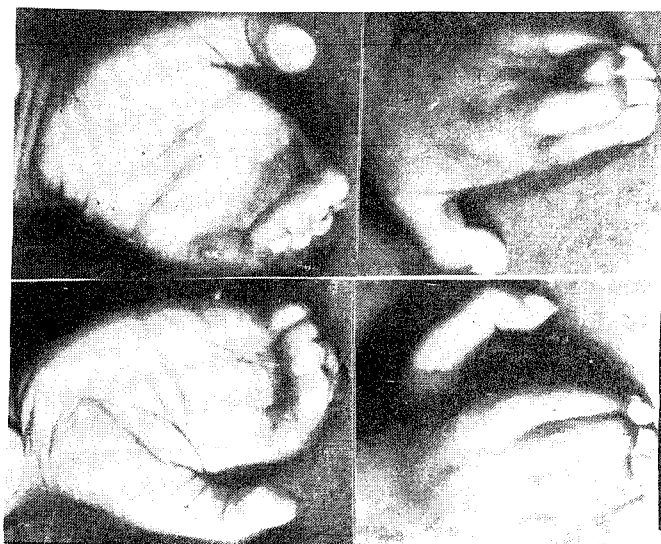
Table : II Other associated anomaly with syndactyly.

Type	No.	Percentage of syndactylous cases
Polydactyly	5	15
Ectrodactyly	2	6
Brachydactyly	2	6
Annular grooves	1	3
Others	0	0

In total of 33 patients with syndactyly 7 (21.0 %) patients had other associated anomalies of the hand. 5 (15.0 %) had associated polydactyly. One of them had syndactyly of ulnar polydactylous finger with the little finger of that hand (Table II).

Two (6.0 %) patients had ectrodactyly with syndactyly in right hand only. In right hand, patient had ectrodactyly of middle and ring finger with the absence of middle and distal phalanges both the fingers and both the ectrodactylous fingers were syndactylized with bony fusion. In the left hand of the same patient ectrodactyly was seen in index and middle finger with the absence of middle and distal phalanges in the former and absence of distal phalanx only in the latter. These were associated with the brachydactyly of ring finger of left hand.

Other patient of ectrodactyly had syndactyly of right hand and ectrodactyly in the left hand with left sides annular grooves.



Two (6.0 %) patients had brachydactyly: one of the patients had short proximal, middle and distal phalanges of IV digit of left hand and syndactyly of III and IV digit and short middle phalanx of the III digit.

One patient who had syndactyly with ectrodactyly, also had bilateral annular groove. These were present at metacarpophalangeal joint in 4 and 5th digit and in proximal interphalangeal joint in the 3rd digit (Table II).

Table : III Syndactyl with other associated anomalies of the body.

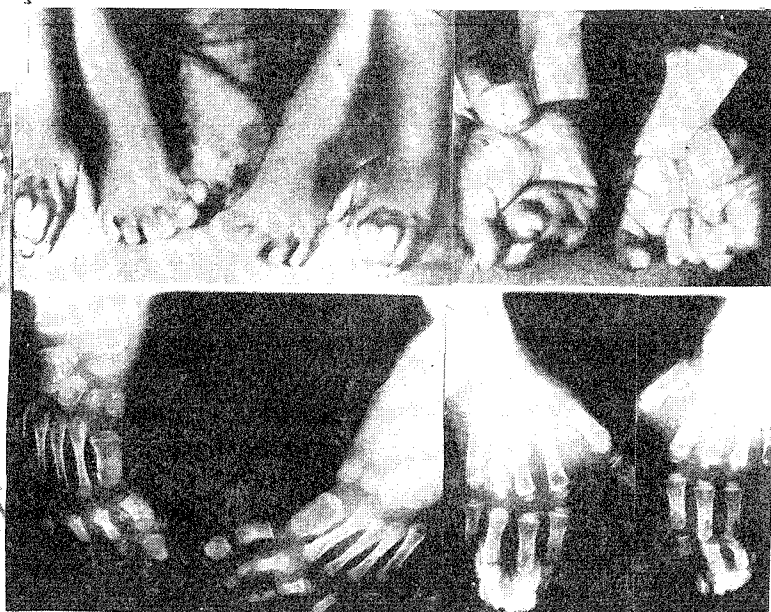
Total No. of Syndactyly.	With associated anoma of the body	No.	%
33	13 (39.0 %)Foot anomalies	1	33.0
	Face	1	3.0
	Genito urinary	1	3.0
	Others	0	0

Out of 33 patients with syndactyly 13 (39.0 %) had associate other anomalies of the body (Table III).

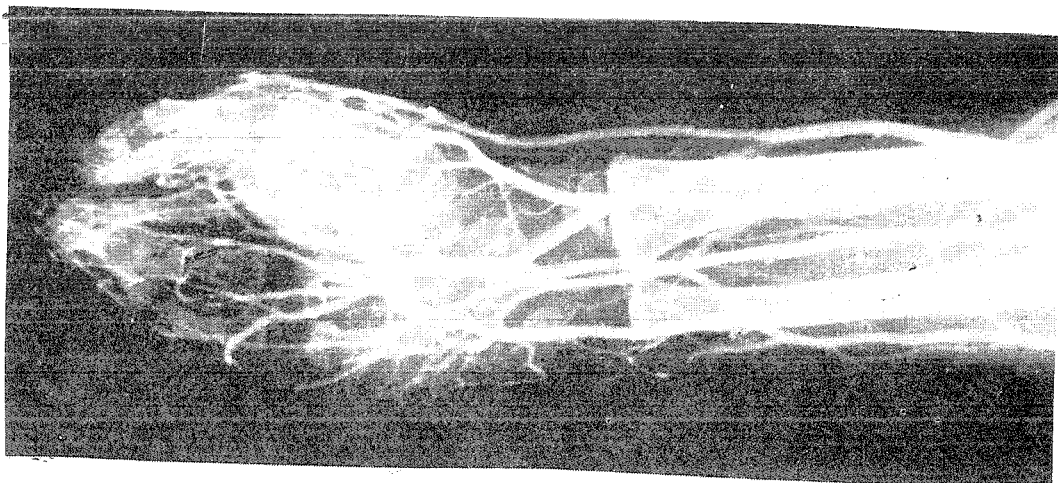
FOOT ANOMALIES :

Out of 50 cases of hand anomalies 15 (30.0 %) had associated congenital foot anomalies and all of them were associated with syndactyly of the hand. Three of them had only syndactyly of the foot.

One patient had syndactyly II and III digits of left hand along with syndactyly of 2nd, 3rd toe of the left foot. Second patient had bilateral syndactyly of 4th and 5th toe. Third patient had bilateral syndactyly of III and IV digit with the bilateral syndactyly of 2nd and 3rd toe. (Photo - D).



One (B) of the patient had nubbin in the form of polydactyly of foot on the medial side of the great toe on the left foot with syndactyly of the II to V digits on both the hands, and had bilateral syndactyly of I, II and III toe. Brachial angiogram of the same patient



of left hand shows crowding of vessels with venous filling too. (Photo - E)

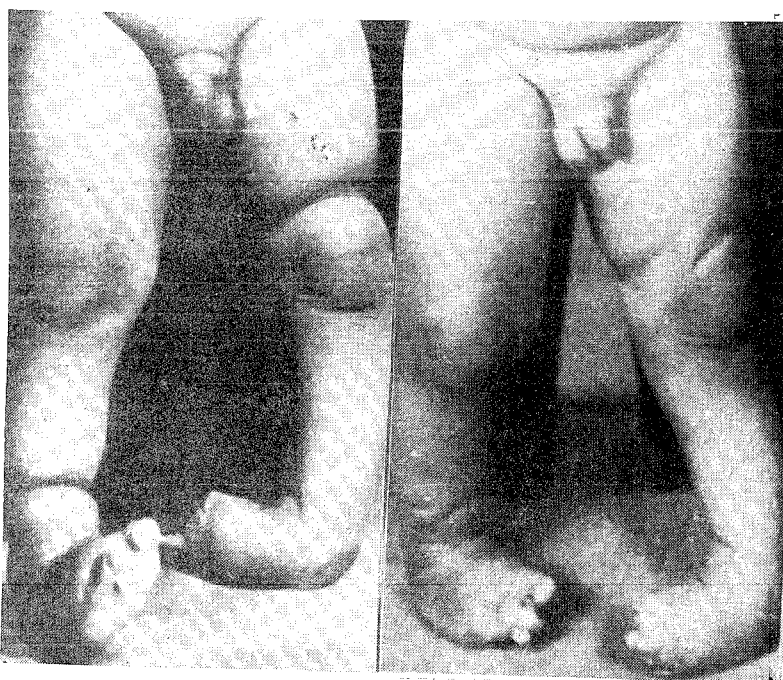
Four patients had syndactyly with polydactyly of the foot along with the syndactyly of the hand. One patient had bilateral syndactyly and polydactyly of foot. Second patient had 7 toes on both the foot. Polydactylous toes were on the lateral side of the foot. Pattern of syndactyly associated was - on the right side medial four toes were webbed and on the left side medial 4 toes were webbed and lateral two were also webbed separately i.e. there was no webbing between 4 and 5 toe and lateral two polydactylous toes were webbed. These were associated with the bilateral syndactyly of IV and V digits of the hand alongwith the ulnar polydactyly of both hands.

Third patient had syndactyly of III and IV digits of the hand in which on left side middle phalanx of middle finger was short along with foot anomalies, like 6th finger in both the foot on the lateral side and syndactylous 5th and 6th toes. Last patient had syndactyly of III and IV digit of both hands with bilateral lateral polydactyly with syndactyly of 5th and 6th toes in both feet.

Three patients had congenital talipes equinus varus. One patient had right side syndactyly of I and II digit and partial syndactyly of IV and V digits with bilateral congenital talipes equine varus.

Other patient had right sided congenital talipes equinus varus with left sided rudimentary III^d toe with unilateral right sided syndactyly of I to IV digits.

Lastly one patient (R.P.) had bilateral congenital talipes equine varus with bilateral asymmetrical syndactyly with annular grooves on the lower limbs.



REFERENCES :

1. Haim, F. : Split Hand Complexes in congenital deformities of the hand and forearm. Kelikian, H. : W.B. Saunders Pub., Philadelphia (1974).
2. Kelikian, H. (Ed) : Casual relations in congenital deformities of hand and forearm. W.B. Saunders Pub. Philadelphia. pp. 16-47 (1974).
3. Kelikian, H. (Ed.) : Syndromes implicating the hand and the forearm. W.B. Saunders Pub., Philadelphia. pp. 89-131 (1974)
4. Kummeiz, E. : Syndactyly in congenital deformities of the hand and forearm by Kelikian, H. Pub. W.B. Saunders, Philadelphia (1881).
5. Patterson, T.J.S. : Classification of the congenitally deformed hand. Brit. J. Plastic Surg. 17 : 142-144 (1964).

AUTHOR'S NAME AND ADDRESS :

1. Prof. F.M. Tripathi, (Professor)
2. Dr. R. Atam, Resident
3. Dr. A.K. Rai, Orthopaedic Surgeon
4. Prof. S.K. Gupta (Professor).

Divison of Plastic Surgery
Institute of Medical Sciences
Banaras Hindu University,
Varanasi - 221 005 (INDIA)