Indian Journal of Plastic Surgery 1995, 28, 57-62

INDIAN JOURNAL OF PLASTIC SURGERY

RECONSTRUCTION OF SKULL BASE USING LOCALLY AVAILABLE ALTERNATIVES : A REVIEW

Atul Goel
Department of Neurosurgery, Seth G.S. Medical College and K.E.M. Hospital, Bombay.

INTRODUCTION

Surgery for cranial basal lesions has become sophisticated in the last decade. Adequate reconstructive procedures are necessary to provide for rigid compartmentalization after an elaborate skull base operation. Some inherent problems involved in skull base reconstruction are:

1) The proximity of the skull base to potentially infective spaces of paranasal sinuses, nasal, oral and pharyngeal pathways, external ear canal and other such spaces. After surgery, it is important to seal off the cranial cavity from these spaces to avoid ascending infections.

2) The basal dura is relatively thin, friable and densely stuck to the bone. Approximation of edges and water tight suturing often may not be possible especially in areas of vessel and nerve transit.

3) Occasionally following a surgical procedure the site of cerebrospinal fluid (CSF) fistula cannot be deciphered. It is pertinent therefore that all the potential sites of CSF leakage be recognized during surgery and adequately taken care of.

4) Some tumors involve the basal bone and dura, and for achieving a radical resection these structures have to be removed elaborately. Opening up of paranasal air sinuses, middle ear cavity and eustachian tube, can subject the patient to risks of cerebrospinal fluid fistula.

5) Frequently there are large dead spaces that need to be filled in after basal bone, soft tissue and tumor resection.

6) Many skull basal procedures are of long duration. Many surgeons are involved in the operation and extensive instrumentation is used. All these factors add to the risk of infections.

7) The reconstruction begins at the end of a relatively long operation when the operative team may be exhausted and errors of omission may be made.

A. SOFT TISSUE RECONSTRUCTION (INCLUDING RECONSTRUCTION OF THE DURA)

A recollection of the relevant anatomy would be useful here.[1,2] The superficial temporal fascial layer is part of the epicranial aponeurosis whilst the deep temporal fascial layer covers the superficial aspect of the temporalis muscle down to the zygomatic arch. These fascial layers have a separate arterial and venous supply and have been used as a homograft, a rotation flap or free microvascular flap. The deep temporal fascia is separated from the superficial fascia by a plane of loose areolar tissue. The temporalis muscle and the deep layer of the fascia receive their blood supply from the anterior, middle and posterior deep temporal arteries. These vessels run between the muscle and the periosteum and subperiosteal elevation of this fan shaped muscle results in a viable muscle flap. The deep layer of the temporalis fascia is nourished by multiple small branches which traverse through the muscle. Partial eversion of the deep layer of fascia from the muscle preserving the small vascular connections can result in a flap of vascularized fascia.

Muscle Flaps

The temporalis muscle can be effectively rotated on its pedicle to cover defects of the middle cranial fossa including the base[3] This muscle can be used in its entirety or it could be vertically split (preserving one of the main feeding vessels) and only a part of it used (Fig 1).

Sternocleidomastoid and other muscles of the nape of the neck can be rotated superiorly to cover defects in the posterior cranial base. These operations are fairly standard now.

Pericranial and Galeal Flaps

These flaps have been extensively used for reconstruction of basal defects. Their use is more effective for the anterior cranial base. The pericranium comprises of an outer layer of loose

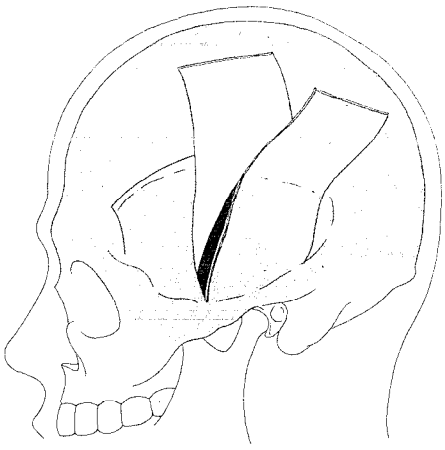

(Fig - 1) Line drawing showing vertical splitting of the temporalis muscle into two parts. The anterior part is kept in situ, preserving its attachment into the coronoid process. The posterior part is elevated subperiosteally as a muscle flap with a pericranial extension.

areolar tissue and an inner layer of osteoblasts and contains an extensive vascular network. The pericranium derives blood supply anteriorly from the supratrochlear and supraorbital arteries and laterally from the superficial temporal arteries. The pericranial layer pedicled flaps can be based on either of these vessels, and accordingly, rotated anteriorly or laterally (Fig. 2a,b). Pericranium is thin in the region of frontal bosses and over the parietal convexity and requires careful dissection to prevent it from getting torn. It could be taken with a portion of the outer table of the skull as well. (Fig 2c)

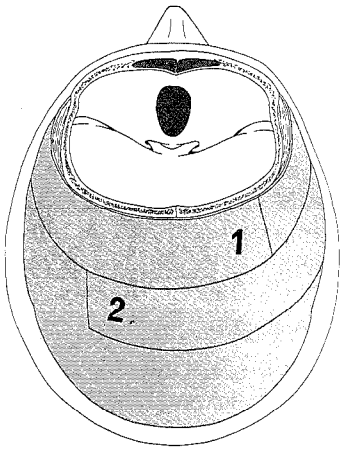

(Fig - 2a) Line drawing shows a bifrontal craniotomy. The shaded area shows the pericranial cover of the skull bone. The transverse lines show the sites of pericranial layer incision for the purpose of harvesting of the flaps. Two pericranial or subgaleal fascia pericranial flaps numbered 1 and 2 are shown.

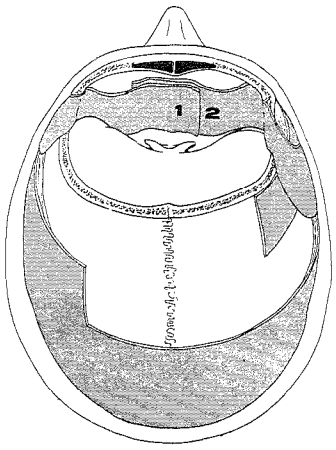

(Fig - 2b) The two pericranial flaps from both sides are harvested and rotated along with the temporalis muscle towards the defect in the anterior skull base one over the other forming a multilayer reconstruction.

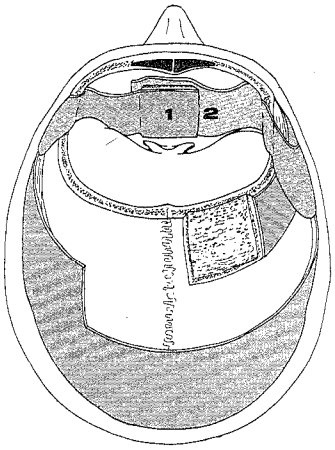

(Fig - 2c) Line drawing showing the incisions over the pericranial layer. Bifrontal craniotomy is seen. Note that the skull bone is split on the right side and is rotated along with the pericranium to form a vascularized pedicled bone flap.

Muscle - Fascia Flaps

The deep temporal fascia can be everted over the muscle maintaining its attachment and thereby preserving its vascularity. This type of composite flap can be used for reconstruction of a basal defect in the middle cranial fossa and mastoidectomy cavities (Fig.3) It could also be folded for added bulk. This would be useful especially in the presence of infection.

Subgaleal Flaps

Subgaleal fascia can be used as a flap in itself. This layer, known previously as 'loose areolar tissue layer' of scalp has now been shown to have

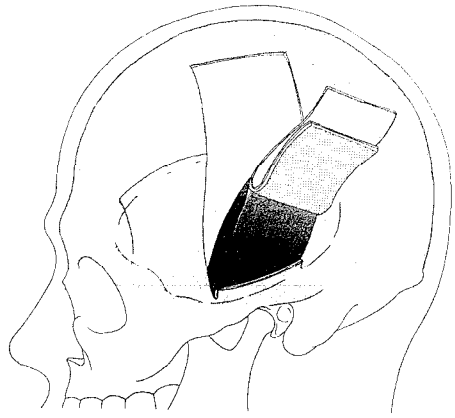

(Fig - 3) The superficial and deep layers of the temporalis fascia are cut at the base and reflected superiorly. This thickens the peripheral part of the flap.

an independent and extensive blood supply entering into it at the base of the cranial vault circumferentially. Casanova et al called the same layer as innominate fascia[4]. It is a thin but well defined trilaminar fibrous structure and a discretely separable layer. Superficial temporal artery and its branches which supply the galea also give many minute branches to subgaleal fascia which is closely approximated to the pericranial layer.

Since the subgaleal fascia has multiple sources of blood supply, it is possible to design a flap using this layer alone[5]. Also an attempt to preserve this layer during the elevation of long pericranial flaps would contribute to a better blood supply and greater chances of survival, especially when the flap is taken beyond the midline.

Dura

Cranial dura is formed by two layers - the outer endosteal layer and the inner meningeal layer. These layers are well defined and separable by manual dissection, particularly in younger individuals. The dura is supplied by multiple small and medium sized arteries circumferentially. The meningeal blood vessels are largely located in the endosteal layer. When preserved intact the outer endosteal layer can be rotated and used to cover defects in the proximity. The principle advantage of using such a material is that it may be used as a vascularized pedicle flap or a free graft. The consistency and quality of the material matches with that of adjacent dura. Local availability and ease of rotation of this flap are the other advantages. Despite the limitations in using this flap due to technical difficulties in separating the layers, it can be useful in an occasional situation[6].

B. BONY RECONSTRUCTION

Reconstruction of bone defects following skull base surgery is a controversial subject. All bone defects do not require reconstruction. The questions of cosmesis, arthrodesis and stability are not applicable in basal reconstruction. The main purpose of reconstructing bone defects is to avoid possible herniation of the brain matter into the aerodigestive tracts, ear, orbit, or in the space resulting following a large tumor resection or after treating basal encephalocele. Possibility of such an eventuality is rare and the decision regarding reconstruction of basal bone should be a calculated one. In the presence of intact basal dura, even large bone defects can be tolerated without any consequence. One third to half of the orbital roof can be removed without any problem of pulsating exophthalmos. Large clival, petrous and sphenoid bone defects can safely be left unrepaired. Often it is safer not to perform bone reconstruction at the end of a long surgical procedure for the fear of infection, consequently complicating the entire surgical procedure. In sterile fields free bone grafts are appropriate. However, in potentially infective fields, use of a bone flap based on a vascularized pedicle is recommended. Vascularized bone flaps remain viable and are characterized by normal bone healing while free bone grafts have a greater incidence of necrosis and resorption.

Osteomyoplastic Flap

This term refers to the incorporation of a segment of vascularized bone in a muscle flap such as the temporalis muscle. When osteomyoplastic flaps are used[7,8], the initial incisions must be planned in

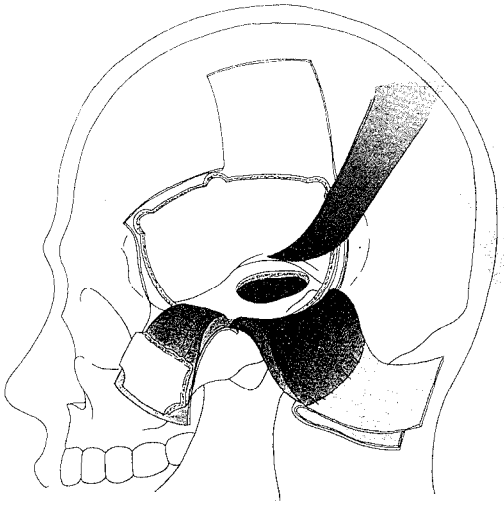

(Fig - 4a) Drawing shows the anterior half of the flap is an osteomyoplastic flap (secondary flap) while the posterior half of the flap is a long vascularized pedicled temporalis muscle-pericranial flap (primary flap). The temporal brain is retracted to expose the middle fossa bone defect.

such a way as to avoid transecting the blood supply of the temporalis muscle. Either split or full thickness cranial bone can be used. The temporalis muscle lends itself well to reconstruction of middle fossa and petrous bone defects. (Figs 4a,b,c).

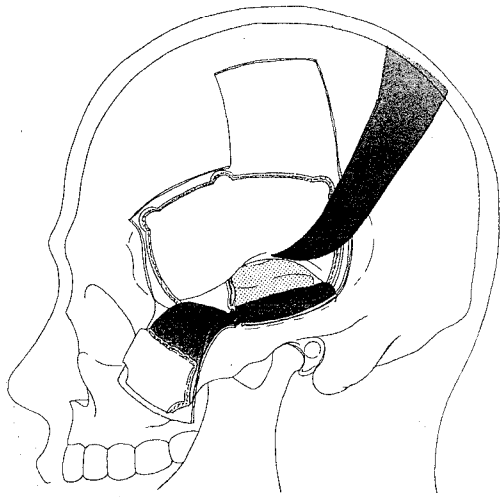

(Fig - 4b) The primary flap is rotated first towards the **middle fossa floor defect.**

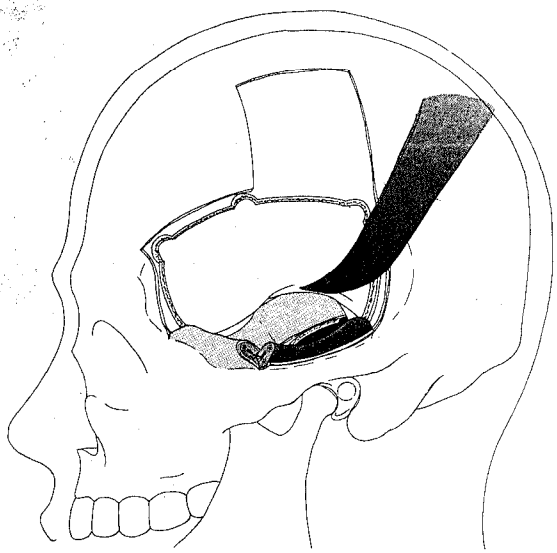

(Fig - 4c) The secondary osteomyoplastic flap is then rotated so that it lies on the previously laid primary flap. This results in the formation of multilayer construct with vascularized pedicle flaps.

Pericranium Based Bone Flaps

Bone flaps of the calvarium pedicled on pericranium or galea (osteo-galeopericranial flap), have been described for reconstruction of craniofacial deformities[9]. The same principle can be readily utilised for skull base reconstruction in the anterior cranial fossa (Fig 5a,b). Whenever necessary,the bone can be placed in such a way that it is not directly exposed to the paranasal sinuses. It can even be sandwitched between the pericranial layers (Fig 2c). The bone may have to be fractured into

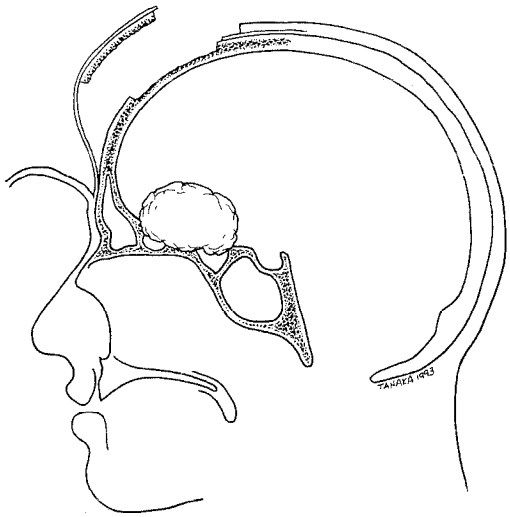

(Fig - 5a) Line drawing showing an anterior cranial basal tumor. A split thickness calvarial graft pedicled on galeo-pericranial layer is taken.

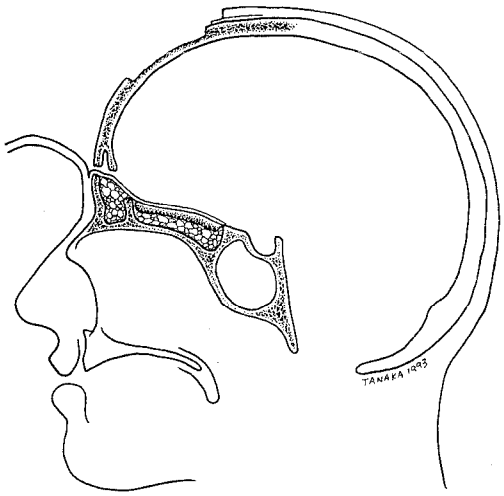

(Fig - 5b) Drawing shows the tumor has been resected. The bone graft is placed in the resultant basal defect. Fat occupies the opened sinuses.

two or more pieces retaining its attachment to the pericranium so that contour can be adjusted to suit the local environment. Such flaps would be ideal for treating basal encephaloceles[10].

Composite Cranial Flaps

The temporalis muscle with its overlying fascial layers and pericranium can be retained with the outer table of the skull (Fig 6a,b) enhancing the vascularity and length of the flap. The skull bone is thicker superior to the temporal line which marks the attachment of the temporalis muscle. Splitting of the skull bone is easier in the paramedian parietal bone due to the well formed diploic channels. The fascial layers covering the temporalis muscle can be used to seal the defects in the basal dura while the muscle and bone occupy the area of bone defect[11].

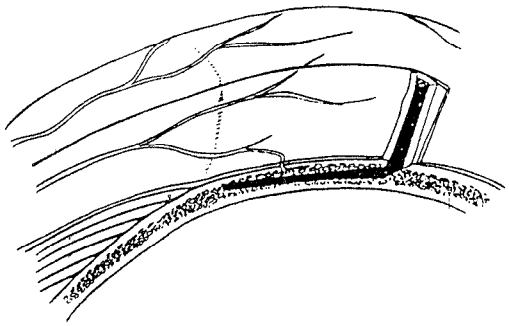

(Fig - 6a) Drawing shows splitting of the cranial bone. The bone flap is being elevated along the pericranium. The temporalis muscle and its fascial envelope form the pedicle of the flap.

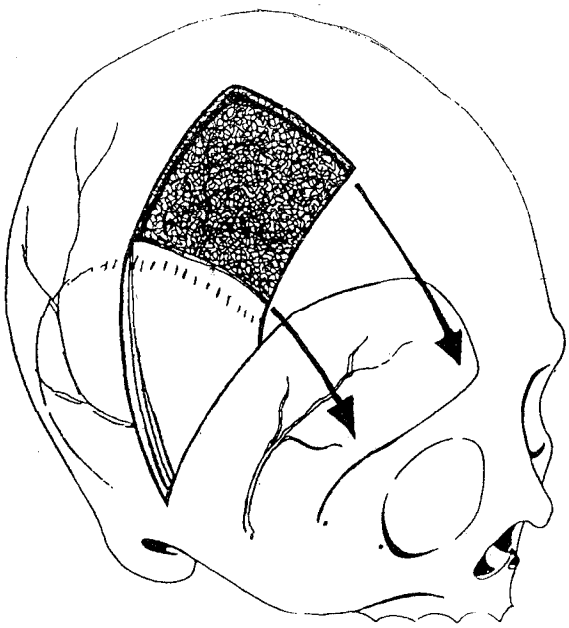

(Fig - 6b) Drawing shows how the described flap will be cut along the bold lines and rotated in the direction of the arrow towards the site of skull defect. The temporalis muscle has been split vertically.

Use of Bone Dust and Debris

When craniotomies are performed using modern craniotomes, a large amount of bone dust is obtained. The bone dust can be flattened and placed in the form of a sheet over the site of defect. Small bone chips which are generally available during a craniotomy can be placed interspersed in the bone dust. This forms a template over which new bone and fibrous tissue is laid.

Temporary Subgaleal Preservation of Bone

Various techniques of heterotopic preservation of bone have been described both inside and outside the body. The subgaleal plane adjacent to the site of operation could be used for the same purpose quite effectively. This space is exposed widely by blunt dissection and the bone is placed in it taking care that the curvature of the bone does not excessively elevate the scalp or cause tension. The bone is replaced to the original site or where it is needed as early as possible[12].

C. MULTI-LAYERED RECONSTRUCTION

Utilising a combination of the above described techniques, it is possible to reconstruct all layers of a composite cranial base defect[13]. Two methods of multi-layered reconstruction have already been illustrated in Fig 2&4. Temporal bone defects resulting due to basal rotation can be reconstructed with split cranial bone grafts in the classical manner.

CONCLUSION

The neurosurgeon and plastic surgeon working together as a team can effectively use the techniques outlined above to cover defects of the skull base. This would prevent brain herniation,post-surgical CSF fistula and reduce infection in skull base surgery.

References

1. **Tolhurst D E, Carstens M H, Greco R J and Hurwitz D J.** The surgical anatomy of the scalp. Plast Reconstr Surg 1991; 87:603-612.
2. **Nakajima H, Imanishi N and Minabe T.** The arterial anatomy of the temporal region and the vascular basis of various temporal flaps. Br J Plast Surg 1995; 48:439-450.
3. **Antonyshyn O, Gruss J S and Birt B D.** Versatility of temporal muscle and fascial flaps. Br J Plast Surg 1988; 41: 118-131.
4. **Casanova R, Cavalcante D and Grotting J C.** Anatomic basis for vascularized outer-table calvarial bone flaps. Plast Reconstr Surg 1986; 78:300-308.
5. **Carstens M H, Greco R J, Hurwitz D J and Tolhurst D E.** Clinical appliations of the subgaleal fascia. Plast Reconstr Surg 1991; 87:615-626.
6. **Goel A.** Use of outer layer of dura as a pedicled flap. Surgical neurology 1995; 44:92-93.
7. **Goel A.** Vascularised osteomyoplastic flap for skull base reconstruction. Br J of Neurosurgery 1994; 8:79-82.
8. **Cutting C B,McCarthy JG,Bernstein A.** Blood supply of the upper craniofacial skeleton: the search for a composite calvarial bone flap. Plast Reconstr Surg 1984;74:603-610.
9. **Jackson I T, Adam M N,Marsh WK.** Use of the galeal frontalis myofascial flap in craniofacial surgery. Plast Reconstr Surg 1986; 77:905-910.
10. **Goel A,Gahankari D.** Extended subgaleal fascia-pericranial temporalis flap for skull base reconstruction. Acta Neurochirurgica (Wien) 1995; 135:203-205.

11. **Goel A.** Split Calvarial Osteoplastic Flap. Journal of Neurosurgery. 1995; 82:150-151.

12. **Goel A.** Subgaleal preservation of the calvarial bone flap. Surgical Neurology 1995; 44:161-168.

13. **Goel A.** Mutli layered vascularized pedicle reconstruction of the middle cranial fossa. Acta Neurochirurgica. 1996; 138: 580-588.

Author

Dr.Atul Goel, M Ch., Associate Professor

Department of Neurosurgery, Seth G.S. Medical College and K.E.M.Hospital, Bombay

Request for reprints to Dr.Atul Goel,Department of Neurosurgery,Seth G.S.Medical College and K.E.M.Hospital,Parel,Bombay 400 012.