

Reconstruction Of Thumb By Distraction - A Case Report

Dr. P.K. Sharma, M.Ch.(Plastic Surgery)
Dr. K.K. Verma, M.B.B.S., Resident
Dr. O.P. Sharma, M.S.
Dr. A. Malhotra, M.S.

* Presented at XXVII National Conference Association of Plastic Surgeons of India in September 1992, at Bombay.

KEY WORDS

Sub. periosteal Osteogenesis Thumb stump lengthening.

ABSTRACT

A Simple, excellent, practical & effective method of Reconstruction of thumb is described in this distraction technique. Reconstructed thumb is of near normal, colour, texture, sensation, stability, aesthetics, and function wise.

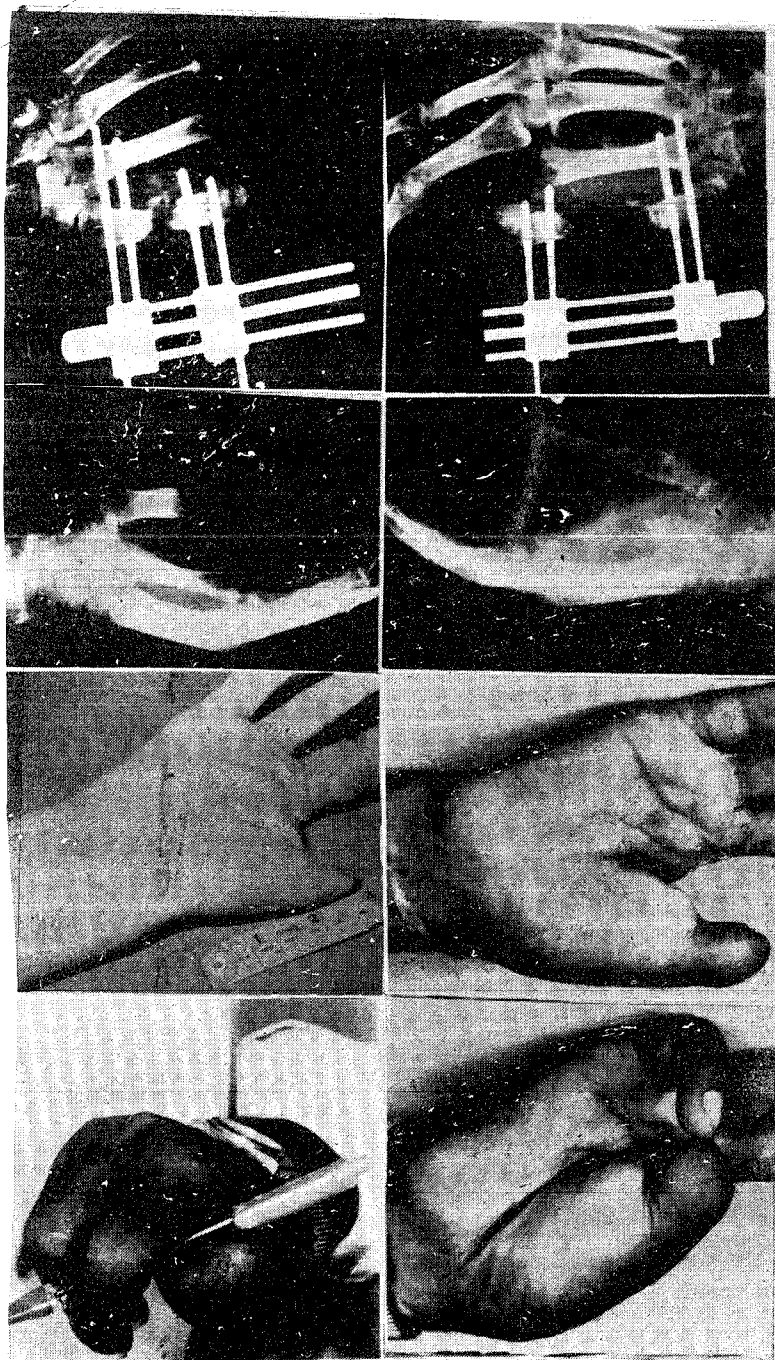
INTRODUCTION

The loss of thumb produces aesthetic and functional problems where grasp and pinch both functions are affected. Various methods like osteoplastic technique, Policization, Toe transfers etc. are currently in vogue. First metacarpal lengthening by distraction, is performed in the present case.

CASE REPORT

A twenty six year old male patient with Traumatic amputated stump right thumb at the base of proximal phalanx, reported to our unit.

A small longitudinal incision over the dorsum of the right metacarpal was made. Four K wires (2.5 mm diameter) were placed transversely across the bone proximal and distal to the site of osteotomy. A transverse sub. periosteal osteotomy was completed in the mid portion of the shaft. The wound was closed and external fixator distraction apparatus applied to K wires. It consist of two metallic blocks connected by two guide pins and one threaded shaft. Each block has two transverse holes to adjust 2.5 mm. screws. A central screw is used for distraction. Anticlockwise one round distracts one mm. After 7 days, distraction of 0.5 mm. a day was started for a week. After a gap of two weeks, distraction 1 mm a day started till 4 cm lengthening. Postoperatively, function was near normal.



Skiagram Showing :

1. Ext. Fixator Distractor Apparatus Applied to k Wires and Transverse Osteotomy.
2. Metacarpal Lengthening with Distractor Apparatus.
3. Pre-Op. Amputated Stump.
4. Bone Consolidation After Lengthening.

Figures :

5. Pre Op. Stump Length.
6. Post Op. Lengthening.
7. Pinch Action Rt. Thumb.
8. Opponens Action.

TABLE

Period	Per day lengthening	Total length achieved.
1st week	No distraction	-
2nd week	0.5 mm	3.5 mm
3rd & 4th week	No distraction	-
5th to 9th week	1 mm	35 mm
9 weeks		38.5 mm

DISCUSSION

Prerequisite for a metacarpal lengthening is, atleast 2/3rd metacarpal length with good skin and no scar in first web space. During the gain in length, spontaneous bone consolidation takes

place because of periosteum. Careful monitoring of distraction give excellent results. Blanching and pain are limitations for distraction. Neurovascular bundle can withstand continuous stretching without neuropraxis.

The known complications of pin migration, Pin loosening, Infection, nonunion, necrosis, Distal skin slough, Rotation, angulation of metacarpal were not encountered in this case.

The resultant elongated first metacarpal unit was sensitive, stable, had original blood supply, minimal scar and presented aesthetic, near normal anatomy and physiology. Technique is simple, single staged, reliable and with minimum complications. But lengthening is a slow process.

Matev (1967) reported first metacarpal lengthening. Other authors also reported i.e. Kessler (1976), Corven (1980) and Benhur (1980).

This procedure can also be used for Clinodactyly, Palm shortening and Thumb hypoplasia etc. This procedure with experience, may prove to be primary reconstruction consideration in this area.

REFERENCES

1. Kessler, L., Hecht, and Baruch, A : Distraction lengthening of digital rays in the management of the injured hand. J. Bone Joint Surg; 1979; 61 A : 83 - 87.
2. Matev, I.B. : Thumb reconstruction through metacarpal lengthening. J. Hand Surg., 1980; 5 : 482-487.
3. Matev, I.B. : Thumb reconstruction after amputation at the Metacarpophalangeal joint by bone lengthening. A preliminary report of three cases. Plast, Reconstr. Surg. 1970 ; 52 A : 957- 965.
4. Matev, I.B. : Thumb reconstruction in children through Metacarpal lengthening. Plast. Reconstr. Surg. 1979; 64 : 665.

Author's Name And Address

1. Dr. P.K. Sharma, M.Ch. (Plastic Surgery), Reader,
2. Dr. K.K. Verma, M.B.B.S., Resident.
3. Dr. O.P. Sharma, M.S.,
Professor and Head,
4. Dr. A. Malhotra, M.S., Reader,
Department of Orthopaedics Surgery.

Plastic Surgery Unit,
Gandhi Medical College,
Bhopal - 462 001 (MP)