

Chin Augmentation In Temporomandibular Ankylosis

Dr. J.K. Sinha, M.S., F.R.C.S.
Dr. K.K. Mangal, M.S., M.Ch.

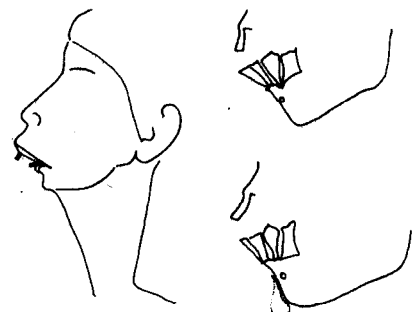
KEY WORDS

Microgenia, Chin retrusion.

ABSTRACT

In T.M. Joint ankylosis cases post operatively, normal facial contour and profile cannot be achieved although trismus is relieved. Development of mandible and facial skeleton by puberty exaggerate this problem. Not only is there chin retrusion, wide lip separation, there are also problems related to obliquely placed protruding upper and lower incisor and canines, in need of further treatment. Chin augmentation at puberty by sialastic implant, to bring about normal chin appearance and face profile is discussed.

Sketches



Sketches Showing:

1. Chin Retrusion, Lip Separation, Protruding Teeth.
 2. Pre-Operative Profile View.
 3. Placement of Sialastic Implant.
-

INTRODUCTION

Microgenia or retruded chin is a problem which may be primary - Due to maldevelopment or secondary to excision of local lesions. Primary i.e. developmental microgenia amongst the two is usually more severe deformity and needs correction. Etiologically there are many factors which lead to arrest of development i.e. trauma in childhood, infection in T.M. joints in childhood, etc. are some of them. The end result is T.M. joint ankylosis, resulting in trismus, in need of release.

CASE REPORTS

Two 17 year old female patients presented with small and retracted chin. They were successfully operated for bilateral T.M. joint ankylosis approximately ten years earlier to relieve trismus.

TREATMENT :

Under general anaesthesia with endotracheal intubation a horizontal incision is made from one angle of the mouth to the other on the lower lip on mucosal surface 2 cms. away from gingivolabial sulcus. This is deepened taking due care not to injure the two nerves emerging from the mental foramina till mandible is fully exposed. Periosteum is then separated and a correct size sialastic implant is subperiosteally placed to achieve desired results. Implant is then fixed to chin by drilling two holes into the mandible, and 2, 0 prolene sutures to tie. Closure of the mucosal incision is done with 3, 0 Chromic catgut.

DISCUSSION :

There are many ways to correct this deformity. Allopathic implants, Advancement osteotomies, Autogenous onlay grafts of bone or cartilage, and skin graft inlays and external prosthesis. Advancement osteotomies are a complicated and complex procedures which need experience, precision, instruments and careful followup. When autogenous grafts are used, there is problem of irregular absorption leading to irregularity in chin contour which may necessitates revision. Inlay grafting and external prosthesis demand continuous care and are cumbersome.

Allopathy implants when used for augmentation have many advantage. It avoids operation on other body area for harvesting donor material. Migration of implant can be adequately prevented by fixing it to bone. Subperiosteal placement of implant avoids bone reabsorption.

CONCLUSION

Long term results are satisfactory and implanted material helps substantially to improve face appearance in profile.

REFERENCES :

1. Mc Carthy J.G., Kawamoto H., Grayson G.H., Colen S.R., Cocco P.J., Wood-smith D.: Surgery of the Jaws : Plastic Surgery volume 2, edited by Mc Carthy J.G., May J.W., Littler J.W., W.B. Saunders Company 1990.
2. Aston S.J. Thorne C.H.M.: Aesthetic Surgery of the Aging face. Erabb and Smith's Plastic Surgery edited by Smith, J.W., Aston S.J., Little Brown and Company fourth edition 1991.
3. PITANGUY I Augmentation mentoplasty Plastic & Reconstruction Surgery 42 : 460, 1968.

AUTHOR'S NAME AND ADDRESS:

1. Dr. J.K. Sinha, M.S., F.R.C.S.,
Professor & Head.
2. Dr. K.K. Mangal, M.S., M.Ch, Senior Resident.

Division of Plastic Surgery,
Institute of Medical Sciences,
Banaras Hindu University, VARANASI.