

Interposing Prolene Mesh Repair For Upper Abdominal Wall Defects.

Dr. Hosi M. Bhatena, M.S., M.S., M.Ch.
Dr. Naozer M. Kavarana, M.S.

KEY WORDS

Rectus abdominis
Deficit

ABSTRACT

Dermatofibrosarcoma, Supra umbilical excisional defect with a deficit of 4 cms. of left rectus abdominis was repaired. Results are presented.

INTRODUCTION

Maintenance of the integrity of the anterior abdominal wall following reconstruction of postexcisional defects resulting from tumors, trauma, infection and radionecrosis of anterior abdominal wall cause major problem in reconstruction. Shortening of peritoneal, posterior rectus sheath rectus muscle or other muscles of anterior abdominal wall are often removed during the procedure. These leads to ventral hernia, burst abdomen or generalised peritonitis as complication. Reconstructive Surgeon has to take into account all these possibilities prior to reconstruction. The upper abdominal wall defects need to be reconstructed using flaps of rectus sheath and external oblique muscle/aponeurosis; while the lower abdominal weakened donar site is repaired with other alternatives like tensor fascia lata or other modalities flaps.

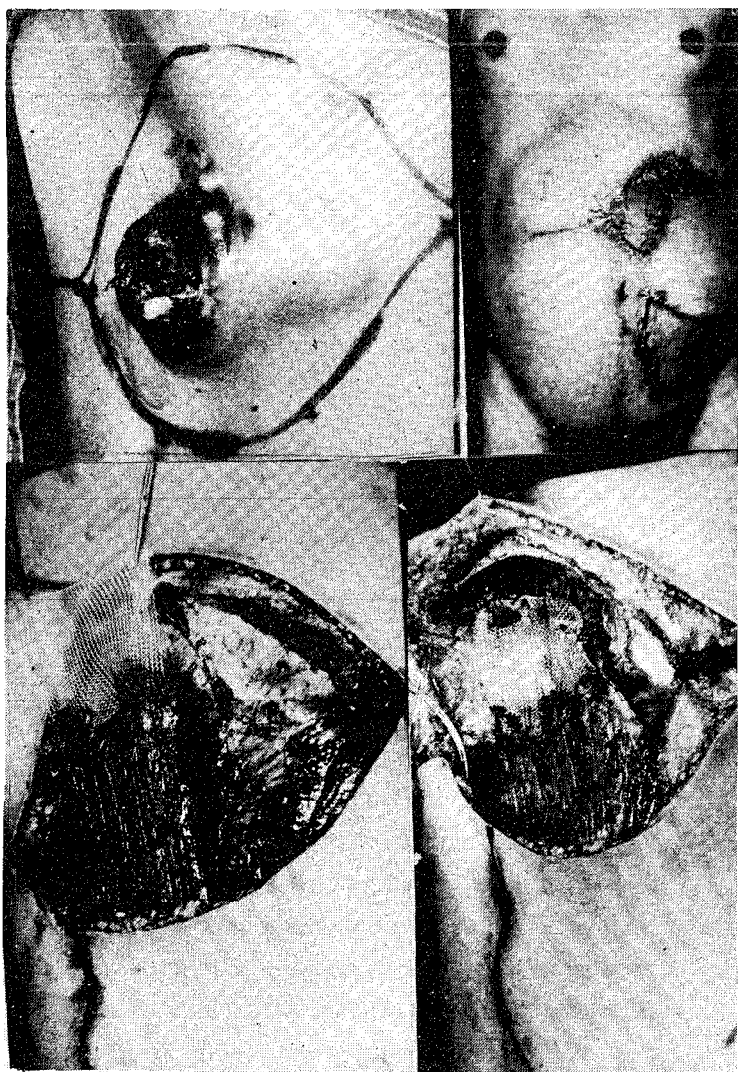
Microvascular free tissue transfer has been used for the anterior abdominal wall reconstruction, but it has its own limitations. (Caffee 1983)

A case in which prolene mesh was utilized for rectus abdominis deficit and transportation of skin flap for skin cover is being presented.

CASE REPORT

A moderately built 50 year old male presented with a protruberent fungating mass in the left hypochondrial region, with foul smelling discharge and occasional episodes of bleeding of one year's duration. He gave a history of trauma to the local site 30 years ago, resulting in skin discoloration lasting for two to three years. On examination, 6 cm x 5 cm bosselated firm to hard mass, with ulceration of the skin overlying the tumour in connection with the rectus muscle was found. The histopathology was dermatofibrosarcoma protruberance.

Photographs 1-4



Figures :

1. Abdominal Wall Tumour with Markings For Skin Flap.
2. Post-Operatively After 9 Months.
3. Post Excisional Defect of Left Rectus and Prolene Mesh Being Applied.
4. Prolene Mesh Sutured to the Muscle Stump.

OPERATION

Under general anaesthesia, exploration revealed tumor infiltration of the left rectus and external oblique muscles, with an intact posterior rectus sheath and peritoneum. The postexcisional defect consisted of a left rectus muscle of 8 cm length, anterior rectus sheath and a skin ellipse of 15 cm x 11 cm. The rectus muscle was mobilised in its sheath by dividing the intersegmental attachments upto the level of the umbilicus. Thus the rectus muscle was advanced without hampering the segmental neurovascular supply to the muscle, resulting in a deficiency of 4 cm. length. This defect was interposed by double layers of prolene mesh using prolene sutures. A local random pattern skin flap was elevated and transposed to cover the skin defect in conjunction with a split skin graft. The donor site was repaired with split skin grafting.

DISCUSSION

Reconstruction of the abdominal wall entails repair of the musculature and the skin. Preservation of the rectus abdominis muscle remnant along with the segmental neurovascular supply whenever possible is very important during excision of abdominal wall tumours. Mobilisation of the rectus muscle within the rectus sheath by dividing the intersegmental attachments without severing the segmental neurovascular supply is necessary. Prolene mesh or other alloplastic implant or fascia can be used to bridge defects in the musculature to restore the normal anatomy. This mesh provides a new attachment for the healthy functioning rectus muscle to work, especially when the segmental neurovascular bundles are preserved.

This case is presented because of the success achieved.

REFERENCES :

1. Caffee, HH. (1983) Reconstruction of the abdominal wall by variations of the tensor fascia lata flap. *Plast Reconstr. Surg.* 71 : 348-351.
2. Prakash, S. (1988). Bilateral turn-table rectus abdominis myocutaneous flaps for an upper abdominal recurrent dermatofibrosarcoma. *British Journal of Plastic Surgery*, 41 : 322-324.

AUTHOR'S NAME AND ADDRESS :

1. Dr. Hosi M. Bhatena, M.S. M.S., M.Ch.,
2. Dr. N.M. Kavarana, M.S., Chief Plastic and Reconstructive Surgeon.

Plastic and reconstruction Surgery Department,
Tata Memorial Hospital and Center,
Bombay.