



Cinematic Rendering of Persistent Fifth Aortic Arch with Aortic Coarctation and Bicuspid Aortic Valve

Karamkar Deepmala¹ Jineesh Valakkada¹ Anoop Ayappan¹ Basavaraj Birardar¹

¹Department of Imaging Sciences and Interventional Radiology, Sreechitra institute of Medical Sciences and Technology, Trivandrum, Kerala, India

Address for correspondence Jineesh Valakkada, MD, Department of Imaging Sciences and Interventional Radiology, Sreechitra Institute of Medical Sciences and Technology, Trivandrum 695011, Kerala, India (e-mail: jineesh174@gmail.com).

Indian J Radiol Imaging 2024;34:193–195.

Congenital cardiovascular lesions can be complex and perplexing to diagnose even with multiple imaging and post-processing modalities. Herein, we present a case of persistent fifth aortic arch (PFAA) with coarctation of aorta emphasizing role of computed tomography (CT) cinematic rendering to simplify the complex anatomy

A 19-year-old male adolescent patient presented with gradually progressive chest pain and exertional dyspnea over 6 months with bilateral lower limb claudication pain. On palpation, femoral pulses were feeble bilaterally. There was differential systolic blood pressure of 70 mm Hg between the upper and lower limbs. Echocardiogram showed a bicuspid aortic valve (BAV) with juxtaductal coarctation of aorta with a systolic gradient of 63 mm Hg. Cinematic rendering of CT angiogram revealed a common arterial trunk arising from the distal ascending aorta, giving rise to all the arch vessels (►Video 1). The aortic arch was low-placed and in a horizontal orientation (►Fig. 1) with BAV and a nondilated aortic root (►Fig. 2). The coarcted segment measured 4 mm in diameter. Multiple collaterals were seen in the paravertebral region. In view of the limb claudication and significant aortic gradient and outpouching, he underwent successful percutaneous stent graft of the coarctation of aorta. Postprocedure period was uneventful with follow-up at 1 year showing improvement in symptoms

Video 1

Cinematic rendering of the aortic arch showing the origin of the arch vessels and coarctation of aorta. AA,

aortic arch; BCA, brachiocephalic artery; CCA, common carotid artery; DTA, descending aorta; LSA, left subclavian artery; PFAA, persistent fifth aortic arch; RT, right. Online content including video sequences viewable at: <https://www.thieme-connect.com/products/ejournals/html/10.1055/s-0043-1775798>.

PFAA is an extrapericardial vessel arising from ascending aorta proximal to the origin of brachiocephalic arteries, terminating either in the dorsal aorta or in the pulmonary arteries via the persistently patent arterial duct.¹ It is a rare congenital cardiovascular malformation occurring in almost 1 of 330 autopsy studies.² It is believed to originate from the failed degeneration of the fifth pharyngeal aortic arch during embryogenesis.³ Freedom et al defined four different subtypes based on anatomical and physiological characteristics (►Table 1).⁴ Echocardiography can show the low-lying fifth arch in some cases, especially in children.⁵ In our case (type 1 Freedom PFAA), there was a limited acoustic window since our patient was an adolescent, hence cross-sectional imaging was called for.

Magnetic resonance imaging or CT is the preferred imaging modality to accurately diagnose PFAA.⁶ A single trunk from which all the aortic arch vessels originate and the relatively low horizontal position of the so-called “aortic arch” helps to rule in the diagnosis. Patent ductus arteriosus (PDA) and aortopulmonary (AP) window can mimic PFAA. PDA arises distal to the origin of brachiocephalic artery and is extrapericardial. In AP window, there is a septation defect between the most proximal

article published online
October 13, 2023

DOI <https://doi.org/10.1055/s-0043-1775798>.
ISSN 0971-3026.

© 2023. Indian Radiological Association. All rights reserved.
This is an open access article published by Thieme under the terms of the Creative Commons Attribution-NonDerivative-NonCommercial-License, permitting copying and reproduction so long as the original work is given appropriate credit. Contents may not be used for commercial purposes, or adapted, remixed, transformed or built upon. (<https://creativecommons.org/licenses/by-nc-nd/4.0/>)
Thieme Medical and Scientific Publishers Pvt. Ltd., A-12, 2nd Floor, Sector 2, Noida-201301 UP, India

Table 1 The Freedom classification of PFAA

Classification	Connection	Association
Type 1	Systemic-to-systemic	Interrupted aortic arch or coarctation of the aorta
Type 2	Systemic-to-pulmonary	Right-sided obstructive lesions
Type 3 (rare)	Pulmonary-to-systemic	Left-sided obstructive lesions
Type 4 (rare)	Bilateral	Bilateral PFAAs of any type

Abbreviation: PFAA, persistent fifth aortic arch.

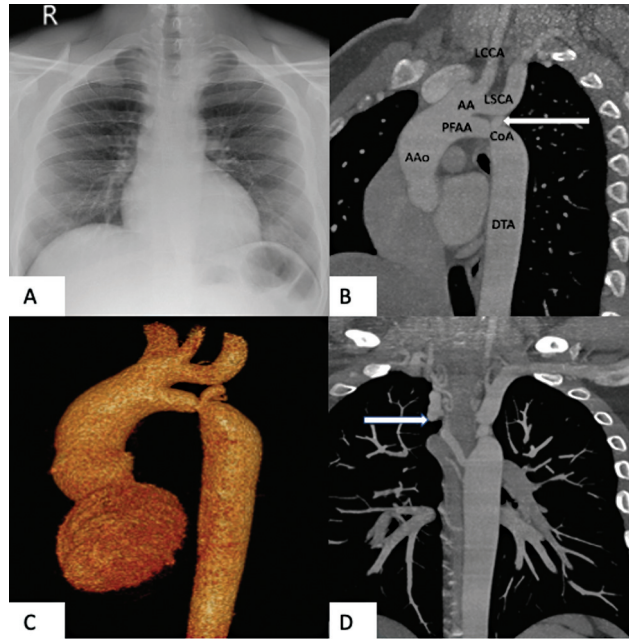


Fig. 1 (A) Chest radiograph at the time of presentation reveals normal cardiac silhouette and lung fields. (B) Computed tomography (CT) maximum intensity projection in the sagittal oblique plane shows the single vessel from ascending aorta giving rise to the head and neck vessels, while the lower lumen with no branching represents the persistent fifth aortic arch (PFAA). Also shown is the coarctation of distal PFAA with adjacent saccular outpouching (white arrow) better visualized in Volume reconstructed images (C). There are multiple intercostal collaterals suggestive of significant coarctation (D). Aao, ascending aorta; AA, aortic arch; CoA, coarctation of aorta; DTA, descending aorta; LCCA, left common carotid artery; LSCA, left subclavian artery. Three-dimensional reconstruction (B) from the CT angiography showing similar findings.

portion of the aorta and the pulmonary trunk and septation is typically intrapericardial.⁷

CT cinematic rendering can provide valuable inputs in cases of complex congenital heart diseases. Cinematic rendering involves propagation of billions of light rays through the voxels and their interaction with the volume to generate a single pixel, while volume rendering uses one light ray per pixel.⁸ It uses complex high dynamic range rendering maps for creating a natural lighting environment resulting in a more realistic three-dimensional image as opposed to the synthetic light source of volume rendering helping in better detection of these lesions. Accurate diagnosis and characterization of PFAA were

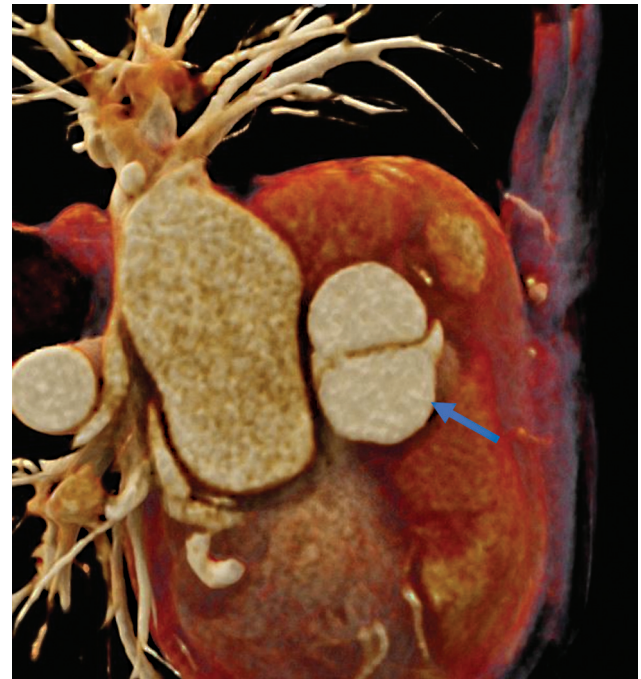


Fig. 2 Computed tomographic cinematic rendering showing bicuspid aortic valve (arrows).

in our cases for the treatment because of the associated narrowing of the aortic arch. In short, CT cinematic rendering may work in future as a better post-processing tools for delineating of such complex anatomies

Conflict of Interest

None declared.

References

- Gupta SK, Gulati GS, Anderson RH. Clarifying the anatomy of the fifth arch artery. *Ann Pediatr Cardiol* 2016;9(01):62–67
- Gerlis LM, Ho SY, Anderson RH, Da Costa P. Persistent 5th aortic arch—a great pretender: three new covert cases. *Int J Cardiol* 1989; 23(02):239–247
- Liu Y, Zhang H, Ren J, et al. Persistent fifth aortic arch: a single-center experience, case series. *Transl Pediatr* 2021;10(06): 1566–1572
- Freedom RM, Yoo S-J, Mikailian H, Williams WG. *The Natural and Modified History of Congenital Heart Disease*. New York, NY: Wiley-Blackwell; 2008

- 5 Bernheimer J, Friedberg M, Chan F, Silverman N. Echocardiographic diagnosis of persistent fifth aortic arch. *Echocardiography* 2007;24(03):258–262
- 6 Kim CH, Kim H, Choi KH, Sung SC, Ko H, Choo KS. Persistent fifth aortic arch associated with aortic coarctation: a case of surgical correction without artificial material. *J Cardiothorac Surg* 2021;16(01):281
- 7 Lloyd DFA, Ho SY, Pushparajah K, et al. Persistent fifth aortic arch: the “great pretender” in clinical practice. *Cardiol Young* 2018;28(02):175–181
- 8 Eid M, De Cecco CN, Nance JW Jr, et al. Cinematic rendering in CT: a novel, lifelike 3D visualization technique. *Am J Roentgenol* 2017;209(02):370–379