


An Unusual Presentation of Accidental Rectal Corrosive Injury

Maitrey Patel¹ Rushil Solanki¹ Radhika Chavan¹  Sanjay Rajput¹

¹Department of Gastroenterology and Endoscopy, Ansh Clinic, Maninagar, Ahmedabad, Gujarat, India

Address for correspondence Maitrey Patel, DNB, Ansh Clinic, A-1, Jaisinghbhai Park Hirabhai Tower, Nirant Cross Rd, near Divine Buds School, Uttamnagar, Maninagar, Ahmedabad, Gujarat 380008, India (e-mail: ptlmaitrey@gmail.com).

J Digest Endosc 2023;14:179–180.

Abstract

Rectal corrosive injuries occur rarely among adult patients and are confined to suicidal patients and cases of homicide. These injuries are less frequently accidental. No reports of rectal corrosive injury have been reported in the literature to date. In this study, we report an unusual presentation of a very rare case of accidental rectal corrosive injury.

Keywords

- ▶ accidental corrosive
- ▶ lower GI bleed
- ▶ colonoscopy

Background

Intrarectal injection of caustic material is uncommon and is usually done with intent of suicide or homicide, or as a part of therapy by some tribes. In some cases, it can be accidental. The severity of such caustic injury ranges from mild mucosal congestion to complete necrosis of the rectum and colon, leading to perforation.¹ Limited data are available on rectal caustic injury because of its rare presentation. In this study, we report an unusual case of accidental corrosive injury of the rectum.

Case Report

A 68-year-old woman presented with tenesmus and bleeding per rectum for 5 days. General and systemic examination was within normal limits. Evaluation showed moderate anemia (hemoglobin 9 g/dL) with raised erythrocyte sedimentation rate (40 mm/h). On per rectum examination, soft friable edematous mucosa with bleeding was noticed in the anal and perianal region. She underwent colonoscopy and it showed circumferential superficial to deep ulceration, mucosal edema, friability, and spontaneous oozing of blood

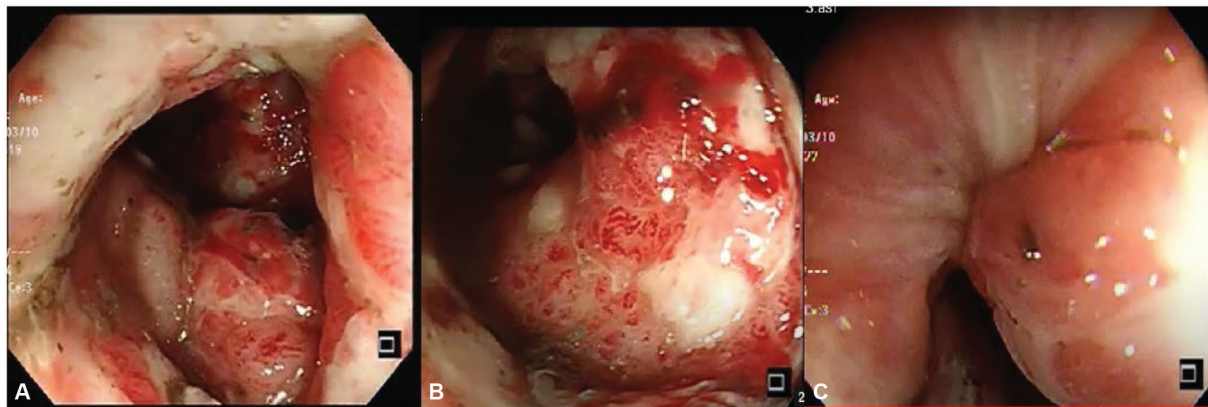


Fig. 1 (A,B) Ulcerated colonic mucosa with minimal ooze. (C) Edematous anorectum mucosa.

DOI <https://doi.org/10.1055/s-0043-1775852>.
ISSN 0976-5042.

© 2023. The Author(s).

This is an open access article published by Thieme under the terms of the Creative Commons Attribution License, permitting unrestricted use, distribution, and reproduction so long as the original work is properly cited. (<https://creativecommons.org/licenses/by/4.0/>)
Thieme Medical and Scientific Publishers Pvt. Ltd., A-12, 2nd Floor, Sector 2, Noida-201301 UP, India

(►Fig. 1A and 1B) from the friable mucosa in the anorectal region and distal rectum (up to 3–4 cm; ►Fig. 1C). The rest of the colon examination was normal. Due to diagnostic dilemma, relatives were called in to obtain the history once again. At that time, it was revealed that the patient had accidentally used toilet cleaner instead of water while cleaning the anal region, and these symptoms started developing after that incident. She was hospitalized and treated with intravenous antibiotics, fluids, and steroids. With this treatment, her symptoms improved within 3 days. However, she died of sudden cardiac arrest at home after 1 week.

Conclusion

Rectal and colonic caustic injuries are uncommon and may go unrecognized.² Careful examination and detail

history can help in identification of such injuries. The patient can be managed conservatively in the absence of peritonitis.

Funding

None.

Conflict of Interest

None declared.

References

- 1 Saliba T, Tack D. A caustic hydrochloric acid enema: a case report. *Cureus* 2023;15(02):e35394
- 2 Diarra B, Roudie J, Ehua Somian F, Coulibaly A. Caustic burns of rectum and colon in emergencies. *Am J Surg* 2004;187(06):785–789