



USE OF LIMBERG FLAP FOR CLOSURE OF SACRAL PRESSURE SORES

Avtar Singh, K S Mander, G P Singh, S K Gulati, Gopal Malhotra, K C Garg and J P S Walia
Government Medical College & Rajendra Hospital, Patiala

SUMMARY : *Limberg flap has been used for the closure of moderate size sacral pressure sores in 5 cases. It provides a good padded skin cover with the suture line away from the midline which is the area of ulceration. No breakdown or ulceration in the flap or donor defect suture line were seen during 1-4 years of follow up. Operative technique is briefly described and important points on flap planning are discussed.*

INTRODUCTION

Sacral skin is frequently the first area of breakdown in the acute spinal injury patient due to bed rest in supine position. These are also seen in rehabilitated patients who are forced to become bedridden due to intercurrent illnesses usually involving either respiratory or genitourinary infections.

Surgical treatment consists of (i) excision of the ulcer and entire bursae, (ii) conservative osteotomy to achieve smooth, evenly contoured sacrum and (iii) closure of the defect by any one of the following methods, viz. primary closure, skin graft, reverse dermal graft, inferiorly based skin flap, gluteus maximus myocutaneous flap, gluteus maximus v-y myocutaneous flap, transverse lumbosacral flap, superior gluteus myoplasty, turnover gluteus myoplasty, gluteal thigh flap or sensory island flaps¹.

We describe the use of Limberg flap for closure of moderate size sacral pressure sores in 5 cases with consistently good results.

MATERIAL AND METHODS

Limberg flap was used for closure of sacral pressure sores in 5 male patients. One patient was a 5 year old child with a deep ulcer of dimensions 3.5-4.5 cm in sacrococcygeal region (Fig 1). The other four patients were adult males aged between 25 and 35 years with sacral pressure ulcers following traumatic paraplegia, measuring about 8-10 cm in 3 cases and 5-6 cm in one case (Table 1). All the patients had only a single pressure sore.

OPERATIVE TECHNIQUE

The general condition of the patient was stabilised by correction of anaemia and hypoproteinaemia.

Wound swabs were done for bacteriological culture and sensitivity and under antibiotic cover, patients were taken up for surgery. No anaesthesia was given for paraplegics but the child was operated under general anaesthesia. Intravenous fluids were started and 1-2 units of blood were transfused during the operation. The ulcer along with the undermined and scarred skin and bursae was excised to produce a 60 degrees and 120 degrees horizontally oriented rhomboid defect whose short diagonal was kept oblique to the midline (Fig 2A & 3A). In the case of the child who had sacrococcygeal ulcer, vertically oriented rhomboid defect with short diagonal at right angle to the midline was created (Fig. 1).

Conservative osteotomy of sacrum was done to achieve evenly contoured smooth sacral surface. In 4 adult patients Limberg flap was marked

Table 1

Table shows age and sex of patients, site and size of ulcers and the Limberg flaps

Case No.	Age/sex	Neurological Status	Size & site of ulcer	Site of flap	Size of Limberg flap
1	5 yrs M	NPP*	3.5-4.5cm sacrococcygeal	Right side Superior base	6.0 cm
2	25 yrs M	TPP**	8-9.5 cm sacral	Right side below the defect	11.5 cm
3	32 yrs M	TPP	8-9 cm sacral	Left side below the defect	10.5 cm
4	30 yrs M	TPP	9-10 cm sacral	Right side below the defect	12.0 cm
5	35 yrs M	TPP	5-6 cm sacral	Right side below the defect	7.5 cm

NPP* Non-paraplegic

TPP** Traumatic paraplegic

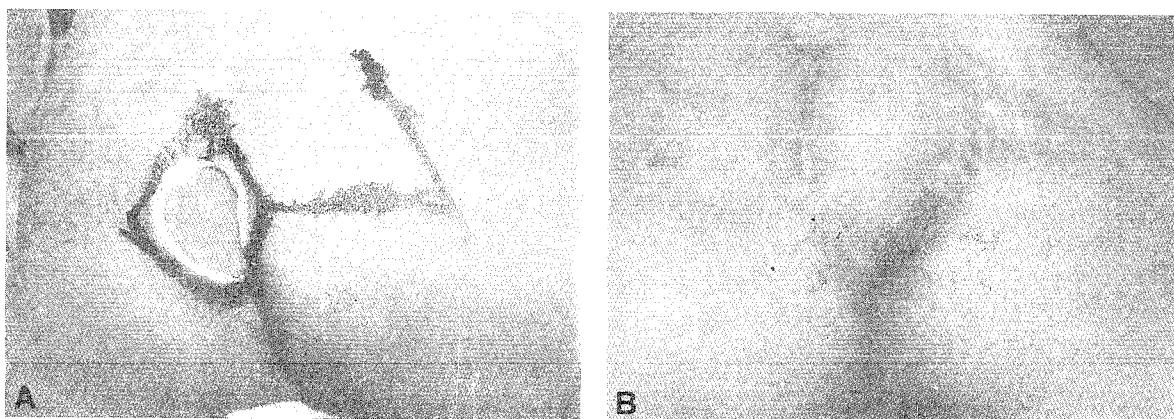
below the defect on the right (Fig. 3A) or the left side (Fig. 2A) depending on the obliquity of the defect and the short diagonal. But in the child it was marked on the right side with superior base (Fig. 1). Table 1 shows the size of the Limberg flaps.

The marked flap was incised and raised from the underlying muscle. Margins of the donor defect were widely undermined to facilitate closure of the donor defect and flap transposition with ease. Complete haemostasis was achieved and two drains (vacuum suction or corrugated) were used one each in the donor area and sacral defect area. Donor defect was closed and flap was sutured in 2 layers with 3-0 vicryl subcutaneous and 3-0 silk/nylon skin stitches. The operated area was covered with padded dressing.


Patients were kept in the prone or semiprone position keeping the base of flap dependent. Antibiotics were given based on the bacterial culture sensitivity report. The first dressing was done after 24 hours, the drains were removed after 72-96 hours and stitches were removed on 8th to 10th day. Patients were allowed to lie supine from 10th day onward, initially for short periods and increasing it over the next 2-3 weeks.

RESULTS

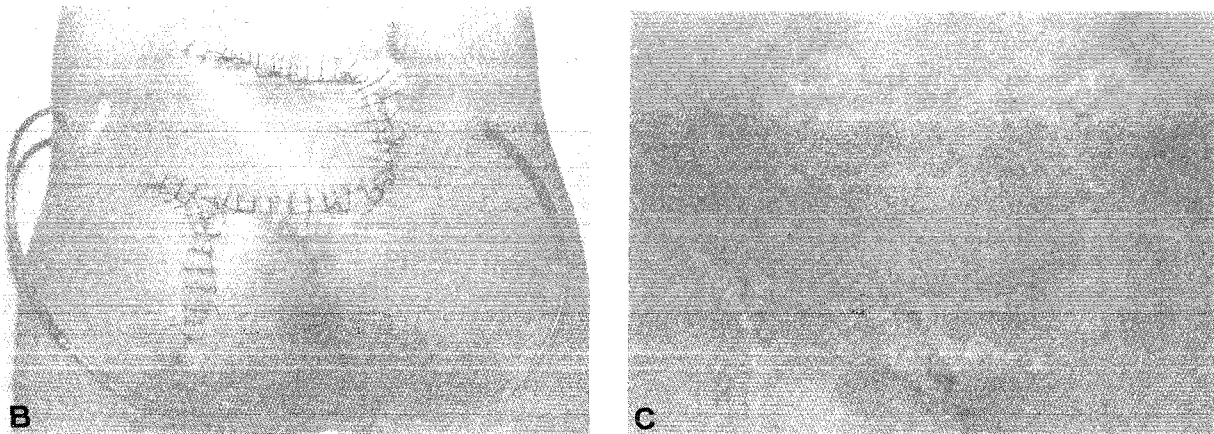
In all the cases wounds healed by the 10th day and the flap provided a good padded skin cover to the sacral region. At 1-4 years follow up there was no breakdown or recurrent ulceration of sacral region or donor defect suture line in any of the cases.



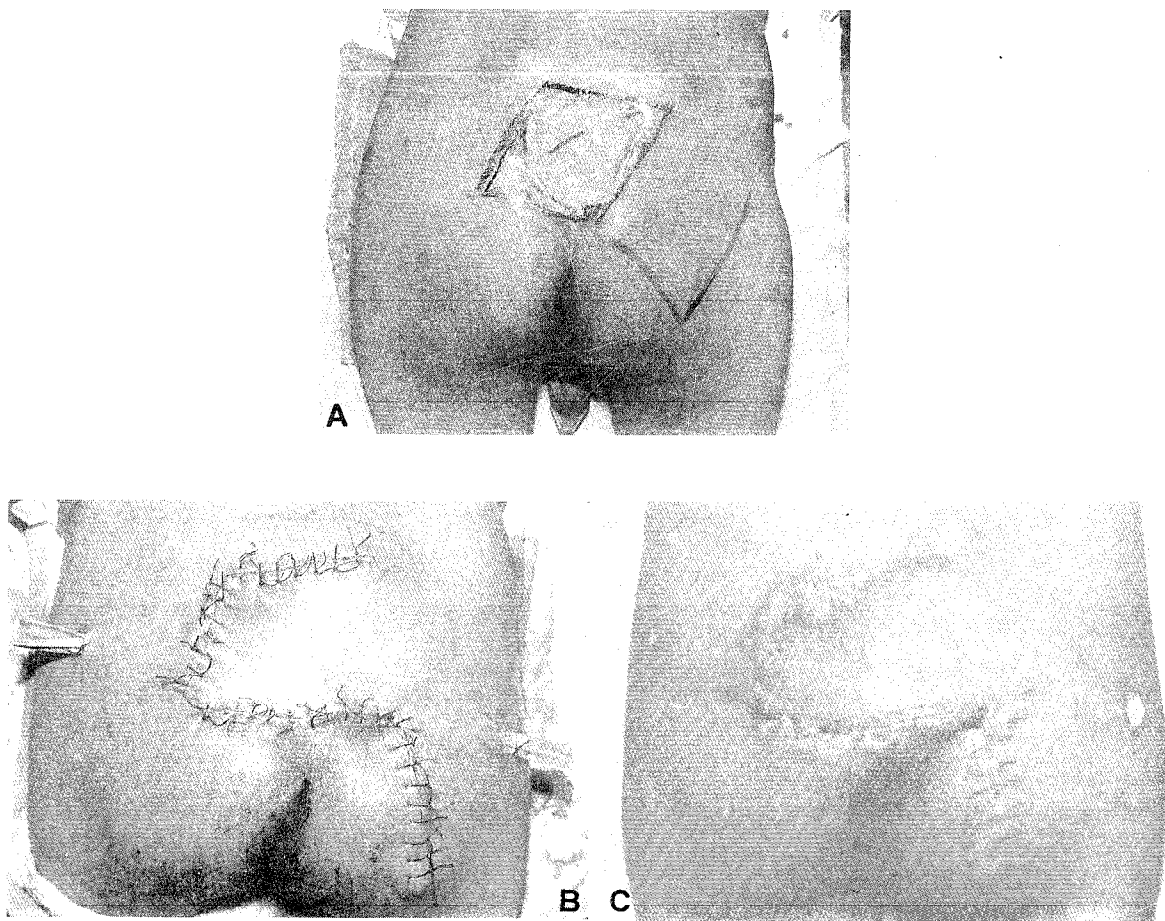
(Fig - 1) (a) Vertically oriented sacrococcygeal ulcer. The rhomboid defect with the horizontal short diagonal and the proposed Limberg flap (b) Postoperative result



(Fig - 2) (a) Horizontally oriented sacral ulcer, marked rhomboid defect with short diagonal oblique to midline and the proposed Limberg flap. (Fig. Continues)



(Fig - 2) (b) Operative photograph showing closed donor defect and flap sutured to sacral defect (c) Postoperative result



(Fig - 3) (a) Horizontally oriented sacral ulcer, marked rhomboid defect with the short diagonal oblique to midline and the proposed Limberg flap (b) Intraoperative photograph (c) Postoperative result

DISCUSSION

Limberg flap is a transposition flap which depends on the looseness of adjacent skin and is suitable only for closure of rhomboid defects with angles of 60 degrees and 120 degrees. The sides of the Limberg flap are kept equal to the short diagonal of the rhomboid defect²⁻⁵.

Limberg flap is one of the techniques for covering skin defects that are not amenable to straight line closure. It is a simple versatile technique that requires only the correct placement of the rhombic donor flap for its execution. It has been used extensively for closure of defects on different parts of the body. There is little mention of its use for the closure of sacral pressure sores. Though we have used it in 5 cases only, it has proved to be a very useful alternative for coverage of moderate size sacral pressure sores. It provides a good padded skin cover with suture line away from the midline. Though flap donor area closure line runs downwards and outwards towards the ischial region, it has not caused any problem in our cases.

While converting the pressure sore into a rhombic defect its short diagonal is kept oblique to the midline to keep the tip of the flap and donor defect closure lines away from natal cleft and perianal region. The flap can be raised from above or below the sacral defect on either side, but we prefer the flap from below the defect because it provides thicker tissue and hence a better padding. In vertically oriented low lying defects (Fig. 1) the

short diagonal is kept horizontal and Limberg flap from either side with a superior base is found more suitable and practical. Limberg flap has proved to be as good as other non-sensory flaps for coverage of sacral pressure sores.

References

- 1 **Colen S.** Pressure Sores. In: McCarthy JG ed. Plastic Surgery Vol.6 Philadelphia : WB Saunders Co., 1990: 3797-3838.
- 2 **Limberg AA.** Design of Local Flaps. In: Gibson T ed. Modern Trends in Plastic Surgery, London : Butterworths, 1966:38-61.
- 3 **Lister GD and Gibson J.** Closure of Rhomboid Skin Defects : The Flaps of Limberg and Dufourmental. Brit J Plast Surg. 1972; 25: 300-314.
- 4 **JanKauskas S, Cohen IK, Grabb WC.** Basic Techniques of Plastic Surgery. In: Smith JW and Aston SJ ed. Grabb and Smith's Plastic Surgery 4th Ed. Boston: Little Brown & Co 1991:1-90.
- 5 **Borges AF.** The Rhombic Flap. Plast. Reconstr. Surg. 1981; 67:458-466.

Authors

Dr Avtar Singh, MS, M Ch (Plastic), Senior Lecturer
Dr K S Mander, MS, M Ch (Plastic), Professor & Head
Dr G P Singh, MS, M Ch (Plastic), Assistant Professor
Dr S K Gulati, MS, M Ch (Plastic), Resident
Dr Gopal Malhotra, MS, M Ch (Plastic), Resident
Dr K C Garg, MS, M Ch (Plastic), Resident
Dr J P S Walia, MS (Ortho), Senior Lecturer in Orthopaedics

Department of Plastic & Reconstructive Surgery, Government Medical College & Rajendra Hospital, Patiala 147 001, Punjab

Requests for reprints to Dr Avtar Singh, 44B/4 Dashmesh Nagar, Patiala 147 001, Punjab