



Invited Article

A SYSTEMATIC APPROACH FOR MICROSURGICAL RESTORATION OF OPPOSITION FOLLOWING MULTIPLE DIGIT LOSS

Tarek Abdalla El-Gammal and Fu-Chan Wei

Dept of Plastic & Reconstructive Surgery, Chang Gung Memorial Hospital, Taipei, Taiwan, Republic of China

INTRODUCTION

The functional deficit is often profound following mutilating hand injuries with loss of multiple digits¹⁻³. The aim of surgery should be directed towards the restoration of opposable digits. Although local procedures such as osteoplastic reconstruction, pollicization and phalangization are useful, they require the use of adjacent functioning digits. In severe hand injuries, the remaining digits may be stiff and unsuitable for conventional reconstructive techniques. Multiple toe transfer, performed either sequentially or simultaneously¹⁻⁷ can tremendously improve hand function by bringing additional functioning units to the hand. Selection of a specific set of transfers must take into consideration both the anatomic and functional requirements as well as the patient's concerns regarding appearance and donor site morbidity. This article provides the guidelines for restoring function and appearance to severely mutilated hands utilizing a variety of toe-to-hand transfers.

INITIAL CARE

Toe transfer is to be considered in the context of a prioritized system for acute care of complex hand injuries. Replantation, of course, should be performed when feasible. Initial care should be directed to thorough debridement of all nonviable tissues followed by adequate soft tissue coverage. Length of bone, tendon, and neurovascular bundle must be properly preserved if reconstruction with toe transfer is considered. Excessive shortening of the digital skeleton, especially removing a mobile PIP or MP joint, and using local flaps to achieve primary coverage should be avoided. Soft tissue can be augmented with a pedicled groin flap or free flap transfer. The redundant skin will later prove useful particularly for covering the lateral aspect of the transferred toes to protect the pedicle and improve scar quality. Reconstruction by toe transfer can be performed either primarily when

the wound is still open or secondarily after the wound heals. Primary reconstruction is recommended in patients with clean wounds and good general condition since it has been shown to add no statistically significant risk of failure or complications⁸.

THUMB RECONSTRUCTION

Reconstructive considerations

In the normal hand, the thumb is said to contribute 40-50% of total hand function⁹. In the mutilated hand, the thumb is even more important since it has to compensate for the reduced mobility and length of the transferred toes. Therefore, a non-replantable thumb amputation, even as distal as the IP joint, should be considered for toe transfer reconstruction. A remaining trapeziometacarpal mobility is required for functioning thumb reconstruction. In the absence of trapeziometacarpal mobility, the reconstructed thumb will function as a stable post.

Consideration of residual thenar muscle function is important¹⁰. When thenar function is preserved, a more "static" reconstruction may suffice. When thenar function is impaired, restoration of MP, and possibly IP, joint function becomes a priority. Thenar function also has a bearing on timing of reconstruction. With intact thenar muscles, simultaneous reconstruction of the thumb and digits is preferable. If there is doubt about thenar function, fingers should be reconstructed first. Temporary use of a prosthetic post helps to determine the required length and position of the transferred toe when the thumb is reconstructed. If thenar function is defective, performing tendon transfer for restoration of opposition at the time of toe transfer markedly shortens the rehabilitation period.

Reconstructive options

Since the introduction of free toe to hand transfer by Cobbett in 1969 and Bunke et al. in 1973, several

techniques have been developed^{11,12}. Current transfers utilize the whole great toe¹³⁻²², the great toe wrap-around flap²³⁻²⁵, the trimmed great toe²⁶, and the second toe²⁷⁻³¹. There is no universal agreement as to which microsurgical method of thumb reconstruction is ideal. Each has its pros and cons. In general the great toe makes a better thumb than the second toe both functionally and cosmetically, as the second toe provides limited contact surface for pinch and tends to claw. However, the donor site of the great toe is esthetically worse than that of the second toe. Second toe transfer can be combined with metatarsal transfer to restore length and reconstruct MP joint mobility in case of transmetacarpal thumb amputation. Although not recommended by the senior author, a dorsalis pedis flap can be harvested in conjunction with the second toe provided the foot defect is carefully skin grafted. The great toe wrap-around flap with iliac bone graft designed by Morrison et al. preserves the stump of the great toe, thus improving the appearance of the donor foot³³. However, absence of distal joint mobility, pulp instability and iliac bone fracture or resorption makes this technique not suitable for all thumb reconstructions. Several modifications have been suggested to solve these problems but all provide immobile composite thumb^{23,24,34,35}. For mobility, Yu advocated elevating the great toe flap in conjunction with the vascularized bony framework and tendons of the second toe³⁶. The trimmed great toe transfer advocated by Wei et al. is a combination of the wrap-around and the whole great toe transfer methods²⁶. In this method excess bone, joint and soft tissue are removed from the medial aspect of the great toe prior to transfer. An average of 10° loss of active motion in the trimmed joints is expected as compared with the whole great toe transfer, but, contrary to the wrap-around technique, the interphalangeal flexibility needed for fine pinch is maintained. Table 1 summarizes the

Table I
Functional and cosmetic evaluation of the various transfer techniques for thumb reconstruction*.

	Second toe	Whole Great toe	Wrap around	Trimmed Great toe
Stability	F	E	G	E
Pinch	F	G	G	G/E
Joint Motion	F/G	F/G	N	F/G
Thumb appearance	F	F/G	E	E
Donor Foot appearance	E	P/F	F/G	P/F
Donor foot function	E	F	F/G	F

*None : N, poor : P, fair : F, good : G, excellent : E

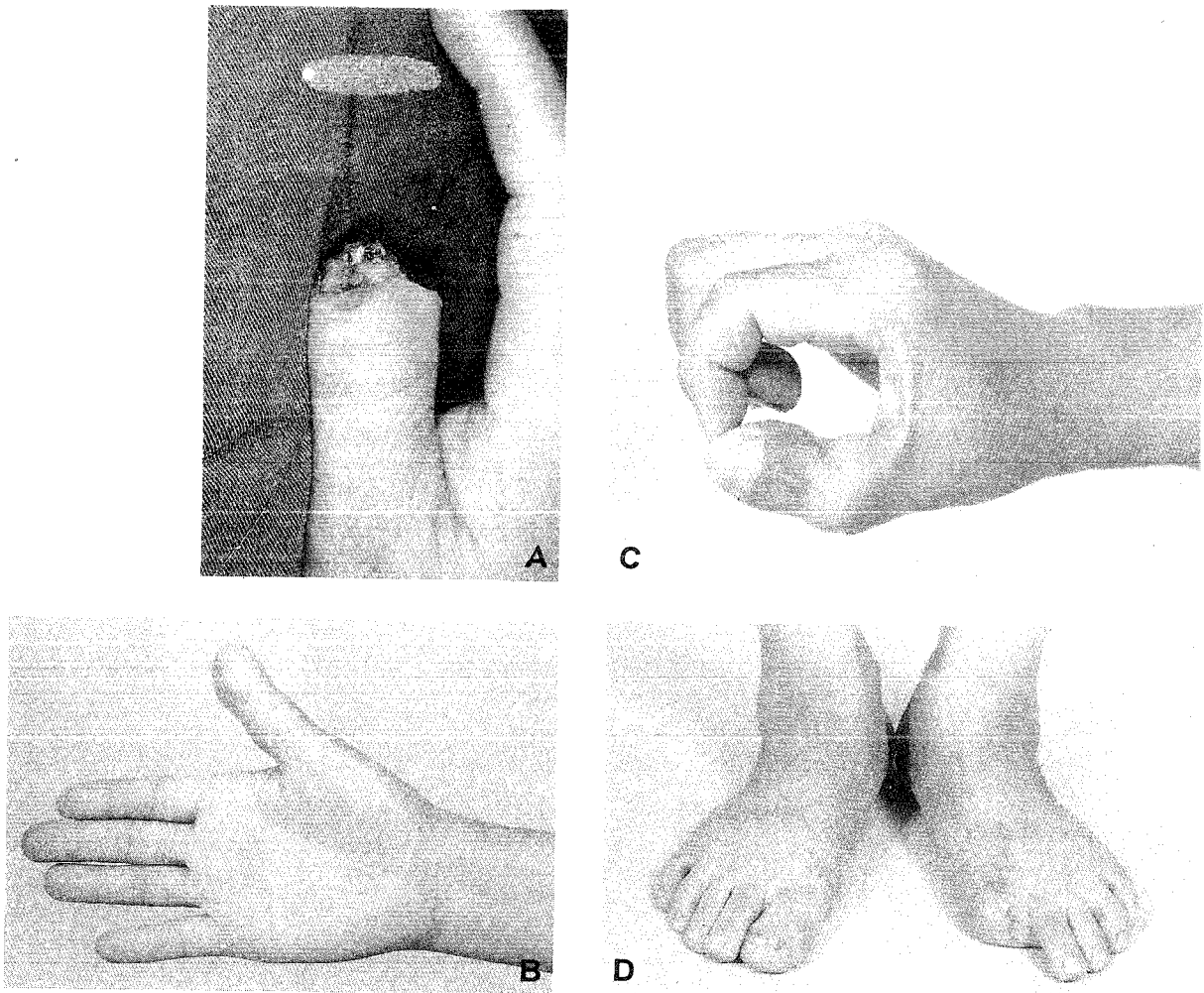
differences between the various toe to thumb transfer techniques.

Wei et al. have proposed the indications for the various transfers based on their experience of 103 cases over 9 years^{37,38}. Second toe transfer is best suited for patients with a second toe almost equal to the thumb in size, demand for minimum foot deformity and tolerance of suboptimal function and appearance of the reconstructed thumb (as in nondominant hand or in old age). Second toe should be used exclusively for thumb reconstruction in patients requiring transmetatarsal transfer to restore a foreshortened first metacarpal, since harvesting the first metatarsal in conjunction with the great toe would result in significant morbidity. It should also be used for thumb reconstruction in children because of potential involvement in running athletics and future job adaptability. Whole great toe transfer provides optimal functional qualities when either the thenar function or motion of the remaining fingers is diminished. It is suitable for those patients with reasonably sized great toe and a distal first metacarpal amputation. The great toe wrap-around transfer is an excellent option for the distal first ray degloving injuries or distal phalangeal amputation in the presence of reasonable MP and IP joint mobility (Fig. 1). Trimmed great toe transfer can be used for reconstruction of an esthetic, mobile thumb at the MP joint or proximal phalangeal level regardless of the size of the great toe (Fig. 2). Because toe trimming involves osteotomy through the epiphyseal region, trimmed toe transfer may theoretically influence skeletal growth in children.

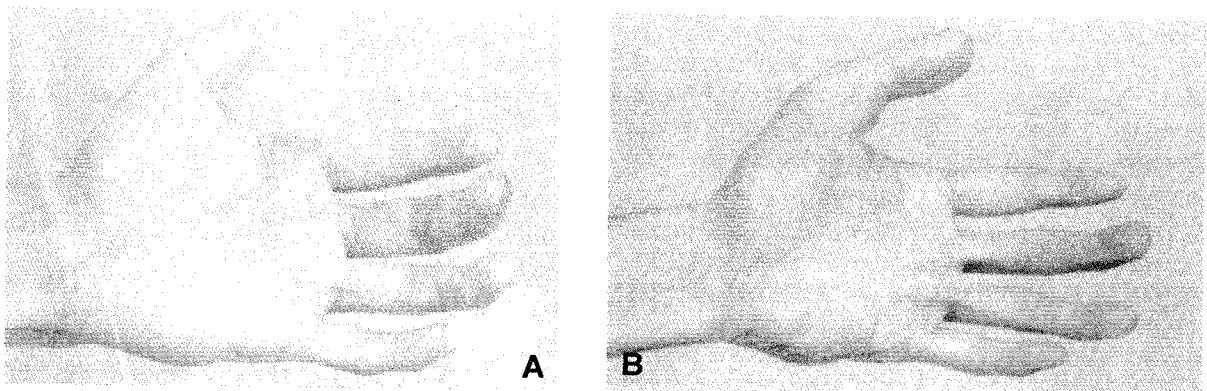
Technical considerations

In the whole great toe, trimmed great toe, and the great toe wrap-around methods, the toe is amputated at any level distal to the metatarsophalangeal joint depending on the length needed for thumb reconstruction as well as soft tissues left after toe harvest. Preservation of *one cm of the proximal phalanx* improves the appearance and push off function of the donor foot.

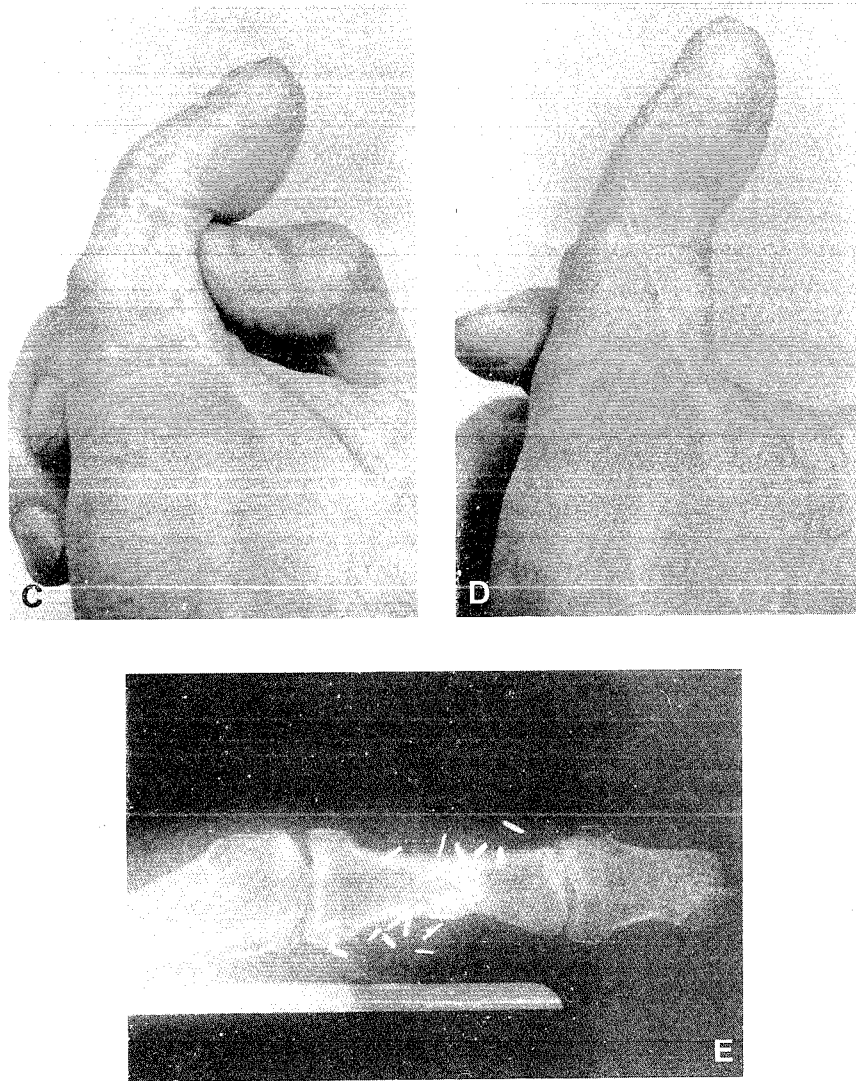
In the great toe wrap-around transfer, the distal phalanx is osteotomized longitudinally at one-third to one-half its tibial side. This allows reduction of the wide transverse diameter. The plantar side of the distal phalanx is also burred to reduce the anteroposterior diameter. Preservation of the vascularized distal phalanx on its fibular side helps to maintain stability of the wrap-around flap and normal nail growth. The extensor hallucis longus and flexor hallucis longus are included in the harvest if necessary.



(Fig - 1) (A) Thumb amputation distal to the IP joint (B) One year after wrap around great toe transfer (C) IP extension (D) Donor site appearance



(Fig - 2) (A) Thump amputation proximal to the IP joint (B) 3.5 years after trimmed great toe transfer and subsequent pulp plasty (Fig. continues)



(Fig - 2) (C) IP flexion (D) IP extension (E) Radiograph showing sound union of the transferred toe after interosseous wiring and very mild degenerative change at the lateral aspect to the trimmed joint.

In the trimmed great toe transfer, the reduction in soft tissue is similar to that in the great toe wrap-around transfer. Skeletal debulking is achieved by a longitudinal osteotomy through both the proximal and distal phalanges and the interphalangeal joint. In order to preserve joint stability, medial periosteum, capsule and collateral ligaments are elevated as a flap which is then repositioned after trimming.

In the second toe transfer, metatarsophalangeal disarticulation or transmetatarsal amputation are always performed regardless of the length needed. A tighter extensor than flexor repair, a longitudinal K-pin through the distal and proximal interphalangeal joints to keep the second toe in full extension for six weeks, and night extension splinting for at least one year help to overcome the flexion habitus of the second toe.

FINGER RECONSTRUCTION

Reconstructive considerations

Following consideration of the first ray possibilities, attention is then given to the restoration of opposable fingers. The surgeon poses three questions:

- 1) How many digits are to be restored?
- 2) Where these digits are to be positioned? and
- 3) Which technique of reconstruction is to be selected?

According to Tsai and Wei et al., it is best to aim at reconstructing at least two adjacent digits to allow useful chuck (tripod) pinch and provide support against ulnar drift with lateral pinch. Reconstruction of two fingers also provides a stronger hook grip and a wider span for grasping

large objects^{39,44}. Additional toe-to-finger transfer after restoration of the tripod pinch is controversial. When the ring or middle finger is missing, small objects may fall through the gap during grasp.

This problem can be solved with ray amputation. Additional toe transfer for this defect is sometimes indicated on cosmetic basis^{41,45,46}. However, a reasonable result can only be achieved when amputation is distal to the PIP joint with the joint function preserved.

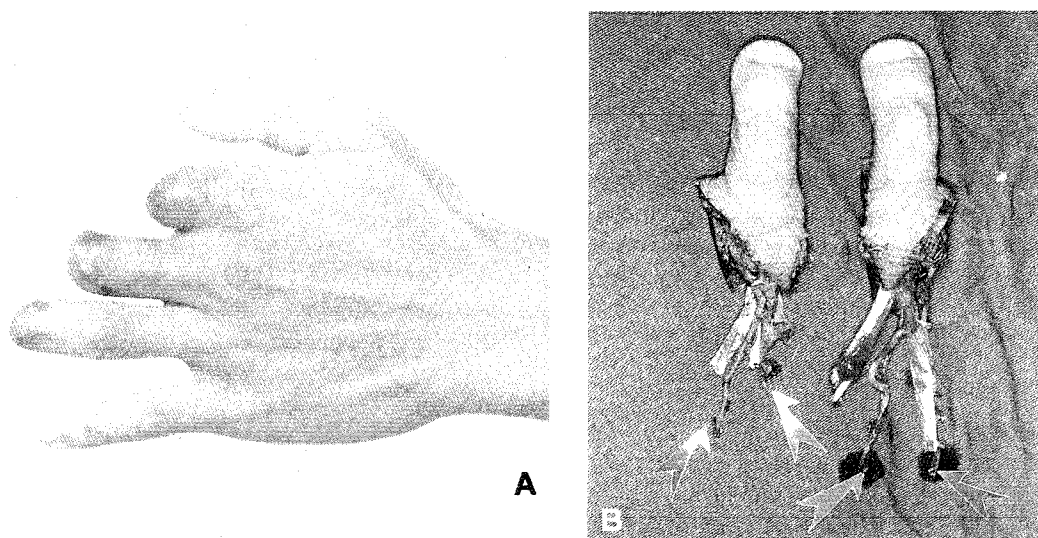
The exact placement of the reconstructed digits is controversial⁴⁷. In any case, the reconstructed digits must be accessible for opposition by the thumb. The decision is often individually tailored. Reconstruction of ulnar digits is best for labourers who require power grasp and large objects handling. Preservation of the web space is also important in this consideration. Reconstruction of the second and third digits is more cosmetic and better suited for patients with occupations requiring fine manipulation. Reconstruction of the long and ring fingers present a suitable compromise that provides a hand span adequate for both power grasp and pinch⁴⁴.

Reconstructive options

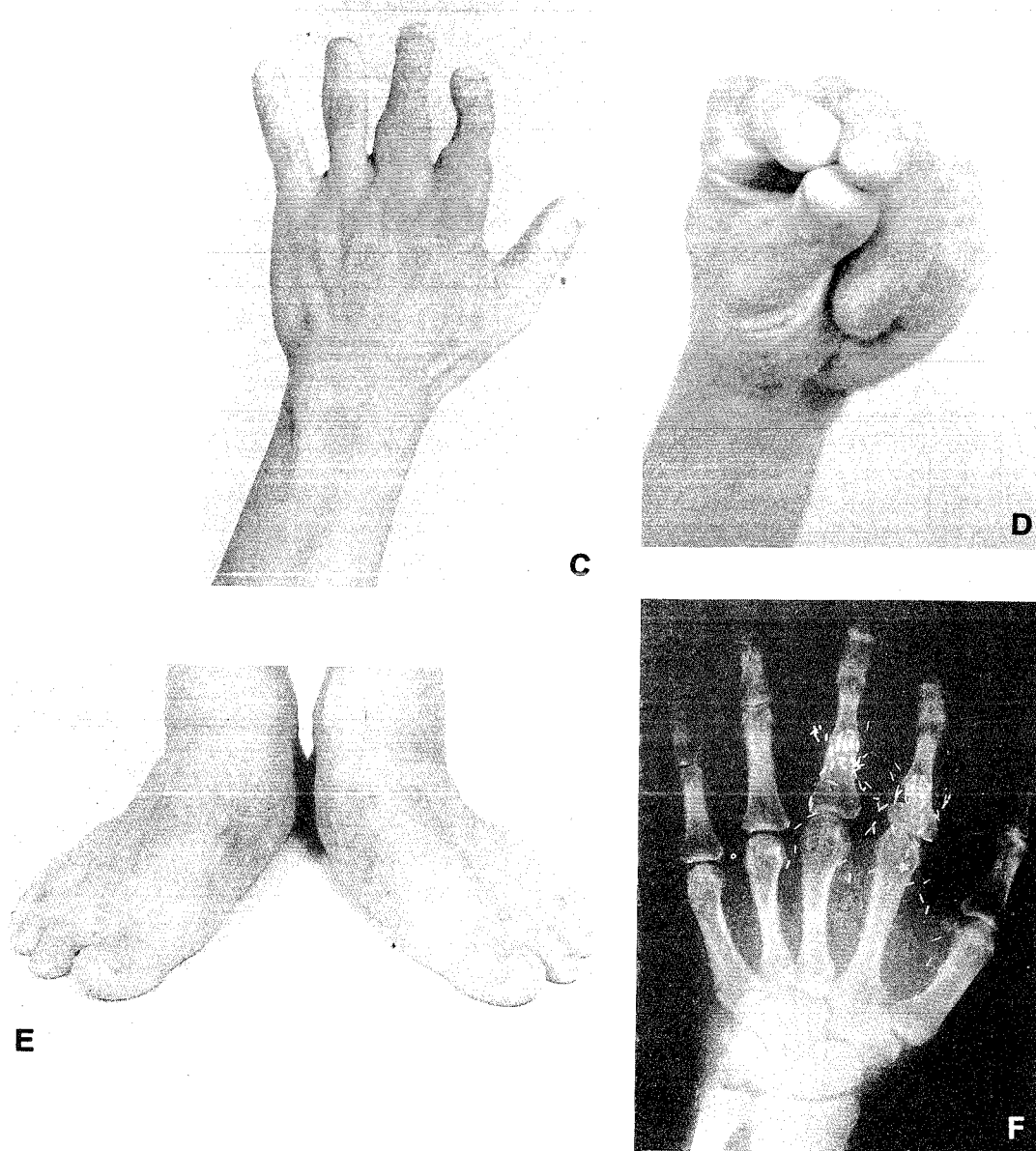
Amputations proximal to the MP joint can be reconstructed by total lesser toe, usually second toe transfer. However, this results in inadequate flexion since the transferred metatarsophalangeal joint has an average range of motion of only 30°^{48,10}. This is

aggravated by the short length of the toe and inevitable clawing from lack of intrinsic reconstruction⁴⁹. In transarticular amputations sparing the metacarpal articular surface, it is possible to reconstruct the MP joint by harvesting the toe down to the articular surface of the proximal phalanx including the joint capsule¹⁷. This technique provides an average range of motion of 40°¹⁰. When amputation is distal to the MP joint, the choice is between two separate second toe transfers or combined second and third toes transfer on a single vascular pedicle^{3,10,39,43}. Two second toe transfers are preferred when amputation is distal to the web space (Fig. 3) and when the remaining digits are longer than the small finger since transfer of a double toe unit in these cases would create syndactyly and incongruent grasp arc respectively^{42,43}. The third toe can be used instead of the second toe⁴⁶, 1) when the second toe is not available or unsuitable because of previous surgery or injury, 2) when the third toe provides a better size match, and 3) to minimize donor site deformity when the only second toe available is located in the same foot in which the great toe had already been harvested.

Combined second and third toes transfer is only suited for amputations proximal to the web space with absent or shortened remaining fingers^{42,43} (Fig. 4). The main advantage of combined toe transfer is that it requires only one set of recipient



(Fig - 3) (A) Amputation through the proximal phalanges to the index and middle fingers and the DIP joint to the ring finger (B) Two second toes separately harvested (Fig. continues)



(Fig - 3) (C) Two years after transfer of two second toes to the index and middle fingers (D) Good tripod pinch was achieved (E) Donor site appearance (F) Radiograph showing sound union of the transferred toes after interosseous wiring

vessels, which is important in a severely traumatized hand. Various donor site complications have been reported including delayed wound healing, standing and ambulation discomfort and migration of the fourth toe towards the first toe (scissoring)^{3,8,39,41,48}.

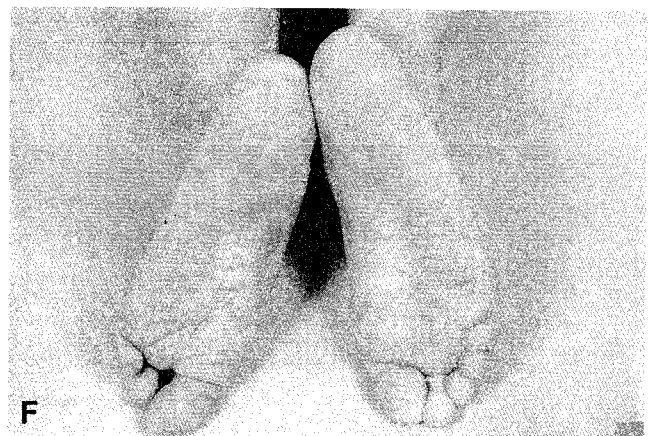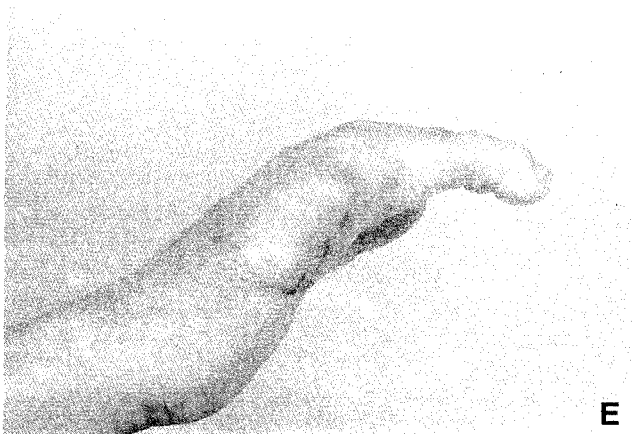
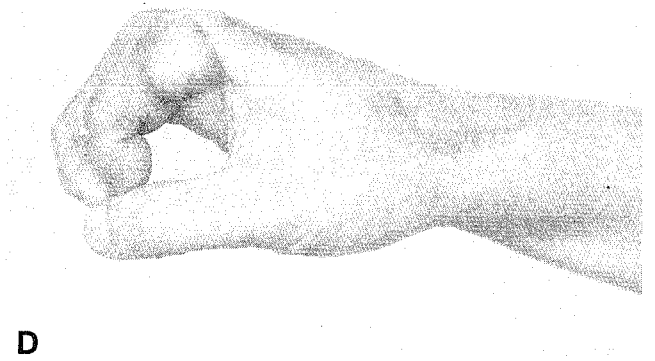
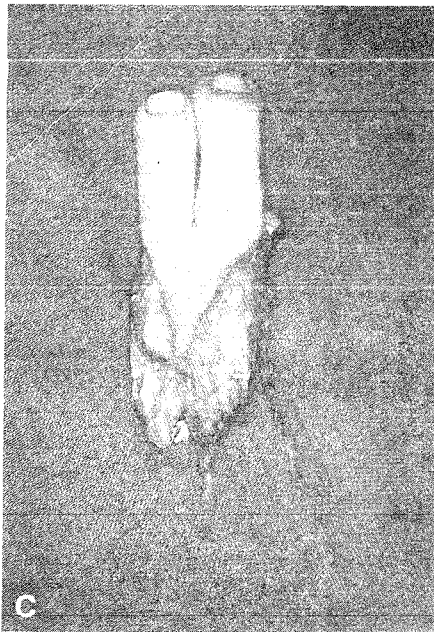
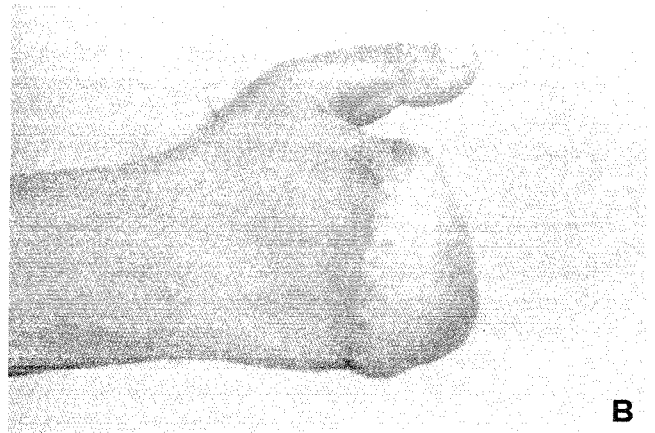
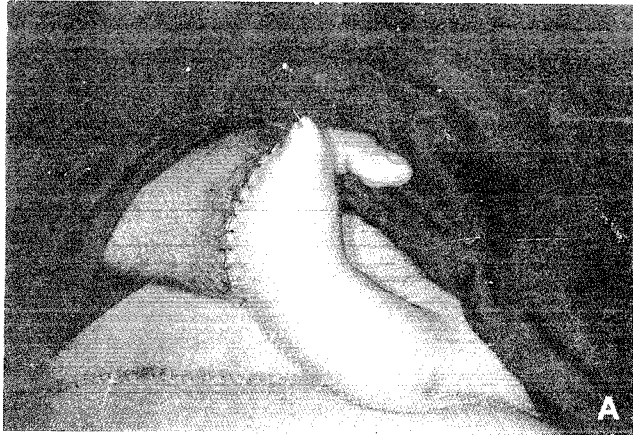Technical considerations⁴²

For the combined second and third toes transfer, Wei et al. have advocated limited dorsal and plantar skin flaps extending only to the midpoint of the first and third digital web spaces which allow for direct donor site closure^{42,43,50}. The plantar metatarsal arch should be maintained by avoiding

metatarsal shaft osteotomy unless mobile MP joints are required.

Secondary procedures

The circumference of the transferred great toe atrophies by 10-15% within the first three years⁵¹. However, in almost all patients, the thumb pulp is still larger than that of the normal thumb. Wei and Yim advocated pulp plasty by removing a longitudinal wedge of skin and subcutaneous tissue as soon as three months after the transfer⁵². They also suggested that pulp plasty be performed as an initial procedure while harvesting the toe with the exception of the trimmed toe and wrap-around



(Fig - 4) (A) Pedicled groin flap used for soft tissue coverage and augmentation following traumatic amputation to the four fingers (B) One month after division of the groin pedicle (C) Combined second and third toes harvested on a single vascular pedicle (D) One year after combined second and third toes transfer to the index and middle fingers showing good opposition (E) Extension of the transferred toes (F) Donor site appearance

techniques for fear of devascularizing the pulp. The reduction of bulky soft tissue in the pulp reduces shearing movement with pinch. Results showed subjective and functional improvement with almost no residual scarring. In a study of 139 toe-to-hand transfer by Yim and Wei, secondary procedures, other than soft tissue revision, was necessary to improve function in 15.8% of the cases. Tenolysis was the most common secondary procedure and its incidence was 6.8%⁵².

Rehabilitation

Rehabilitation after successful toe-to-hand transfer should aim at optimizing both motor and sensory recovery. Wei et al, advocated a five-stage rehabilitation program in which gentle passive movement is performed as early as the first postoperative day¹⁰. This program is outlined in table 2. Early sensory reeducation should aim at facilitating perception of touch submodalities with correct localization. Specific sensory exercises are utilized such as having the patient stroke the end of the transferred toe with the eraser of the pencil while verbalizing to himself "I feel something

moving on my finger". Following the recovery of constant and moving touch sensation, late-phase sensory reeducation is begun utilizing a group of objects differing in texture, size and shape for which the patient attempts to appreciate the object's nature with the tip of the transferred toe instead of the adjacent normal finger surface. Wei and Ma have evaluated a delayed sensory reeducation program in 22 toe transfers using a Disk-Criminator (TM) (Disk-Criminator, P.O. Box 16392, Baltimore, MD, 21210) as a home rehabilitation device. At an average of 3.3 months final evaluation, improvement averaged 7mm in static and 6mm in moving two-point discrimination. They attributed the improvement to cortical reorganization rather than stimulation of peripheral neural regeneration⁵³.

References

1. **Gordon L, Leitner DW, Bunke HJ, Aipert BS.** Hand reconstruction for multiple amputations by double microsurgical toe transplantation. *J Hand Surg* 1985; 10(A):218-225.
2. **Lichtman DM, Ahbel DE, Murphy RB, Bunke HJ.** Microvascular double toe transfer for opposable digits - case report and rationale for treatment. *J Hand Surg* 1982; 7(A):279-283
3. **O'Brien BM, Brennen MB, McLeod AM.** Simultaneous double toe transfer for severely disabled hands. *Hand* 1978;10:232-240.
4. **Holle J, Freilinger G, Mandl H, Frey M.** Grip reconstruction by double toe transplantation in cases of a fingerless hand and a handless arm. *Plast Reconstr Surg* 1982;69:692-698.
5. **Ohtsuka H, Torigai K, Shioya N.** Two toe-to finger transplants in one hand. *Plast Reconstr Surg* 1977; 60:561-565.
6. **Rose EH, Bunke HJ.** Simultaneous transfer of the right and left second toes for reconstruction of amputated index and middle fingers in the same hand. *J Hand Surg* 1980; 5(A):590-593.
7. **Yu ZJ.** Reconstruction of a digitless hand. *J Hand Surg* 1987;12 (A):722-726.
8. **Wei FC, Chen HC, Chuang CC, Nordhoff MS.** Simultaneous multiple toe transfers in hand reconstruction. *Plast Reconstr Surg* 1988; 81:366-374.
9. **Strickland JW, Kleinmann WB.** Thumb reconstruction. In: Green DP, Hotchkiss RN (Eds): *Operative Hand Surgery*, 3rd ed. New York: Churchill Livingstone, 1993:2043-2156.
10. **Wei FC, Coessens B, Ganos D.** Multiple microsurgical toe-to-hand transfer in the reconstruction of the severely mutilated hand. *Ann Hand Surg* 1992;11(3):177-187.
11. **Cobbett JR.** Free digital transfer. Report of a case transfer of a great toe to replace an amputated thumb. *J Bone Joint Surg* 1969;51(B):677-679.
12. **Bunke HJ, McLean DH, George PT, Greech BJ, Chater NL, Commons GW.** Thumb replacement: Great toe transplantation by microvascular anastomosis. *Br J Plast Surg* 1973;26:194-201.
13. **Lister G.** The choice of procedure following thumb amputation. *Clin Orthop* 1985;195:45-51.

Table 2

Postoperative rehabilitation protocol

Stage	Timing	Rehabilitation technique
Protective	Day 1-3	<ul style="list-style-type: none"> - Psychological Support - Viability monitoring - Gentle exercise with protective splinting - Donor site desensitization
Early mobilization	Day 4-week 3	<ul style="list-style-type: none"> - Controlled passive ROM - Edema control - Protective splinting
Active motion	Week 4-week 5	<ul style="list-style-type: none"> - Passive and active exercises - Edema control and scar management - Dynamic splinting - Gait training
4. ADL training	Week 6-week 7	<ul style="list-style-type: none"> - Muscle power strengthening - ROM improvement - ADL designs - Sensory reeducation
5. Prevocational training	Week 8 onwards	<ul style="list-style-type: none"> - Muscle power strengthening - Coordination and dexterity training - Vocational activities design - Psychological adjustment reinforcement

14. **Bunke HJ**. Toe digital transfer. *Clin Plast Surg* 1976;3:49-57.
15. **May JW, Daniel RK**. Great toe to hand free issue transfer. *Clin Orth Rel Res* 1978;133:140-153.
16. **May JW**. Aesthetic and functional thumb reconstruction: Great toe to hand transfer. *Clin Plast Surg* 1981;8(2):357-362.
17. **May JW, Bartlett SP**. Great toe to hand free tissue transplantation for thumb reconstruction. *Hand Clin* 1985;1(2):271-284.
18. **Morrison WA, O'Brien BM, Macleod AM**. Experience with thumb reconstruction. *J Hand Surg* 1984;9(B):223-233.
19. **O'Brien BM, McLeod AM, Sykes PJ, Donahoe S**. Hallux-to-hand transfer. *Hand* 1975;7:128-133.
20. **O'Brien BM, Brennen MB, McLeod AM**. Microvascular free toe transfer. *Clin Plast Surg* 1978;5(2):223-237.
21. **O'Brien BM, Morrison WA**. Thumb reconstruction. In: *Reconstructive Microsurgery*. Edinburgh:Churchill Livingstone, 1987:356-369.
22. **Strauch B**. Microsurgical approach to thumb reconstruction. *Orthop Clin North Am* 1977;8(2):319-327.
23. **Doi K, Hattari S, Kawai S**. New procedure on making a thumb-one stage reconstruction with free neurovascular flap and iliac bone graft. *J Hand Surg* 1981;6:346-350.
24. **Doi K, Kuwata N, Kawai S**. Reconstruction of thumb with a free wrap-around flap from the big toe and an iliac bone graft. *J Bone Joint Surg* 1985;67(A):439-445.
25. **Nunley JA, Goldner RD, Urbaniak JR**. Thumb reconstruction by the wrap-around method. *Clin Orthop Rel Res* 1985;195:97-103.
26. **Wei FC, Chen HC, Chuang CC, Noordhoff MS**. Reconstruction of the thumb with a trimmed toe transfer technique. *Plast Reconstr Surg* 1988;82:506-513.
27. **Dongyue Y, Gu YD**. Thumb reconstruction utilizing second toe transplantation by microvascular anastomosis: Report of 78 cases. *Chin Med J* 1979; 92(5):295-309.
28. **Foucher G, Moss AL**. Microvascular second toe to finger transfer: a statistical analysis of 55 transfers. *Br J Plast Surg* 1991;44:87-90.
29. **Leung PC**. Second toe to hand transplantation: Clinical experience of 25 cases. *Aust NZJ Surg* 1980;50:254-257.
30. **Leung PC**. Thumb reconstruction using second toe transfer. *Hand* 1983;15:15-21.
31. **Leung PC**. Thumb reconstruction using second toe transfer. *Hand Clin* 1985;1:285-295.
32. **O'Brien BM, McLeod AM, Sykes PJ, Browning FS, Threfall GN**. Microvascular second toe transfer for digital reconstruction. *J. Hand Surg* 1978;3(A):123-133.
33. **Morrison WA, O'Brien BM, Macleod AM**. Thumb reconstruction with a free neurovascular wrap-around flap from the big toe. *J Hand Surg* 1980;5:575-583.
34. **Yu ZJ, He HG, Tang CH**. Reconstruction of the thumb by free skin flap of the big toe. *J. Reconstr Microsurg* 1984;1(2):155-159.
35. **Urbaniak JR**. Wrap around procedure for thumb reconstruction. *Hand Clin* 1985;1:259-269.
36. **Yu ZJ, He HG**. Thumb Reconstruction with free big toe skin-nail flap and bones, joints and tendons of the second toe. Report of the cases. *Chin Med J*, 1985;98:863-867.
37. **Wei FC**. Microsurgical thumb reconstruction with various toe transfers. *Plastic Surg* 1992;11:785-786.
38. **Wei FC, Chen HT, Chuang CC, Chen ST**. Microsurgical thumb reconstruction with toe transfer: selection of the various techniques. *Plast Reconstr Surg*, 1994;93:345-351.
39. **Tsai TM**. Second and third toe transplantation to a transmetacarpal hand. *Ann Acad Med Singapore* 1979;8:413-418.
40. **Tsai TM, Jupiter JB, Wolff TW, Atasoy E**. Reconstruction of severe transmetacarpal mutilating hand injuries by combined second and third toe transfer. *J Hand Surg* 1981;6:319-328.
41. **Wei FC, Chen HC, Chuang CC, et al**. Reconstruction of hand amputated at the metacarpophalangeal level by means of combined second and third toe from each foot. A case report. *J Hand Surg* 1986;11(A):340-344.
42. **Wei FC, Chen HC, Chuang CC, Chen ST, Noordhoff MS**. Combined second and third toe transfer. *Plast Reconstr Surg*, 1989;84(4):651-661.
43. **Wei FC, Chen HC, Chuang CC, Chen ST, Noordhoff MS**. Combined second and third toe transfer. Presented at the 3rd Annual Meeting of the American Society of Reconstructive Microsurgery, San Antonio, Texas, 1987.
44. **Wei FC, Colony LH**. Microsurgical reconstruction of opposable digits in mutilating hand injuries. *Clinics Plast Surg* 1989;16(3):491-504.
45. **Wei FC, Strauch RJ, Chen HC, Chuang CC**. Reconstruction of four damaged or destroyed ipsilateral fingers with free toe-to-hand transplantations. *Plast Reconstr Surg* 1994;93(3):608-614.
46. **Wei FC, Yim KK**. Single third toe transplantation in hand reconstruction *J Hand Surg*, accepted.
47. **Valauri FA, Bunke HJ**. Thumb reconstruction-great toe transfer. *Clinics Plast Surg* 1989;16(3):475-489.
48. **O'Brien BM, Morrison WA**. Finger and metacarpal hand reconstruction. In *Reconstructive Microsurgery*. Edinburgh: Churchill Livingstone, 1987:370-380.
49. **Morrison WA, Macleod AM, O'Brien BM**. Digital reconstruction in the mutilated hand. *Ann Plast Surg* 1982;9:392-399.
50. **Wei FC, Seah CS, Chen HC, Chuang CC**. Functional and esthetic reconstruction of a mutilated hand using multiple toe transfers and iliac osteocutaneous flap: A case report. *Microsurgery* 1993;14:388-390.
51. **May JW**. Microvascular great toe to hand transfer for reconstruction of the amputated thumb. In: *McCarthy JG* (Ed); *Plastic Surgery*, 1st Ed. Philadelphia: WB Saunders, 1990:5153-5185.
52. **Wei FC, Yim KK**. Pulp Plasty after toe to hand transplantation. *Plastic Reconstr Surg*, accepted.
53. **Wei FC, Ma HS**. Delayed sensory reeducation after toe-to-hand transfer. *Microsurgery*, accepted.

Authors

Dr Tarek Abdalla El-Gammal, MD. Clinical Fellow
Dr Fu-Chan Wei, MD, FACS. Professor and Chairman
 Department of Plastic and Reconstructive Surgery, Chang Gung Memorial Medical College, Chang Gung Memorial Hospital, Taipei, Taiwan, Republic of China.

Requests for reprints to Dr Fu-Chan Wei, Department of Plastic and Reconstructive Surgery, Chang Gung Memorial Hospital, Taipei, Taiwan, Republic of China