




# Bristow-Latarjet Surgery: A Current Overview in Brazil

## *Cirurgia de Bristow-Latarjet: Um panorama atual do Brasil*

Bruno Vierno de Araujo<sup>1</sup>  Paulo Henrique Schmidt Lara<sup>1</sup> Alberto de Castro Pochini<sup>1</sup>  
Benno Ejnisman<sup>1</sup> Eduardo Antônio de Figueiredo<sup>1</sup> Paulo Santoro Belangero<sup>1</sup>

<sup>1</sup>Orthopaedic surgeon, Sport Trauma Center, Department of Orthopedics and Traumatology, Escola Paulista de Medicina, Universidade Federal de São Paulo, São Paulo, Brazil

Rev Bras Ortop 2023;58(5):e734–e741.

Address for correspondence Bruno Vierno de Araujo, Centro de Traumatologia do Esporte, Departamento de Ortopedia e Traumatologia, Escola Paulista de Medicina, Universidade Federal de São Paulo, Rua Estado de Israel 636, Vila Clementino, São Paulo, SP, 04022-001, Brazil (e-mail: brunoviernodearaujo@yahoo.com.br).

### Abstract

**Objective** To provide a current overview of the Bristow-Latarjet surgery in Brazil.

**Materials and Methods** This cross-sectional study was based on an electronic questionnaire with 26 items, which was sent to active members of the Brazilian Society of Shoulder and Elbow Surgery (Sociedade Brasileira de Cirurgia do Ombro e Cotovelo, SBCOC, in Portuguese). The questionnaire addressed training, surgical technique, complications, and postoperative management.

**Results** We sent the questionnaire to 845 specialists from April 20 to May 12, 2021, and 310 of them answered it in full. During their specialization, most specialists participated in up to ten Bristow-Latarjet procedures. The most frequent complication was graft fracture, while the most common technical difficulty was screw positioning. In total, 50.6% and 73.9% reported having experienced intraoperative and postoperative complications respectively; 57.1% declared performing subscapularis suture; 99.7% indicated postoperative immobilization; and 61.9% considered graft consolidation fundamental.

**Conclusion** Most specialists participated in up to ten Bristow-Latarjet procedures during the specialization, but 13.5% of them graduated without participating in the surgery. The most frequent complication was graft fracture. The most common technical difficulty was screw positioning. Most participants prefer postoperative immobilization since they believe graft consolidation is essential to resume the practiced of sports. The highest complication rate occurred with specialists who have obtained their titles 11 to 15 years ago. In Brazil, the Southeast region is the largest producer of specialists and has the highest concentration of these professionals.

### Keywords

- ▶ joint instability
- ▶ shoulder dislocations
- ▶ shoulder joint
- ▶ postoperative complications

*Study developed at the Sports Traumatology Center, Escola Paulista of Medicine, Federal University of São Paulo, São Paulo, SP, Brazil.*

received  
May 16, 2022  
accepted  
May 5, 2023

DOI <https://doi.org/10.1055/s-0043-1776131>.  
ISSN 0102-3616.

© 2023. Sociedade Brasileira de Ortopedia e Traumatologia. All rights reserved.

This is an open access article published by Thieme under the terms of the Creative Commons Attribution-NonDerivative-NonCommercial-License, permitting copying and reproduction so long as the original work is given appropriate credit. Contents may not be used for commercial purposes, or adapted, remixed, transformed or built upon. (<https://creativecommons.org/licenses/by-nc-nd/4.0/>)

Thieme Revinter Publicações Ltda., Rua do Matoso 170, Rio de Janeiro, RJ, CEP 20270-135, Brazil

## Resumo

**Objetivo** Traçar um panorama atual da cirurgia de Bristow-Latarjet no Brasil.

**Materiais e Métodos** Estudo transversal no qual um questionário eletrônico com 26 perguntas sobre aspectos de formação, técnica cirúrgica, complicações e manejo pós-cirúrgico foi enviado a membros ativos da Sociedade Brasileira de Cirurgia do Ombro e Cotovelo (SBCOC).

**Resultados** Entre 20 de abril e 12 de maio de 2021, o questionário foi enviado a 845 especialistas, e obteve-se 310 respostas completas. Durante a especialização, a maior parte dos especialistas participou de até dez procedimentos de Bristow-Latarjet. A complicação mais frequente foi a fratura do enxerto, e a dificuldade técnica, o posicionamento dos parafusos. Ao todo, 50,6% já tiveram complicações no intraoperatório; 73,9% já tiveram complicações no pós-operatório; 57,1% fazem a sutura do subescapular; 99,7% indicam a imobilização no pós-operatório; e 61,9% consideram a consolidação do enxerto fundamental.

**Conclusão** A maior parte dos especialistas participou de até dez procedimentos de Bristow-Latarjet durante a especialização, mas 13,5% se formaram sem ter participado de nenhuma cirurgia. A complicação mais frequente foi a fratura do enxerto. A dificuldade técnica mais frequente foi o posicionamento dos parafusos. Imobilização no pós-operatório é a preferência da maioria dos participantes, que consideram fundamental a consolidação do enxerto para o retorno ao esporte. O maior número de complicações ocorreu com especialistas que obtiveram o título de 11 a 15 anos atrás. A região Sudeste é a maior formadora de especialistas e onde está concentrada a maior parte deles.

## Palavras-chave

- ▶ instabilidade articular
- ▶ articulação do ombro
- ▶ luxação do ombro
- ▶ complicações pós-operatórias

## Introduction

Bone block surgeries for the treatment of recurrent shoulder dislocation are widely used and established. Among several techniques, the Bristow-Latarjet procedure stands out. It is a surgery that fixates the coracoid process graft and the conjoint tendon to the anterior glenoid region to promote joint stability.<sup>1-3</sup>

Throughout the years, these surgeries have undergone modifications, and now it is possible to perform the Bristow-Latarjet procedure using an open or arthroscopic approach. The development of specific materials, including guides and cutting saws, facilitated the surgical steps.<sup>4</sup>

Even though Bristow-Latarjet surgery has been performed globally for years by orthopedists, it demands high technical ability from the surgeon. The literature describes many complications from these procedures, with rates ranging from 0% to 30%.<sup>5,6</sup> In recent years, there has been an exponential increase in the number of Bristow-Latarjet procedures performed.<sup>7-11</sup> The present study aims to provide a current overview of Bristow-Latarjet surgery in Brazil.

## Materials and Methods

We sent an electronic questionnaire by e-mail to all orthopedists who are active members of the Brazilian Society of Shoulder and Elbow Surgery (Sociedade Brasileira de Cirurgia do Ombro e Cotovelo, SBCOC, in Portuguese). The questionnaire consisted of 26 questions with multiple-choice

answers that covered specialist training, surgical techniques, complications, and postoperative management.

From April 20 to May 12, 2021, we sent the questionnaire to 845 active SBCOC members, and we received 310 questionnaires answered in full. The institutional Ethics in Research Committee approved the present study.

## Statistical Analysis

The platform used to obtain data was Google Forms. The statistical analysis included the test of equality of two proportions, the Chi-squared, Kruskal-Wallis, and Mann-Whitney tests, confidence intervals for the mean values, and *p*-values. The statistical analysis was performed using the following software: IBM SPSS Statistics for Windows (IBM Corp., Armonk, NY, United States), version 20.0, Minitab 16 (Minitab, LLC, State College, PA, United States) and Excel Office 2010 (Microsoft Corp., Redmond, WA, United States). The significance level adopted was of 0.05 (5%).

## Results

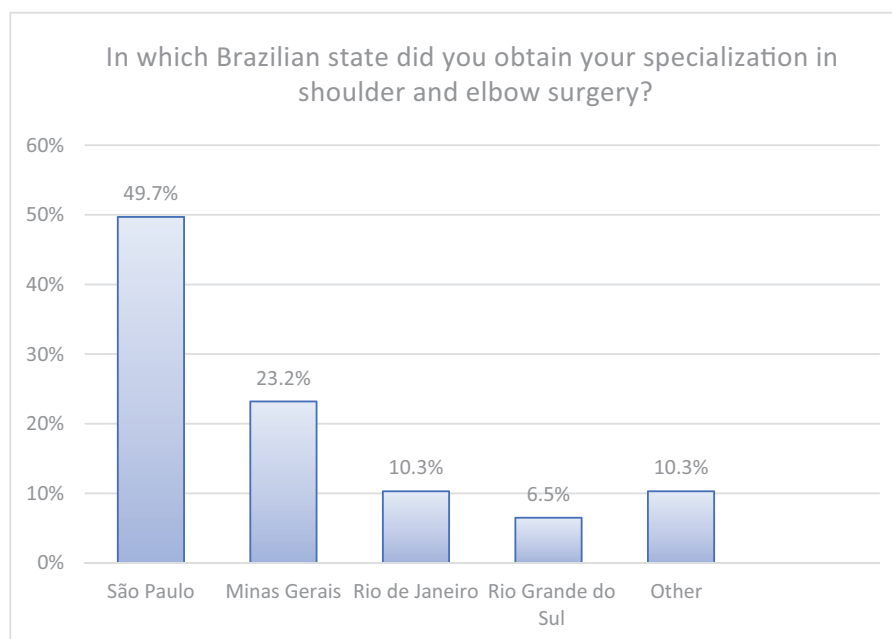
The year 2021 was the base to calculate the time since graduation from medical school, the year of completion of the medical residency in orthopedics and traumatology, and the date of obtainment of the specialist title from SBCOC (► **Table 1**).

The state of São Paulo was the largest producer of specialists, followed by Minas Gerais, Rio de Janeiro, and Rio Grande do Sul (► **Fig. 1**). The largest concentration of shoulder and

**Table 1** Time since medical school graduation, residency in orthopedics, and specialization title

		Mean	Median	Standard deviation	CV	Q1	Q3	Mode	Min	Max	N	CI
Time (in years)	Medical school graduation	19.3	17	9.6	50%	12	24	12	1	50	309	1.1
	Residency graduation	15.6	14	9.9	63%	8	21	4	3	48	310	1.1
	Specialization title	13.0	12	8.7	67%	6	18	3	1	44	303	1.0

Abbreviations: CI, confidence interval; CV, coefficient of variation; Min, minimum; Max, maximum; Q1, first quartile; Q3, third quartile.

**Fig. 1** State of Brazil where the specialization in shoulder and elbow surgery was obtained.

elbow surgery specialists is in São Paulo, Minas Gerais, Rio de Janeiro, and Rio Grande do Sul as well.

We asked about the number of Bristow-Latarjet procedures performed by orthopedists during their internship. Most specialists performed one to ten surgeries (► **Fig. 2**). We also asked them about the most frequent complications according to the literature. The most prevalent answers included graft fracture, graft failure, graft resorption, screw loosening, and postoperative hematoma (► **Fig. 3**).

The leading technical difficulties mentioned by the specialists were screw positioning, glenoid exposure, subscapularis opening, and osteotomy of the coracoid process (► **Table 2**).

Most specialists (287; 92.6%) preferred the open approach; only 4 (1.3%) favored the arthroscopic route, and 19 (6.1%) used both approaches. Most participants indicated a sling for postoperative immobilization, often for 4 weeks (► **Fig. 4**).

Most specialists only allow the return to sports that require the use of the upper limbs after the fourth month of surgery. Graft consolidation is a determining factor for resuming physical activities for most participants (► **Fig. 5**).

► **Fig. 6** shows the answers regarding the use of special devices/instruments during surgery, use of anchors for anterior labial repair, postoperative use of drains, intra- and postoperative complications, subscapularis suture, postoperative immobilization, the significance of graft consolidation to resume physical activities, and the use of computed tomography to assess graft consolidation.

When assessing the time since the obtainment the specialist title and the most prevalent complications, the highest number of complications occurred in the group of surgeons who specialized 11 to 15 years ago. This finding was statistically significant compared with all other groups (► **Table 3**).

## Discussion

The widely performed Bristow-Latarjet surgery for shoulder stabilization is a technically challenging procedure. For Castricini et al.,<sup>12</sup> the following five stages of the Latarjet procedure are the most critical: joint assessment, subscapularis division, coracoid graft removal, graft transfer, and graft fixation.

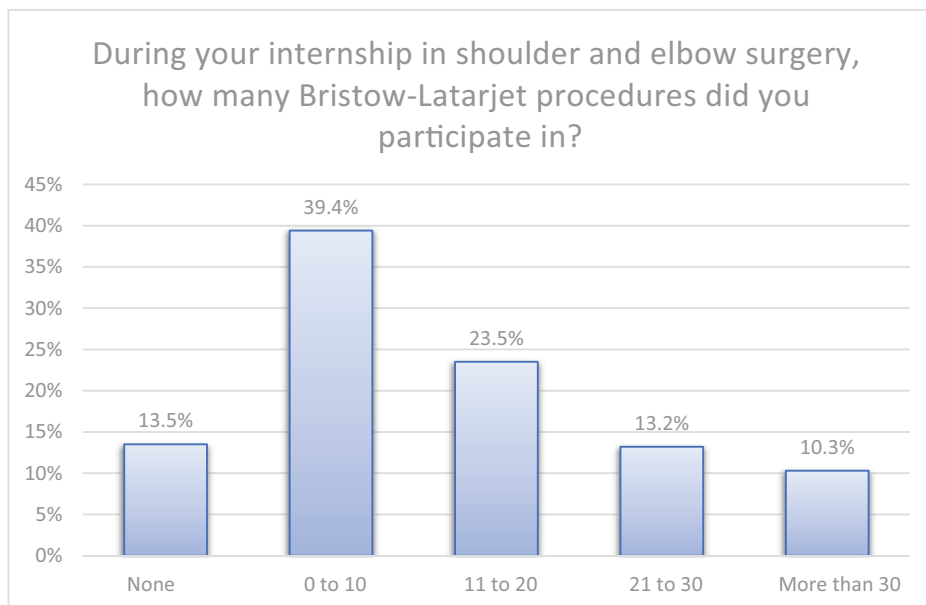


Fig. 2 Number of procedures during training.

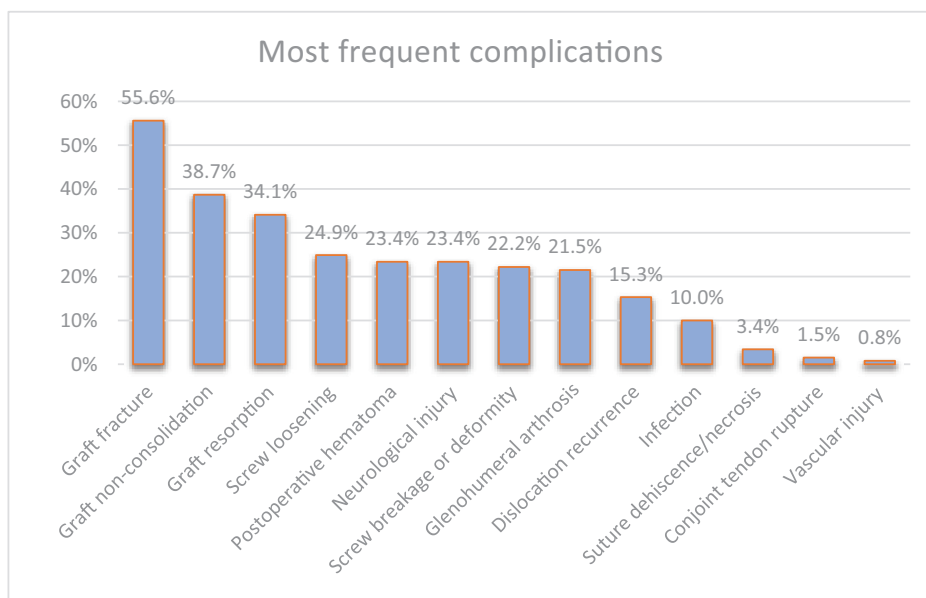
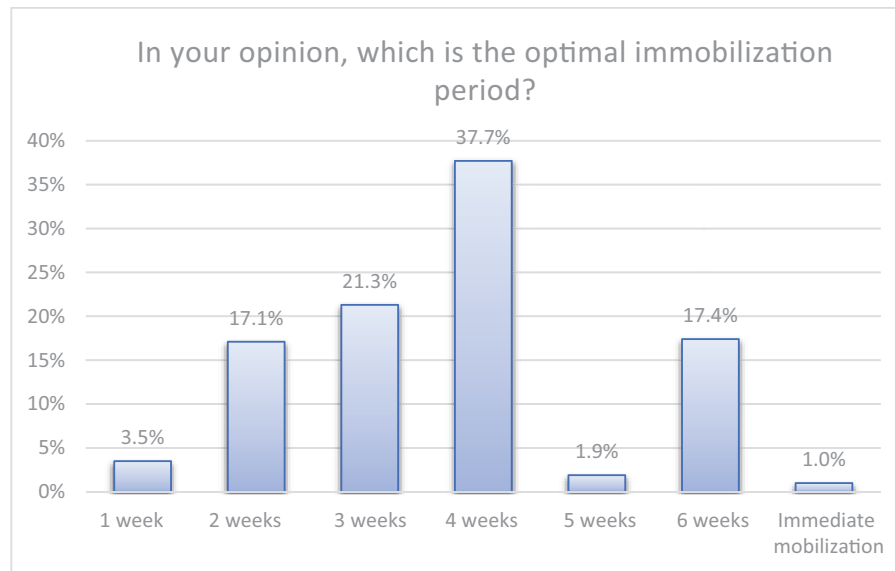


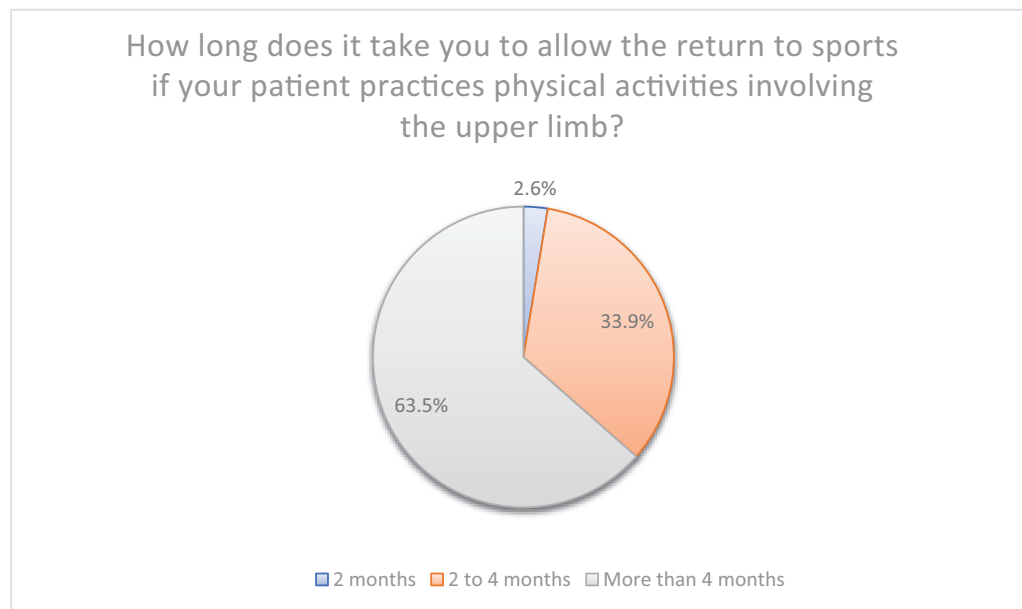
Fig. 3 Most frequent complications.

Table 2 Distribution of the most frequent difficulties

Major difficulties	N	%	p-value
Screw/fixation device positioning	137	54.6%	Ref.
Glenoid exposure	102	40.6%	0.002
Subscapularis and joint capsule opening	48	19.1%	< 0.001
Coracoid process osteotomy	36	14.3%	< 0.001
Other	11	4.4%	< 0.001



**Fig. 4** Postoperative immobilization time.



**Fig. 5** Time to return to sports after surgery.

An overview of the Bristow-Latarjet surgery yields fundamental tools to improve the training of Brazilian orthopedists. The learning curve for any surgical procedure has a direct implication on determinant health factors; moreover, higher training and experience on the part of the surgeon are associated with higher patient safety.<sup>13,14</sup> Ethkiari et al.<sup>15</sup> described that after 22 Latarjet procedures surgeons reach a level of proficiency that is reflected in a shorter intraoperative time. In the present study, we found that 23.5% of orthopedists participated in 21 to 30 Bristow-Latarjet procedures during their shoulder and elbow surgery internship. Most (39.4%) reported performing up to 10 procedures. It is noteworthy that 13.5% of the specialists reported they

did not perform any Bristow-Latarjet surgery during their specialization.<sup>15</sup>

We asked the participants about the number of procedures they had performed in the previous year. In total, 207 specialists (66.8%) performed up to 10 surgeries, 62 (20%), 11 to 20 surgeries, 8 (2.6%), 21 to 30 surgeries, and 6 (1.9%) participants performed more than 30 procedures. It is worth mentioning that the study was conducted during the coronavirus disease 2019 (COVID-19) pandemic, in which there was a decrease in the volume of elective surgeries in Brazil and worldwide. In a systematic review, Hope et al.<sup>16</sup> described the negative impact of the pandemic in the training of new surgeons due to the reduced number of procedures.<sup>16,17</sup>

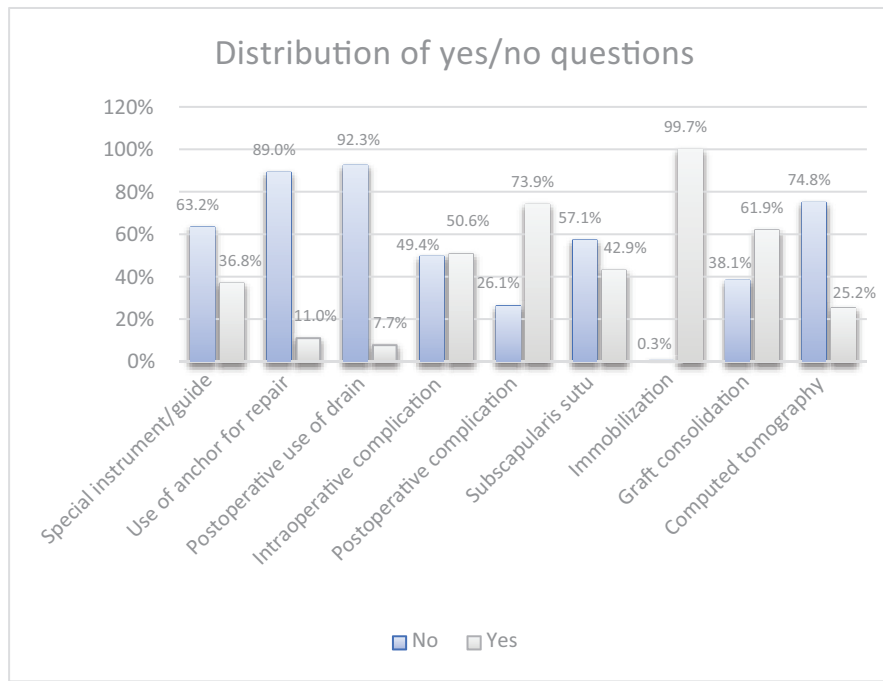


Fig. 6 Distribution of YES/NO questions.

Table 3 Number of complications per specialization time

		Complications: mean	Median	Standard deviation	Q1	Q3	N	CI	p-value
Specialization time in years	1–5	1.83	1	1.80	0.5	3	71	0.42	0.005
	6–10	2.19	2	1.67	1	3	64	0.41	
	11–15	2.93	3	1.69	2	4	55	0.45	
	16–20	2.26	2	1.81	1	3	57	0.47	
	> 21	2.27	2	1.98	1	3	56	0.52	

Abbreviations: CI, confidence interval; Q1, first quartile; Q3, third quartile.

Despite the increase in the number of arthroscopic procedures performed worldwide, in the present study we observed that our specialists still prefer the open approach.<sup>18,19</sup> Although technological advances introduced specific instruments, such as cutting and drilling guides, to help with the surgical steps of the Bristow-Latarjet procedure, most participants do not use them.<sup>4,20,21</sup>

When asked about their preferred method for graft fixation, the rates for the exclusive use of cannulated screws (38.4%), cannulated screws with another fixation device (35.2%), and the lack of use of cannulated screws (26.5%) were similar. In our study, most orthopedists performed graft fixation with 2 screws (82.9%), which has been consistent with the literature<sup>22–26</sup> since its description by Patte et al.<sup>23</sup>

Graft fracture was the most frequent complication in the present study, with 145 (46.8%) answers. Griesser et al.<sup>5</sup> stated that this complication often results from excessive screw tightening, advanced patient age, and excessive graft decortication during its preparation. As for screw-related issues in graft fixation, 65 (21%) and 58 (18.7%) participants mentioned loosening and breakage/deformation respectively.<sup>6,27</sup>

Neurological injury was reported by 61 participants (19.7%). For Cohen et al.,<sup>6</sup> the rates of neurological injury ranged from 1% to 20%, and the musculocutaneous and axillary nerves were the most frequently injured. Watchful waiting is usually enough for complete resolution of the complication.<sup>5,6,28</sup>

Postoperative hematoma was mentioned by 61 participants (19.7%). For Metais et al.,<sup>19</sup> hematoma is a rare complication, with an incidence ranging from 1% to 2%.

Hovelius and Saeboe<sup>29</sup> stated that glenohumeral arthrosis is often associated with a lateralized graft positioning or intra-articular screw placement of screws. In the present study, 56 (18.1%) participants reported this complication.

For Walch and Boileau,<sup>30</sup> the incidence of dislocation recurrence after the Bristow-Latarjet procedure is low, ranging from 1% to 3%. In the present study, 40 (12.9%) participants reported this complication.

Less than 10% of the participants in the present study reported infection, suture dehiscence or necrosis, joint tendon rupture, and vascular injury. This finding is consistent with the literature, which states that these complications are rare.<sup>5,6,28,29,31,32</sup>

Screw positioning was the technical aspect most mentioned as the major difficulty (by 137 participants; 44.2%). Correct screw positioning has a direct influence on graft positioning and fixation. Latarjet<sup>1</sup> recommended the best screw position as parallel to the articular surface. Hovelius and Saeboe<sup>29</sup> stated that, in addition to the correct graft positioning, it is critical to comply with the maximum screw inclination of 15 degrees to the articular surface. Kawakami<sup>33</sup> recommended screw parallelism; however, this is not the single and mandatory condition to avoid complications.

Glenoid exposure was the second major technical difficulty reported by participants, with 102 mentions (32.9%). In total, 48 specialists (15.5%) reported having difficulty opening the subscapularis and joint capsule, while 35 (11.6%) reported difficulty in coracoid process osteotomy. Walch and Boileau<sup>30</sup> recommended the horizontal opening of the subscapularis, keeping two-thirds superior and one-third inferior. The capsulotomy should be vertical and measure about 1.5 cm at the anteroinferior margin of the glenoid. The osteotomy must use a curved osteotome or an angled saw only after careful dissection of the pectoralis minor tendon and the coracoacromial ligament.<sup>30</sup>

Mobilization was indicated by 309 out of 310 specialists (99.7%). The optimal immobilization time ranged widely, and 117 (37.7%) participants preferred 4 weeks. Walch and Boileau<sup>30</sup> recommended a sling for 2 weeks, followed by physical therapy. In his original work published in 1958, Helfet<sup>2</sup> recommended postoperative immobilization for 6 weeks.

Most specialists (197; 63.5%) recommended returning to sports that require the use of the upper limbs only in the fourth month after surgery. Most participants also mentioned graft consolidation as a determining factor to resume physical activities, which is in line with the literature.<sup>27</sup>

According to Scheffer et al.,<sup>34</sup> the number of physicians in Brazil increased exponentially in recent decades. In the present study, we observed a greater participation of physicians graduating from 1999 onwards. The Brazilian states where most specialists work were São Paulo, Minas Gerais, and Rio de Janeiro. Our sample consisted entirely of specialists in Orthopedics and Traumatology (Brazilian Society of Orthopedics and Traumatology, Sociedade Brasileira de Ortopedia e Traumatologia, SBOT, in Portuguese) and Shoulder and Elbow Surgery (SBCOC). The states in which the internship in Shoulder and Elbow Surgery mostly occurred were São Paulo (51% of the participants), Minas Gerais (24.2%), Rio de Janeiro (10.3%), and Rio Grande do Sul (6.8%). Following the national scenario, the order of the states that produce the most specialists is the same. In the present study, consistent with the Brazilian scenario presented by Scheffer et al.,<sup>34</sup> the Northeast, North, and Midwest regions have few specialist training centers.

## Study Limitation

Even though we sent the questionnaire to all active SBCOC members and followed it up with an active search, not all specialists answered it. Using the questionnaire as a tool created a memory bias, and specialists with the greatest

number of years since the obtainment of the titles had more difficulty in answering precisely. Many orthopedists who are not SBCOC members perform shoulder surgeries, but they were not included in the present study, which sought to obtain data from active specialists from SBCOC.

## Conclusion

Most specialists participated in one to ten Bristow-Latarjet procedures during their specialization. A total of 13.5% of specialists graduated without participating in any surgery. The most frequent complication was graft fracture. The most prevalent technical difficulty was screw positioning. Most participants preferred postoperative immobilization since they considered graft consolidation essential to resume physical activities. The highest number of complications occurred with specialists who had obtained their titles 11 to 15 years ago. The Southeast region is the largest producer of specialists and where most of them have their practices in Brazil.

### Financial Support

The authors declare that they have received no financial support from public, commercial, or not-for-profit sources to conduct the present study.

### Conflict of Interests

The authors have no conflict of interests to declare.

## References

- Latarjet M. Treatment of recurrent dislocation of the shoulder. *Lyon Chir* 1954;49(08):994–997
- Helfet AJ. Coracoid transplantation for recurring dislocation of the shoulder. *J Bone Joint Surg Br* 1958;40-B(02):198–202
- Godinho GG, Monteiro PCVF. Tratamento cirúrgico da instabilidade anterior do ombro pela técnica de Didier-Patte. *Rev Bras Ortop* (Sao Paulo) 1993;28(09):640–644
- Zhang S, Zhang L, Han QX, Sun J, Ma J, Liu X-H, et al. [Comparison of the efficacy between open and arthroscopic Latarjet procedure in the treatment of anterior shoulder instability: a Meta-analysis]. *Zhongguo Gu Shang* 2021;34(06):573–583
- Griesser MJ, Harris JD, McCoy BW, Hussain WM, Jones MH, Bishop JY, Miniaci A. Complications and re-operations after Bristow-Latarjet shoulder stabilization: a systematic review. *J Shoulder Elbow Surg* 2013;22(02):286–292
- Cohen M, Fonseca R, Gribel B, Galvão MV, Monteiro M, Motta Filho G. Incidence and Risk Factors of the Complications Related to the Latarjet Surgery. *Rev Bras Ortop* 2021;56(03):307–312
- Degen RM, Camp CL, Werner BC, Dines DM, Dines JS. Trends in bone-block augmentation among recently trained orthopaedic surgeons treating anterior shoulder instability. *J Bone Joint Surg Am* 2016;98(13):e56
- Boileau P, Saliken D, Gendre P, Seeto BL, d'Ollonne T, Gonzalez J-F, Bronsard N. Arthroscopic Latarjet: Suture-Button Fixation Is a Safe and Reliable Alternative to Screw Fixation. *Arthroscopy* 2019;35(04):1050–1061
- Belangero PS, Lara PHS, Figueiredo EA, Andreoli CV, Pochini AC, Ejnisman B, Smith RL. Bristow versus Latarjet in high-demand athletes with anterior shoulder instability: a prospective randomized comparison. *JSES Int* 2021;5(02):165–170
- Figueiredo EA, Belangero PS, Cohen C, Louchard RL, Terra BB, Pochini AC et al. Rodeo athletes: management of shoulder instability. *J Sports Med Phys Fitness* 2016;56(05):560–564

- 11 Moura DL, Reis ARE, Ferreira J, Capelão M, Cardoso JB. Modified Bristow-Latarjet procedure for treatment of recurrent traumatic anterior glenohumeral dislocation. *Rev Bras Ortop* 2018;53(02):176-183
- 12 Castricini R, De Benedetto M, Orlando N, Rocchi M, Zini R, Pirani P. Arthroscopic Latarjet procedure: analysis of the learning curve. *Musculoskelet Surg* 2013;97(Suppl 1):93-98
- 13 Hopper AN, Jamison MH, Lewis WG. Learning curves in surgical practice. *Postgrad Med J* 2007;83(986):777-779
- 14 Dauzère F, Faraud A, Lebon J, Faruch M, Mansat P, Bonneville N. Is the Latarjet procedure risky? Analysis of complications and learning curve. *Knee Surg Sports Traumatol Arthrosc* 2016;24(02):557-563
- 15 Ekhtiari S, Horner NS, Bedi A, Ayeni OR, Khan M. The learning curve for the latarjet procedure: a systematic review. *Orthop J Sports Med* 2018;6(07):2325967118786930
- 16 Hope C, Reilly JJ, Griffiths G, Lund J, Humes D. The impact of COVID-19 on surgical training: a systematic review. [published correction appears in *Tech Coloproctol* 2021;25(11):1267-1268] *Tech Coloproctol* 2021;25(05):505-520
- 17 Posição do Conselho Federal de Medicina sobre a pandemia de COVID-19: contexto, análise de medidas e recomendações [accessed february 22, 2022]. Disponível em: <https://portal.cfm.org.br/images/PDF/covid-19cfm.pdf>
- 18 Lafosse L, Lejeune E, Bouchard A, Kakuda C, Gobezie R, Kochhar T. The arthroscopic Latarjet procedure for the treatment of anterior shoulder instability. *Arthroscopy* 2007;23(11):1242.e1-1242.e5
- 19 Metais P, Clavert P, Barth J, Boileau P, Brzoska R, Nourissat G, et al; French Arthroscopic Society. Preliminary clinical outcomes of Latarjet-Patte coracoid transfer by arthroscopy vs. open surgery: Prospective multicentre study of 390 cases. *Orthop Traumatol Surg Res* 2016;102(8S):S271-S276
- 20 Karlsson J, Magnusson L, Ejerhed L, Hultenheim I, Lundin O, Kartus J. Comparison of open and arthroscopic stabilization for recurrent shoulder dislocation in patients with a Bankart lesion. *Am J Sports Med* 2001;29(05):538-542
- 21 Castropil W, Schor B, Bitar A, Medina G, Ribas LH, Mendes C. Arthroscopic Latarjet: Technique Description and Preliminary Results. Study of the First 30 Cases. *Rev Bras Ortop* 2020;55(02):208-214
- 22 Gendre P, Thélou CE, d'Ollonne T, Trojani C, Gonzalez JF, Boileau P. Coracoid bone block fixation with cortical buttons: An alternative to screw fixation? *Orthop Traumatol Surg Res* 2016;102(08):983-987
- 23 Patte D, Bernageau J, Rodineau J, Gardes JC. Epaules douloureuses et instables. [Unstable painful shoulders (author's transl)] *Rev Chir Orthop Repar Appar Mot* 1980;66(03):157-165
- 24 Alvi HM, Monroe EJ, Muriuki M, Verma RN, Marra G, Saltzman MD. Latarjet Fixation: A Cadaveric Biomechanical Study Evaluating Cortical and Cannulated Screw Fixation. *Orthop J Sports Med* 2016;4(04):2325967116643533
- 25 Provencher MT, Aman ZS, LaPrade CM, Bernhardson AS, Moatshe G, Storaci HW et al. Biomechanical comparison of screw fixation versus a cortical button and self-tensioning suture for the Latarjet procedure. *Orthop J Sports Med* 2018;6(06):2325967118777842
- 26 Massin V, Lami D, Ollivier M, Pithioux M, Argenson JN. Comparative biomechanical study of five systems for fixation of the coracoid transfer during the Latarjet procedure for treatment of anterior recurrent shoulder instability. *Int Orthop* 2020;44(09):1767-1772
- 27 Sabharwal S, Patel NK, Bull AM, Reilly P. Surgical interventions for anterior shoulder instability in rugby players: A systematic review. *World J Orthop* 2015;6(04):400-408
- 28 Gartsman GM, Waggenspack WN Jr, O'Connor DP, Elkousy HA, Edwards TB. Immediate and early complications of the open Latarjet procedure: a retrospective review of a large consecutive case series. *J Shoulder Elbow Surg* 2017;26(01):68-72
- 29 Hovelius L, Saeboe M, Neer Award 2008: Arthropathy after primary anterior shoulder dislocation-223 shoulders prospectively followed up for twenty-five years. *J Shoulder Elbow Surg* 2009;18(03):339-347
- 30 Walch G, Boileau P. Latarjet-Bristow Procedure for Recurrent Anterior Instability. *Tech Shoulder Elbow Surg* 2000;1(04):256-261
- 31 Ikemoto RY, Murachovisky J, Nascimento LGP, Bueno RS Almeida LHO, Strose E, Helmer FF. Resultados da cirurgia de latarjet no tratamento da instabilidade anterior traumática do ombro associada à erosão óssea da cavidade glenoidal - Seguimento mínimo de um ano. *Rev Bras Ortop (Sao Paulo)* 2011;46(05):553-560
- 32 da Silva LA, da Costa Lima ÁG, Kautsky RM, Santos PD, do Val Sella G, Checchia SL. Evaluation of the results and complications of the Latarjet procedure for recurrent anterior dislocation of the shoulder. *Rev Bras Ortop* 2015;50(06):652-659
- 33 Kawakami E. Avaliação do posicionamento dos parafusos na cirurgia de Bristow - Latarjet. Paralelismo à glenoide é essencial? [dissertação]. São Paulo: UNIFESP; 2019
- 34 Scheffer M, Cassenote A, Guerra A, Guilloux AGA, Brandão APD, Miotto BA et al. Demografia Médica no Brasil 2020. São Paulo, SP: FMUSP, CFM; 2020