




A Century of Laffer-Ascher Syndrome

Parveen Rewri¹  Swapnil Garg² Rajender Kumar² Gulab Gupta³

¹Department of Ophthalmology, Maharaja Agrasen Medical College, Agroha (Hisar), Haryana, India

²Department of General Surgery, Maharaja Agrasen Medical College, Agroha (Hisar), Haryana, India

³Department of Pathology, Manglam Diagnostics, Hisar, Haryana, India

Address for correspondence Parveen Rewri, MS, FMRF, Department of Ophthalmology, Maharaja Agrasen Medical College, Agroha 125047, (Hisar), Haryana, India (e-mails: drparveenrewri@mamc.edu.in; drparveenrewri@gmail.com).

Indian J Plast Surg 2023;56:540–543.

Abstract

Laffer-Ascher syndrome is characterized by double lips, blepharochalasis, and non-goiter thyroid enlargement. The syndrome was first described in 1923 and several case reports have been published thereafter. We illustrate the syndrome through a case of a 46-year-old woman who presented with both upper and lower double lips and blepharochalasis, and review the literature published.

Keywords

- ▶ Laffer-Ascher syndrome
- ▶ double lip
- ▶ blepharochalasis

Thyroid involvement is the most inconsistent feature of the syndrome complex described in reported cases.

Introduction

Ascher syndrome or Laffer-Ascher syndrome is a rare, benign disorder characterized by a triad of blepharochalasis, double-upper lip, and nontoxic enlargement of the thyroid gland. The clinical characteristics are so intelligible that diagnosis is unchallenging in most cases. Over a century from now, when the combination of blepharochalasis and the double lip was first reported by Laffer in 1909, and since 1921 when this syndrome was named by Wave, nearly 100 case reports have been published globally in English and other languages.^{1,2} However, there is an ambiguity about the number of cases reported globally so far, the name of this syndrome, and the prevalence of clinical characteristics that are largely based on published individual cases. Few case reports have assigned a diagnosis of Ascher syndrome in the absence of the clinical signs suggestive of blepharochalasis or anomalous lips.³ Here, we describe the clinical presentation, surgical management, and histopathological aspects of an adult patient with blepharochalasis and double lips involving both lips, and review the literature to clear up the ambiguity.

Case Report

A 46-year-old woman presented with complains of drooping of her both upper eyelids for the past few years, which gradually progressed. On gross examination, she had bilateral blepharochalasis, more prominent on the right side, and both upper and lower lips were thick and prominent (▶Fig. 1A). The patient informed that the thickening of the lips started nearly 20 years back and gradually progressed. The onset of blepharochalasis was much later, starting almost 14 years after lip thickening, and initially, it was episodic and resolved spontaneously to recur. There was no history of taking any medications known to cause eyelid swelling or urticaria. Patient denied any use of mascaras or eye shadows. There was no family history of similar complaints. The rest of the ocular examination, including visual acuity, ocular movements, pupil reaction, and systemic examination, was normal. Based on dual findings of blepharochalasis and prominent lips, a provisional diagnosis of Laffer-Ascher syndrome was made. The patient was investigated for nontoxic enlargement of the thyroid gland by ultrasonography and thyroid profile, both of which were

article published online
October 18, 2023

DOI <https://doi.org/10.1055/s-0043-1776140>.
ISSN 0970-0358.

© 2023. Association of Plastic Surgeons of India. All rights reserved. This is an open access article published by Thieme under the terms of the Creative Commons Attribution-NonDerivative-NonCommercial-License, permitting copying and reproduction so long as the original work is given appropriate credit. Contents may not be used for commercial purposes, or adapted, remixed, transformed or built upon. (<https://creativecommons.org/licenses/by-nc-nd/4.0/>)

Thieme Medical and Scientific Publishers Pvt. Ltd., A-12, 2nd Floor, Sector 2, Noida-201301 UP, India

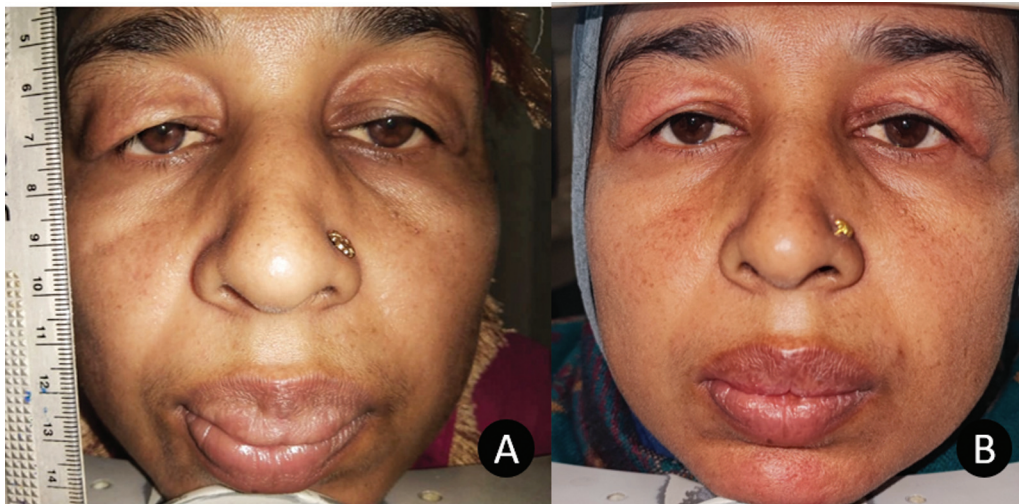

Fig. 1 (A) Preoperative photograph of a patient showing double lips and blepharochalasis. (B) Postoperative photograph.

normal. Other laboratory investigations, including renal function tests, were in the normal range. The patient was informed about surgical reduction of thickened lips tissue and correction of lid skin and was evaluated by a team comprising of an ophthalmologist and plastic surgeon. Single sitting blepharoplasty and lip debulking by double elliptical excision was done under general anesthesia and tissue was sent for histopathology. Histopathological examination revealed a normal epidermis with the loose dermis and dilated vessels along with perifollicular inflammatory infiltrates (→**Fig. 2A**) and decrease the density of elastin in the reticular dermis (→**Fig. 2B**), consistent with a diagnosis of Laffer-Ascher syndrome. The postoperative period was uneventful with marked cosmetic improvement in blepharochalasis and double lip after 2 months (→**Fig. 1B**).

We identified 74 case reports from Medline ($n = 39$) and Google Scholar ($n = 35$), of which 46 were in English language and 29 in non-English language. For non-English language case reports, abstract in English language was available for six case reports. After excluding duplicate, 37

case reports in English and 6 non-English abstracts were finally available for review.

Discussion

Historical Perspective

A combination of blepharochalasis with double lip was first reported by Laffer in 1909.¹ Over a decade later, Ascher reported nontoxic enlargement of thyroid along with blepharochalasis and double lip.⁴ In 1921, Weve reported a case of double lip in association with blepharochalasis and named it Ascher syndrome.² Some of the publications have addressed this combination of findings as Laffer-Ascher syndrome also.⁵⁻⁸

Natural Course

The syndrome most often affects lids first and later involvement of lips occurs. The lid involvement preceded in 15 (36%) case reports, lip involvement in 12(27%), and involvement was simultaneous in 8 (19%) cases. In our patient, it was lip

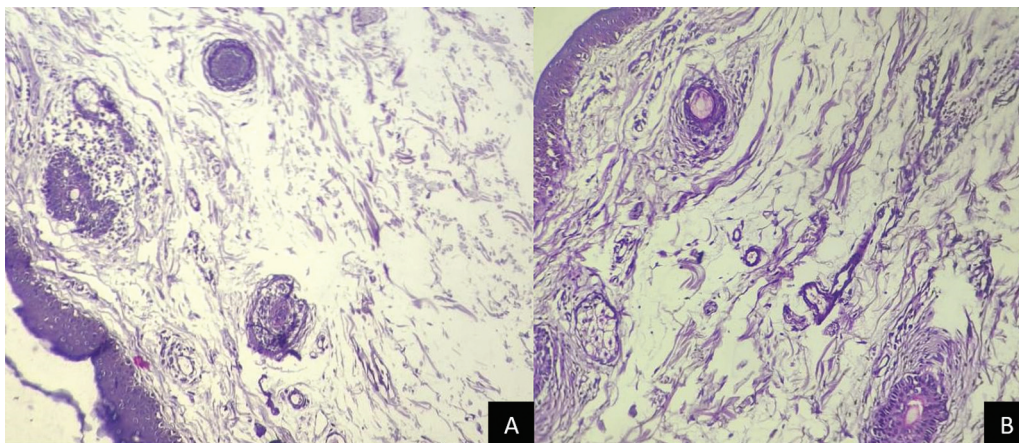


Fig. 2 (A) Normal epidermis with loose dermis and dilated vessels along with perifollicular inflammatory infiltrates (hematoxylin and eosin [H&E] 40 X). (B) Decreased density of elastin in reticular dermis (H&E 40 X).

changes that preceded the lid changes. The age of onset has been mentioned in 23 case reports, and it was below 20 years in 22 cases and 24 years in one case.

Blepharochalasis

Blepharochalasis is characterized by recurrent, self-limiting episodes of painless eyelid edema that results in atrophy of periorbital skin and boggy eyelids. This needs to be differentiated from dermatochalasis as the clinical manifestation of painless, sagging of eyelid skin may mimic blepharochalasis. The dermatochalasis is an involuntional change with redundant skin, contrarily underlying the blepharochalasis is recurrent edema of eyelids, and more often seen in adolescents.^{9,10} In absence of characteristic history, the clinical remembrance may make differentiation difficult, especially in elderly patients.¹¹ In this review of 42 case reports, 24 (57%) patients were aged below 20 years. What is essentially required to make a diagnosis of blepharochalasis is the history of recurring edema of the eyelids.¹² We noticed such history in 11 (26%) case reports, whereas another 6 (14%) mentioned it as progressive edema and in the rest 25 (60%) the onset was not mentioned. In our case initially, lid edema was episodic but then lid changes became progressive and permanent.

The episodes of eyelid edema in the early stage may be misdiagnosed as hereditary angioedema.^{8,13} Episodes of lid edema in blepharochalasis subside spontaneously to recur and does not respond to oral therapy with antihistaminic or steroid drug.^{5,6,13,14} Recurrent episodes of eyelid edema produce chronic changes that are often described as three clinically distinct stages.^{2,15}

What triggers eyelid edema in most cases is not known, but in a few cases, it has been correlated with some trigger such as a premenstrual period or exposure to Sun.^{16,17}

Double Lips

The upper lip mucosa has two transverse zones during development: the outer cutaneous (pars glabrosa) and inner mucosal (paras villosa) zones. In double lip, a tissue duplication occurs between the pars glabrosa and the pars villosa, which is more striking when patients smile.¹⁸ Therefore, the terminology "double lip" seems to be inappropriate because the excessive tissue is in pars villosa. In its original description also, Laffer described the upper lip as swollen particularly on its buccal side.¹ The upper lip is affected in most cases, though rarely the lower lip or both lips may be affected.¹⁹ The excessive tissue (or double lip) may be either congenital or acquired. The congenital form is thought to result from the persistence of the horizontal sulcus that separates the pars villosa and pars glabra at the 70 mm stage of fetal lip.²⁰ The acquired form is most often described with Laffer-Ascher syndrome, though the exact underlying etiology is not elucidated. In case described by Eisenstodt, the boy suffered a blow on the back of his head at the age of 7 years and subsequently suffered several episodes of eyelid edema until the age of 13 years when a double lip also appeared.²¹ Alvis extensively reviewed the literature on blepharochalasis published until 1935 and mentioned 23 cases of blephar-

ochalasis with double lip, including 17 cases by Ascher alone.¹² Blepharochalasis alone in the absence of double lips has been described as *forme fruste* of Ascher syndrome.

Thyroid Involvement

Ascher described thyroid enlargement in at least three cases of several described by him.¹² The discussions of published case reports put nontoxic thyroid involvement in 10 to 50% of cases.^{5-7,22,23} In our review of literature for case reports published in the English language, for which full text was accessible, the nontoxic thyroid involvement was seen in 14% (6/42) cases only. One case report had myxoedema associated with blepharochalasis and double lip in a 70-year-old female patient.⁴ The nontoxic goiter is thyroid gland enlargement not associated with any inflammation, neoplasia, or disturbance in thyroid function and may occur due to many causes including physiological goiter of puberty.¹⁸ Most cases described by Ascher were aged in their teens.²⁴ Among six cases we found during the literature review with nontoxic goiter, two were in their early teens and the other four were adults.^{6,11,22,25-27} Some of the case reports in which thyroid involvement was not observed described the syndrome complex as a *forme fruste* of Ascher syndrome. It is not clear whether the presence of thyroid enlargement is a constant or a necessary feature for diagnosis. Is enlarged thyroid an anecdotal finding or share a common pathological process yet not known? Nontoxic goiter may be autoimmune in origin also, but autoimmune thyroid diseases often have thyroid dysfunction.^{18,28} Eigel speculated that edema in these cases resulted from endocrine disturbances.¹² Antithyroid antibodies were tested negative in two case reports and positive in one.^{5,26,29} The thyroid involvement may occur even years after the appearance of blepharochalasis and double lip.^{26,30,31}

Embryonic Basis

Do the structures affected in Laffer-Ascher syndrome have any embryogenic linkage is not known. These structures are developed from the neural crest and mesoderm between weeks 6 and 9.³² The upper eyelid is developed from the frontonasal process derived from the neural crest and the lower eyelid is developed from the maxillary process. The upper lip is developed from the maxillary processes, the lateral nasal prominences and the intermaxillary segment, and the lower lip from the mandibular process. The maxillary and mandibular processes are derived from the first pharyngeal arch. The thyroid gland cells are derived from the fourth and fifth pharyngeal pouch.

Histopathological Changes

Histopathological changes seen in Laffer-Ascher syndrome characteristically affect mucosal elastic tissue.^{14,16,27,29} The changes described include epidermal thinning with increased pigmentation in the basal layer, nonspecific inflammatory cells infiltration with dilation of blood vessels in the dermis, and a decrease in elastic tissue.^{7,8,16,23,26} The reduced density of the elastin fibers in the papillary and reticular dermis suggestive of dermal elastolysis is characteristic.^{14,27,29}

Management

Treatment is offered for functional and cosmetic reasons. Characteristic changes of lips and eyelids are often the cause of social embarrassment.^{3,15,33,34} Nonsurgical treatment modalities that have been tried include oral prednisolone, antihistaminic, and dapsone. Oral antihistaminic or prednisolone therapy is not useful in resolving lid edema.^{6,7,13} Dapsone has been tried unsuccessfully to delay the onset of the syndrome.³⁵ Cosmetic blepharoplasty is done for eyelids correction, which involves excision of redundant skin leaving 10 mm margins.³⁶ The timing of surgery may be detrimental in relapse of blepharochalasis and should be avoided until the eyelid edema subsides.³⁷ The accessory lip excision is done by elliptical excision under general anesthesia with primary wound closure.^{7,22,23} Recurrence has not been reported after surgical intervention, though the maximum follow-up period in published cases was up to 1 year.^{13,17,33,34}

Conclusion

This review of the literature highlighted that there is a lack of consensus regarding terminology and clinical criteria for the diagnosis of Laffer-Ascher syndrome or Ascher syndrome. Should the terminology be restricted to clinical triad of blepharochalasis, double lips, and nongoiter thyroid involvement? Also, understanding about the pathogenesis of various manifestations and their genetic or developmental basis needs further studies.

Conflict of Interest
None declared.

References

- Laffler WB. Blepharochalasis: Report of a case of this trophoneurosis involving also the upper lip. *Cleveland Med J*. 1909;8:131–135
- Papanayotou PH, Hatziotis JC. Ascher's syndrome. Report of a case. *Oral Surg Oral Med Oral Pathol* 1973;35(04):467–471
- Scardovi S, Buneno L, Raffo M. Ascher syndrome: clinical case care and treatment. *Odontostomatologia* 2018;20:78–85
- Barnett ML, Bosshardt LL, Morgan AF. Double lip and double lip with blepharochalasis (Ascher's syndrome). *Oral Surg Oral Med Oral Pathol* 1972;34(05):727–733
- Dalmau J, Puig L, Roé E, Peramiqnel L, Pimentel CL, Alomar A. Blepharochalasia and double lip: diagnosis and treatment of Ascher's syndrome. *J Eur Acad Dermatol Venereol* 2006;20(10):1390–1391
- Chandravanshi SL, Mishra V. Ascher's syndrome: a rare case report. *Indian J Ophthalmol* 2015;63(03):264–267
- Santos PP, Alves PM, Freitas VS, Souza LB. Double lip surgical correction in Ascher's syndrome: diagnosis and treatment of a rare condition. *Clinics (São Paulo)* 2008;63(05):709–712
- Ruiz-Villaverde R, Anguita-Carazo JL, Sánchez-Cano D. Laffer-Ascher's syndrome mimicking hereditary angio-edema. *Int J Dermatol* 2009;48(08):914–915
- Tenzel RR, Stewart WB. Blepharo-confusion—blepharochalasis or dermatochalasis? *Arch Ophthalmol* 1978;96(05):911–912
- Koursh DM, Modjtahedi SP, Selva D, Leibovitch I. The blepharochalasis syndrome. *Surv Ophthalmol* 2009;54(02):235–244
- Ozdede M, Dere KA. Ascher syndrome: acquired double lower lip combined with epulis fissuratum. *J Craniofac Surg* 2020;31(06):e563–e565
- Alvis BY. Blepharochalasis. *Am J Ophthalmol* 1935;18:238–245
- Sanchez MR, Lee M, Moy JA, Ostreicher R. Ascher syndrome: a mimicker of acquired angioedema. *J Am Acad Dermatol* 1993;29(04):650–651
- Zhai Z, Song Z, Hao F, Zhong B, Shen Z. Ascher syndrome. *Zhonghua Pifuke Yixue Zazhi* 2015;33:26–28
- Mishra SS, Munde AD, Tambe SS, Farooqui AAJ. Ascher syndrome: a case report. *J Indian Acad Oral Med Radiol* 2020;32:405–407
- Mathew MS, Srinivasan R, Goyal JL, Ratnakar C, Garg BR, Reddy BS. Ascher's syndrome: an unusual case with entropion. *Int J Dermatol* 1992;31(10):710–712
- Simão TE, Tarazona MJ, Renaux P, et al. Ascher syndrome: diagnosis and surgical approach. *Surg Cosmet Dermatol* 2015;7:268–271
- Alkabban FM, Patel BC. Nontoxic Goiter. [Updated 2022 Aug 8]. In: StatPearls [Internet]. Treasure Island (FL): StatPearls Publishing; 2022 Jan-. Accessed September 27, 2023 at: <https://www.ncbi.nlm.nih.gov/books/NBK482274>
- Alkan A, Metin M. Maxillary double lip: report of two cases. *J Oral Sci* 2001;43(01):69–72
- Rintala AE. Congenital double lip and Ascher syndrome: II. Relationship to the lower lip sinus syndrome. *Br J Plast Surg* 1981;34(01):31–34
- Eisenstodt LW. Blepharochalasis with double upper lip. *Am J Ophthalmol* 1949;32(01):128–130
- Ali K. Ascher syndrome: a case report and review of the literature. *Oral Surg Oral Med Oral Pathol Oral Radiol Endod* 2007;103(02):e26–e28
- Beinhoff U, Piza-Katzer H. Double lip in a patient with Ascher's syndrome. *Eur J Plast Surg* 1998;21:370–373
- Findlay GH. Idiopathic enlargements of the lips: cheilitis granulomatosa, Ascher's syndrome and double lip. *Br J Dermatol* 1954;66(04):129–138
- Al-Hassani M, Carey B, Sanderson J, Hullah E, Escudier M. Ascher's syndrome: a rare cause of lip swelling. *Ann R Coll Surg Engl* 2020;102(08):e216–e218
- Gomez-Duaso AJ, Seoane J, Vazquez-Garcia J, Arjona C. Ascher syndrome: report of two cases. *J Oral Maxillofac Surg* 1997;55(01):88–90
- Varshney AP, Gahalaut P, Mishra N, Rastogi MK. Ascher syndrome. *Indian J Paediatr Dermatol* 2019;20:252–254
- Fröhlich E, Wahl R. Thyroid autoimmunity: role of anti-thyroid antibodies in thyroid and extra-thyroidal diseases. *Front Immunol* 2017;8:521
- Zhao ZL, Wang SM, Shao CY, Fu Y. Ascher syndrome: a rare case of blepharochalasis combined with double lip and Hashimoto's thyroiditis. *Int J Ophthalmol* 2019;12(06):1044–1046
- Parmar RC, Muranjan MN. A newly recognized syndrome with double upper and lower lip, hypertelorism, eyelid ptosis, blepharophimosis, and third finger clinodactyly. *Am J Med Genet A* 2004;124A(02):200–201
- Lebuisson D, Leroy L, Aron JJ, Jeaneau E, Guillard J. [Laffer-Ascher syndrome]. *J Fr Ophtalmol* 1978;1(12):751–752
- Vieira Carraro RR, Pacheco AS, Zanardi D, Souza Filho JJ. Do you know this syndrome? *An Bras Dermatol* 2006;81:287–289
- Ramesh BA. Ascher syndrome: Review of literature and case report. *Indian J Plast Surg* 2011;44(01):147–149
- Chidzonga MM, Mahomva L. Congenital double lower lip: report of a case. *Int J Paediatr Dent* 2006;16(06):448–449
- Moore KL, Persaud TVN. *Before We Are Born Essentials of Embryology and Birth Defects*. 4th ed. Philadelphia: Saunders; 1993
- Niamtu J III. Cosmetic blepharoplasty. *Atlas Oral Maxillofac Surg Clin North Am* 2004;12(01):91–130
- Stieglitz LN, Crawford JS. Blepharochalasis. *Am J Ophthalmol* 1974;77(01):100–102