




Factors Related to the Recurrence of Low-grade Gliomas

Fatores relacionados à recorrência dos gliomas de baixo grau

David Ilun Tseng Lin¹ Lindson Muhlmann¹ Fábio Pires Botta¹ Pedro Tadao Hamamoto Filho¹
Marco Antonio Zanini¹ Adriano Yacubian Fernandes¹ 

¹ Department of Neurology, Psychology and Psychiatry, Faculdade de Medicina de Botucatu, Universidade Estadual Paulista Julio de Mesquita Filho, São Paulo, SP, Brazil

Address for correspondence Adriano Yacubian Fernandes, MD, Departamento de Neurologia, Psicologia e Psiquiatria, Faculdade de Medicina de Botucatu, Universidade Estadual Paulista Julio de Mesquita Filho, Av. Prof. Montenegro s/n, Botucatu, SP, 18618-687, Brazil (e-mail: adriano.y.fernandes@unesp.br).

Arq Bras Neurocir 2023;42(4):e323–e327.

Abstract

Objective To identify the determining factors for reoperation in patients with low-grade gliomas, taking into account the degree of resection, and to analyze the histological aspects, observing possible transformations with signs of malignancy in the tissue samples.

Materials and Methods The sample consisted of 40 cases of low-grade glioma that were operated on at Hospital das Clínicas de Botucatu between 2013 and 2019.

Results The mean follow-up was of 37 months, and the sample was composed of 28 men and 12 women with a mean age at the first surgery of 43.1 ± 15.6 years. Epileptic seizures were observed in 31 (77.5%) patients. According to the histological classification, half of the patients presented oligodendroglioma (50%), of grade II in most cases (97.5%). Total or subtotal resection was achieved in 22 (55%) patients. Only one patient underwent radiotherapy, and two underwent chemotherapy. Reoperation was performed in 20 (50%) patients. The median interval between the first surgery and the reapproach was of 16 (range: 0–77) months. In the second approach, the histological classification was of astrocytoma in 4 (20%) cases, oligoastrocytoma in another 4 (20%), oligodendroglioma in 7 (35%), and glioblastoma in 5 (25%) cases. The only variable associated with the need for reoperation was the degree of resection after the first surgery ($p = 0.013$).

Conclusions Total resection of low-grade gliomas, when feasible, should be performed to avoid recurrence.

Keywords

- gliomas
- low grade
- microsurgery

Resumo

Objetivo Apontar os fatores determinantes para a reoperação em pacientes com gliomas de baixo grau considerando o grau de ressecção, e analisar os aspectos histológicos, observando possíveis transformações com sinais de malignidade nas amostras teciduais estudadas.

Materiais e Métodos A casuística foi composta por 40 casos de gliomas de baixo grau operados no Hospital das Clínicas de Botucatu de 2013 a 2019.

Resultados O tempo médio de seguimento de foi de 37 meses, sendo a amostra composta de 28 homens e 12 mulheres com idade média à primeira cirurgia de

Palavras-chave

- gliomas
- baixo grau
- microcirurgia

received
September 22, 2022
accepted
March 7, 2023
article published online
October 27, 2023

DOI <https://doi.org/10.1055/s-0043-1776283>.
ISSN 0103-5355.

© 2023. Sociedade Brasileira de Neurocirurgia. All rights reserved. This is an open access article published by Thieme under the terms of the Creative Commons Attribution-NonDerivative-NonCommercial-License, permitting copying and reproduction so long as the original work is given appropriate credit. Contents may not be used for commercial purposes, or adapted, remixed, transformed or built upon. (<https://creativecommons.org/licenses/by-nc-nd/4.0/>)
Thieme Revinter Publicações Ltda., Rua do Matoso 170, Rio de Janeiro, RJ, CEP 20270-135, Brazil

43,1 ± 15,6 anos. Crises epilépticas foram observadas em 31 pacientes (77,5%). Na classificação histológica, a metade dos pacientes apresentou oligodendroglioma (50%), sendo de grau II na maioria dos casos (97,5%). Ressecção total ou subtotal foi atingida 22 pacientes (55%). Apenas um paciente foi submetido a radioterapia, e dois, a quimioterapia. Reoperação foi realizada em 20 pacientes (50%). O intervalo mediano entre a primeira cirurgia e a reabordagem foi de 16 (variação: 0–77) meses; na segunda abordagem, a classificação histológica foi de astrocitoma em 4 casos (20%), oligoastrocitoma em outros 4 (20%), oligodendroglioma em 7 casos (35%), e glioblastoma em 5 casos (25%). A única variável que apresentou associação com a necessidade de reoperação foi o grau de ressecção da primeira cirurgia ($p = 0,013$).

Conclusão A ressecção total dos gliomas de baixo grau, quando factível, deve ser buscada com a finalidade de evitar a sua recorrência.

Introduction

Low-grade gliomas correspond to several histological types, with an emphasis on grade-II astrocytomas, oligodendrogliomas, and oligoastrocytomas.

With the advances and easier access to neuroimaging tests, early diagnosis as well as the diagnosis of asymptomatic patients, has increased. As a result, total or even supratotal resections were possible in a higher percentage of cases.

The results of the surgical treatment improved in terms of neurological and oncological aspects. In the oncological aspect, the patients started to present a lower rate of recurrence and malignancy. In the neurological aspect, fewer deficits and a lower incidence of epilepsy is observed in the postoperative period.¹

Tumor recurrence patterns are varied. They may occur after malignant transformation, at the surgical site, or even at a site distant from the original location.²

Despite surgical resection, which can be total, subtotal or biopsy alone, the incidence of postsurgical recurrence is high, and it depends on the extent of the resection, malignant transformation of the neoplastic tissue, and use or absence of adjuvant treatments, such as radiotherapy and chemotherapy.³ The adjuvant treatment with chemotherapy and radiotherapy can be indicated in cases of recurrence of low-grade gliomas submitted to a second surgery or not.⁴

For some authors,⁵ reoperation for recurrent low-grade glioma is strongly indicated and should be as radical as possible. For others,⁶ there is no strong evidence to recommend reoperation, and further clinical studies on the subject are required. The indicated treatments must be individualized considering the patient's age, the extent of the resection, the histological classification of the tumor, the quality of life, and the patient's preference.⁷

A detailed neuropsychological evaluation must always be performed in these patients, with a comparison of the pre- and postoperative periods, to enable the characterization of the initial deficits secondary to the tumor lesion itself and its postoperative alteration.⁸

Despite the well-defined goal of the surgery for low-grade glioma, the management of the cases of recurrence is still

controversial.⁹ The location of these tumors is a relevant factor in the indication of the first surgery and even in the case of recurrence. Some authors¹⁰ advocate the surgical approach even in complex areas from anatomical and functional points of view, such as the insula.

The recurrence patterns of low-grade glioma vary considerably, and the management at this stage of the evolution of the disease is complex, which reinforces the recommendation for the most radical resection possible in the first surgery.¹¹

Objective

The main objective of the present study was to determine the factors associated with tumor recurrence in low-grade glioma. The secondary objectives were to characterize the population of patients with recurrent glioma according to their demographic data, characterize, from a histopathological point of view, the recurrent low-grade gliomas according to the findings of the first surgical intervention, characterize the degree of resection (total resection, resection, subtotal resection, and biopsy alone) in the first surgical intervention, characterize, also from a histopathological point of view, the tumors observed in the second and occasional third surgical interventions, determine whether a supporting treatment was performed (chemotherapy and/or radiotherapy) between the first and second surgical interventions, and determine the interval between the first and second surgical interventions.

Materials and Methods

This retrospective cohort study was conducted in the Hospital of Clinics at Botucatu Medical School, São Paulo State University, Brazil. We recovered the data from the medical records of patients ($n = 40$) submitted to resection of low-grade gliomas between 2013 and 2019. Preoperative variables, such as age and sex, were the factors considered in the present study. Aspects of the first surgery, such as the degree of resection, the postoperative treatment, and the performance or absence of radiotherapy and chemotherapy, were

Table 1 Clinical features of the patients (n = 40)

Variable	
Male sex	28 (70%)
Age in years (mean ± SD)	43.1 ± 15.6
Seizures	31 (77.5%)
Side	
Right	18 (45%)
Left	19 (47.5%)
Midline	3 (4.5%)
Histological classification	
Astrocytoma	13 (32.5%)
Oligodendroglioma	20 (50%)
Oligoastrocytoma	13 (32.5%)
Degree of resection	
Total	8 (20%)
Subtotal	14 (35%)
Partial	11 (27.5%)
Biopsy	7 (17.5%)
Reoperation	20 (50%)

Abbreviation: SD, standard deviation.

also considered. The histopathological findings of the first and second surgeries were compared. The interval between the two surgeries was also evaluated.

Biopsy was performed by craniotomy and was considered a primary treatment. The degree of resection was classified by the surgeon. Reoperation was only considered when tumor growth was observed. Surgeries for residual tumors or surgery for complications of the procedure were not considered reoperations.

The distribution of the data was assessed using the Shapiro-Wilk test. Comparisons between the groups were performed using the *t*-test or Mann-Whitney tests according to data distribution. The Chi-squared and Fisher exact tests

were used to compare the categorical data. The level of statistical significance was set at 5%. The statistical analyses were performed using the IBM SPSS Statistics for MacBook (IBM Corp., Armonk, NY, United States) software, version 24.0. The present study was approved by the institutional Ethics in Research Committee under registration number 51843121.8.0000.5411.

Results

We included 40 patients (28 men and 12 women), with a mean follow-up of 37 months, and a mean age at the first surgery of 43.1 ± 15.6 years. Epileptic seizures were observed in 31 (77.5%) patients, and the right and left sides were similarly affected. According to the histological classification, half of patients had oligodendroglioma (50%), of grade II in most cases (97.5%). Total or subtotal resection was achieved in 22 (55%) patients. Only one patient underwent radiotherapy, and two underwent chemotherapy. Reoperation was performed in 20 (50%) patients. **Table 1** shows the patients' clinical and demographic data. No differences were observed regarding the histological classification and sex, age, tumor laterality, degree of resection, or need for reoperation (**Table 2**).

Comparing patients who did or did not require reoperation, there was no difference between sexes (*p* = 0.301), mean age (*p* = 0.517), and affected hemisphere (*p* = 1.00). The only variable associated with the need for reoperation was the degree of resection after the first surgery (*p* = 0.013), and none of the patients who underwent total resection required a reapproach (**Fig. 1**).

None of the patients submitted to complete resection were reapproached during the follow-up, and the proportion of patients who required a reapproach was higher among those who underwent partial resection or biopsy alone.

The median interval between the first surgery and the reapproach was of 16 (range: 0–77) months. In the second approach, the histological classification was of astrocytoma in 4 cases (20%), oligoastrocytoma in another 4 (20%), oligodendroglioma in 7 (35%), and glioblastoma in 5 (25%)

Table 2 Comparisons between clinical variables and histological classification of the gliomas

Variable	Astrocytoma (n = 13)	Oligodendroglioma (n = 20)	Oligoastrocytoma (n = 7)	p-value
Male sex	8 (61.5%)	16 (80%)	4 (57.1%)	0.467
Age in years (mean ± SD)	41.4 ± 17.2	46.4 ± 15.0	36.7 ± 13.8	0.337
Left hemisphere	6 (46.2%)	11 (50%)	2 (28.6%)	0.205
Degree of resection				
Total	3 (23.1%)	4 (20%)	1 (14.3%)	0.675
Subtotal	4 (30.8%)	7 (35%)	3 (42.9%)	
Partial	2 (15.4%)	6 (30%)	3 (42.9%)	
Biopsy	4 (30.8%)	3 (15%)	0 (0%)	
Reoperation	7 (53.8%)	8 (40%)	5 (71.4%)	0.340

Abbreviation: SD, standard deviation.

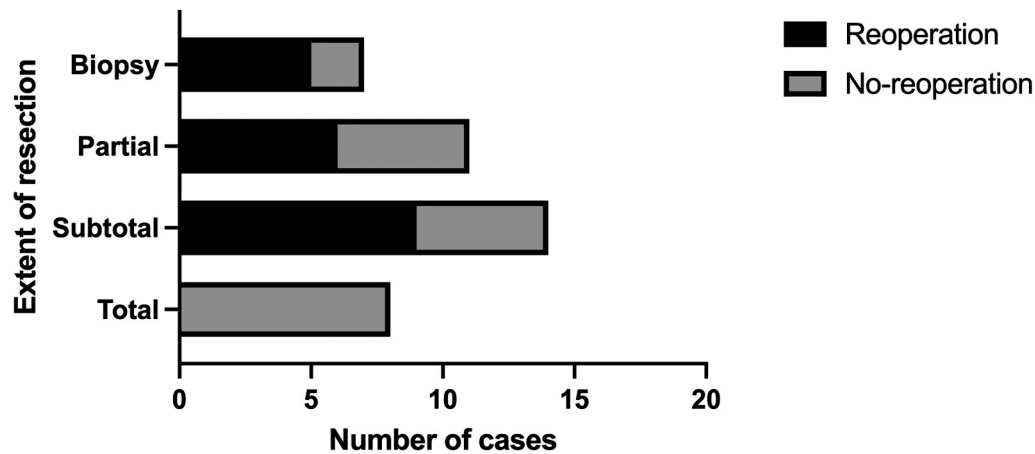


Fig. 1 Number of cases that required reoperation according to the degree of resection of the first surgery.

cases. As for the grades, 7 cases were grade II, 8 were grade III (40%), and 5 were grade IV.

No association was observed between the original histological classification and the change in grade ($p=0.494$). There was also no association between the degree of surgical resection and histological transformation ($p=0.425$).

Discussion

Low-grade gliomas account for 10% to 20% of all primary brain tumors. The median survival time is of 4.7 to 9.8 years. The aim of the treatment is to prolong survival while maintaining a good quality of life. Recent data^{1,5,7} have favored early surgical resection. Additional chemotherapy or radiation therapy is recommended for high-risk patients.¹²

From an epidemiological point of view, the present series differs from those in the literature¹³ because of the predominance of men, and it agrees with the literature considering the age of onset of symptoms (mostly in the beginning of the fifth decade of life). This is also in agreement with the literature because clinically, oligodendrogliomas present with epileptic seizures.^{14,15} In the present study, there was no predominance of a single cerebral hemisphere in the cases analyzed.

The treatment of low-grade gliomas aims to prevent recurrence and malignant transformation; knowing the determining factors of these events is of fundamental importance to determine the best treatment strategies.¹⁶ Diffuse low-grade gliomas can recur in different histological patterns and different degrees of malignancy. Radical surgery at the time of the initial diagnosis seems to determine a better prognosis for recurrence from a histopathological point of view.¹⁶

Regarding the histological type, most cases in the series were of grade-II oligodendroglioma, and cases of grade-II astrocytoma were less frequent. Histological classification has long guided the treatment of gliomas. However, classification through molecular biology has increased the knowledge of the nature of these tumors. The 2016 WHO classification integrates the histological and molecular findings of gliomas.¹⁷ Molecular analysis has only recently

been incorporated into our service; therefore, we did not present this analysis.

In the present series, the degree of resection was total in 20% of the cases, and none of them presented recurrence, corroborating the literature reports relating total resection to better prognoses.^{3,5}

Some authors¹⁸ have compared the performance of biopsy with surgical resection and observed better results in terms of survival and seizure control in patients undergoing more extensive surgeries. However, it should be considered that total resections are usually performed in gliomas located in non-eloquent areas, which eventually favors supratotal resection.

In the present series, regarding the interval between the first and second surgeries, the brevity of the period (16 months on average) should be highlighted, which may be related to the malignant transformation of gliomas to grades III (8 cases) and IV (5 cases). In cases of recurrence, histopathological transformation to grades of greater malignancy is very frequent (65% of the cases in the present series).

Radiotherapy and chemotherapy after the first surgery were performed in one and two patients respectively who had undergone partial or even total resection. Such complementary treatment is often indicated due to recurrence, regardless of tumor malignancy.¹² The absence of molecular biology analysis of the tumors, the small number of cases, and certain methodological aspects are limitations of this study.

Conclusion

Total resection of low-grade gliomas, when the tumor does not occupy eloquent areas of the brain, should be performed to prevent recurrence and provide a better prognosis for these patients.

Conflict of Interests

The authors have no conflict of interests to declare.

References

- Mandonnet E, Taillandier L, Duffau H. [Proposal of screening for diffuse low-grade gliomas in the population from 20 to 40years]. *Presse Med* 2017;46(10):911–920. Doi: 10.1016/j.lpm.2017.07.005

- 2 Ferracci FX, Michaud K, Duffau H. The landscape of postsurgical recurrence patterns in diffuse low-grade gliomas. *Crit Rev Oncol Hematol* 2019;138:148–155. Doi: 10.1016/j.critrevonc.2019.04.009
- 3 Jansen E, Hamisch C, Ruess D, et al. Observation after surgery for low grade glioma: long-term outcome in the light of the 2016 WHO classification. *J Neurooncol* 2019;145(03):501–507. Doi: 10.1007/s11060-019-03316-7
- 4 Spitaels J, Devriendt D, Sadeghi N, et al. Management of supratentorial recurrent low-grade glioma: A multidisciplinary experience in 35 adult patients. *Oncol Lett* 2017;14(03):2789–2795. Doi: 10.3892/ol.2017.6543
- 5 Uppstrom TJ, Singh R, Hadjigeorgiou GF, Magge R, Ramakrishna R. Repeat surgery for recurrent low-grade gliomas should be standard of care. *Clin Neurol Neurosurg* 2016;151:18–23. Doi: 10.1016/j.clineuro.2016.09.013
- 6 Nahed BV, Redjal N, Brat DJ, et al. Management of patients with recurrence of diffuse low grade glioma: A systematic review and evidence-based clinical practice guideline. *J Neurooncol* 2015; 125(03):609–630. Doi: 10.1007/s11060-015-1910-2
- 7 Oberheim Bush NA, Chang S. Treatment Strategies for Low-Grade Glioma in Adults. *J Oncol Pract* 2016;12(12):1235–1241. Doi: 10.1200/JOP.2016.018622
- 8 Duffau H. Is non-awake surgery for supratentorial adult low-grade glioma treatment still feasible? *Neurosurg Rev* 2018;41(01):133–139. Doi: 10.1007/s10143-017-0918-9
- 9 Chang J, Wang Y, Guo R, et al. The effect of operations in patients with recurrent diffuse low-grade glioma: A qualitative systematic review. *Clin Neurol Neurosurg* 2020;196:105973. Doi: 10.1016/j.clineuro.2020.105973
- 10 Morshed RA, Young JS, Han SJ, Hervey-Jumper SL, Berger MS. Perioperative outcomes following reoperation for recurrent insular gliomas. *J Neurosurg* 2018;131(02):467–473. Doi: 10.3171/2018.4.JNS18375
- 11 Fukuya Y, Ikuta S, Maruyama T, et al. Tumor recurrence patterns after surgical resection of intracranial low-grade gliomas. *J Neurooncol* 2019;144(03):519–528. Doi: 10.1007/s11060-019-03250-8
- 12 Kumthekar P, Raizer J, Singh S. Low-grade glioma. *Cancer Treat Res* 2015;163:75–87. Doi: 10.1007/978-3-319-12048-5_5
- 13 Khan MT, Prajapati B, Lakhina S, et al. Identification of gender-specific molecular differences in glioblastoma (GBM) and low-grade glioma (LGG) by the analysis of large transcriptomic and epigenomic datasets. *Front Oncol* 2021;11:699594. Doi: 10.3389/fonc.2021.699594
- 14 Rudà R, Bello L, Duffau H, Soffietti R. Seizures in low-grade gliomas: natural history, pathogenesis, and outcome after treatments. *Neuro-oncol* 2012;14(Suppl 4, Suppl 4):iv55–iv64. Doi: 10.1093/neuonc/nos199
- 15 Aiman W, Rayi A. Low Grade Gliomas. In: StatPearls [Internet]. Treasure Island (FL): StatPearls Publishing; 2022
- 16 Chaichana KL, McGirt MJ, Lathrop J, Olivi A, Quiñones-Hinojosa A. Recurrence and malignant degeneration after resection of adult hemispheric low-grade gliomas. *J Neurosurg* 2010;112(01): 10–17. Doi: 10.3171/2008.10.JNS08608
- 17 Perry A, Wesseling P. Histologic classification of gliomas. *Handb Clin Neurol* 2016;134:71–95. Doi: 10.1016/B978-0-12-802997-8.00005-0
- 18 Jiang B, Chaichana K, Veeravagu A, Chang SD, Black KL, Patil CG. Biopsy versus resection for the management of low-grade gliomas. *Cochrane Database Syst Rev* 2017;4(04):CD009319. Doi: 10.1002/14651858.CD009319.pub3