


Management of Brain Metastases: A Review of Novel Therapies

Shreyas Bellur, MD¹ Atulya Aman Khosla, MD¹ Ahmad Ozair, MD^{1,3}  Rupesh Kotecha, MD^{1,2}
Michael W. McDermott, MD^{2,4} Manmeet S. Ahluwalia, MD, MBA, FASCO^{1,2}

¹ Miami Cancer Institute, Baptist Health South Florida, Miami, Florida

² Herbert Wertheim College of Medicine, Florida International University, Miami, Florida

³ Bloomberg School of Public Health, Johns Hopkins University, Baltimore, Maryland

⁴ Miami Neuroscience Institute, Baptist Health South Florida, Miami, Florida

Address for correspondence Manmeet S. Ahluwalia, MD, MBA, FASCO, Fernandez Family Foundation Endowed Chair in Cancer Research, Chief of Medical Oncology, Chief Scientific Officer & Deputy Director, Miami Cancer Institute, Baptist Health South Florida, Professor of Translational Medicine, Herbert Wertheim College of Medicine, Florida International University, Miami, FL 33199-2156 (e-mail: manmeeta@baptisthealth.net).

Semin Neurol 2023;43:845–858.

Abstract

Brain metastases (BMs) represent the most common intracranial tumors in adults, and most commonly originate from lung, followed by breast, melanoma, kidney, and colorectal cancer. Management of BM is individualized based on the size and number of brain metastases, the extent of extracranial disease, the primary tumor subtype, neurological symptoms, and prior lines of therapy. Until recently, treatment strategies were limited to local therapies, like surgical resection and radiotherapy, the latter in the form of whole-brain radiotherapy or stereotactic radiosurgery. The next generation of local strategies includes laser interstitial thermal therapy, magnetic hyperthermic therapy, post-resection brachytherapy, and focused ultrasound. New targeted therapies and immunotherapies with documented intracranial activity have transformed clinical outcomes. Novel systemic therapies with intracranial utility include new anaplastic lymphoma kinase inhibitors like brigatinib and ensartinib; selective “rearranged during transfection” inhibitors like selpercatinib and pralsetinib; B-raf proto-oncogene inhibitors like encorafenib and vemurafenib; Kirsten rat sarcoma viral oncogene inhibitors like sotorasib and adagrasib; ROS1 gene rearrangement (ROS1) inhibitors, anti-neurotrophic tyrosine receptor kinase agents like larotrectinib and entrectinib; anti-human epidermal growth factor receptor 2/epidermal growth factor receptor exon 20 agent like poziotinib; and antibody–drug conjugates like trastuzumab-emtansine and trastuzumab-deruxtecan. This review highlights the modern multidisciplinary management of BM, emphasizing the integration of systemic and local therapies.

Keywords

- ▶ brain metastases
- ▶ precision oncology
- ▶ novel therapies
- ▶ future directions
- ▶ EGFR

Brain metastases (BMs) represent the most common intracranial malignancies in adults, accounting for up to 50% of all brain tumors.¹ The incidence of BM has been increasing in recent years, likely due to the availability of effective systemic therapies for primary cancers, the immunological

nature of the brain as a sanctuary site, along with advances in imaging. Among patients with solid tumors, 10 to 30% develop BM, with the highest rates seen in patients with lung cancer, breast cancer, melanoma, renal cell carcinoma, and colorectal carcinoma.² Across tumor types, the development

article published online
November 27, 2023

Issue Theme Neuro-oncology: Part 1;
Guest Editors: Lynne P. Taylor, MD,
FAAN, Tresa M. McGranahan, MD, PhD,
and Vyshak Alva Venur, MD

© 2023. Thieme. All rights reserved.
Thieme Medical Publishers, Inc.,
333 Seventh Avenue, 18th Floor,
New York, NY 10001, USA

DOI <https://doi.org/10.1055/s-0043-1776782>.
ISSN 0271-8235.

of BM confers a poorer prognosis, with survival time varying based on patient and disease characteristics.³ The blood–brain barrier (BBB) poses a significant challenge to drug delivery (► **Fig. 1**), and the tumor microenvironment governs the development, progression, and spread of BMs.⁴ BMs are heterogeneous entities, with survival associated with tumor histology, age, performance status, extent of extracranial disease, and genomic profile, among other factors. The prognosis may be calculated by the molecular-graded prognostic assessment (GPA) tool, which incorporates molecular profiling into the previously used diagnosis-GPA tool.^{5–7} A multivariable Cox proportional hazards regression was performed using various prognostic factors and treatments associated with survival for each primary site. The same group developed the GPA tool in 2008 based on 1960 patients from five randomized trials.^{3,8}

In the last two decades, the emergence of better therapeutic options contributing to better survival in combination with much more sensitive imaging modalities has led to increased

detection of BM. Treatment modalities have conventionally consisted of local therapy, including surgical resection, whole brain radiation therapy (WBRT), and stereotactic radiosurgery (SRS), while conventional chemotherapy was reserved for recurrent BM, although with poor efficacy.

However, over the past decade the widespread utilization of immunotherapies and targeted therapies have markedly improved treatment outcomes in individuals with BMs and led to the utilization of these agents in the upfront setting. The critical considerations that dictate the choice of therapy include the number, size, and extent of BM; the presence of CNS symptoms; patient performance status and overall health status; comorbid conditions; and the driver mutation profile of the tumor. Medical management depends on the molecular profile of the primary tumor and the BM. This article is a review of the management of BM, focusing primarily on medical management based on the origin of the primary tumor and novel therapies driving advances in clinical outcomes.

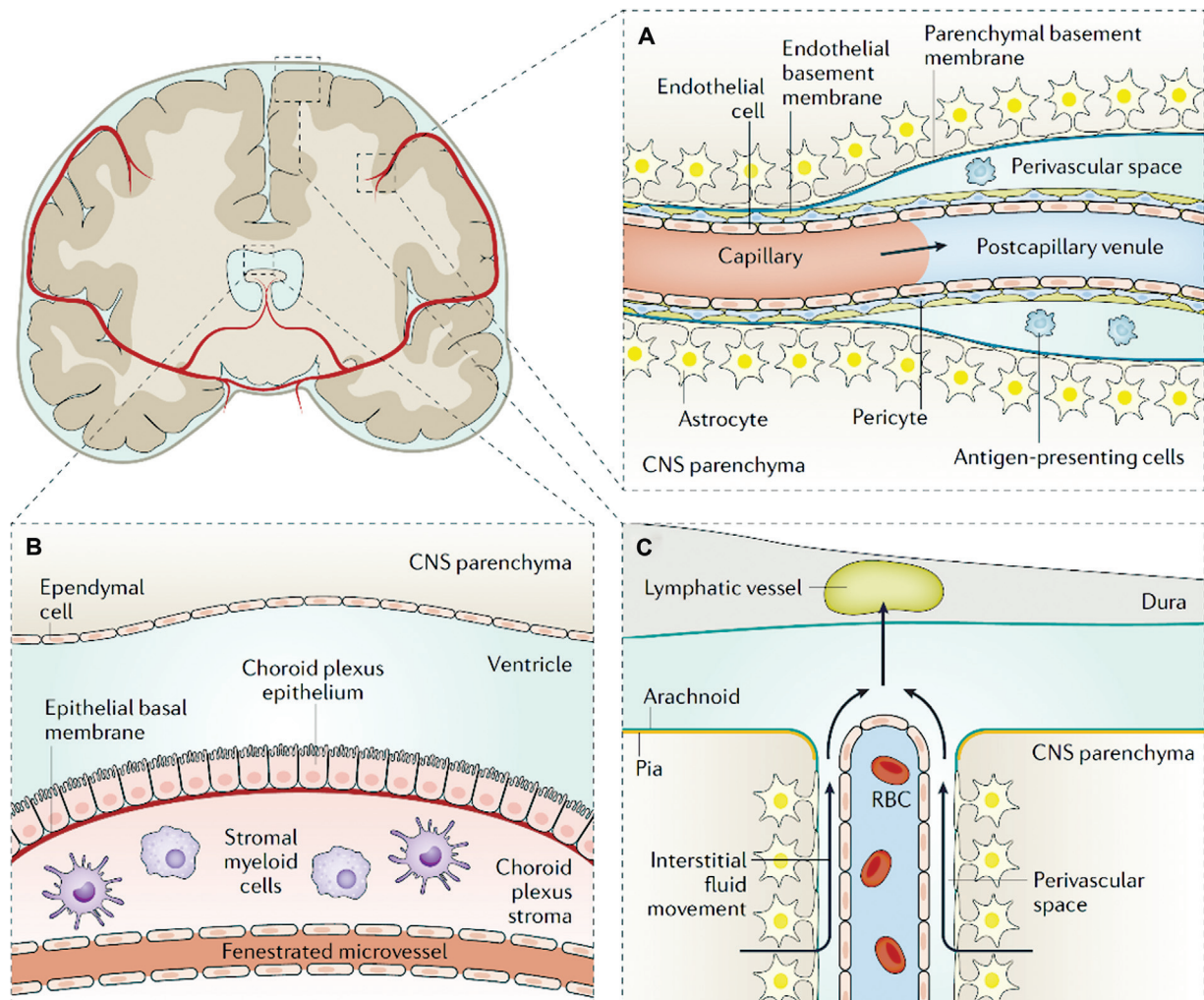


Fig. 1 Barriers present in the central nervous system (CNS). (A) The BBB primarily consists of endothelium connected by tight junctions along with increased efflux pumps. Additional contributions come from basement membranes, pericytes, and astrocytes. (B) The blood–CSF barrier is made by choroid plexus cells connected by tight junctions but having fenestrations to permit molecular movement. (C) The brain lymphatic system through which immune cells and CSF proteins are routed. (Reproduced with permission from Achrol AS, Rennert RC, Anders C, et al. Brain metastases. *Nat Rev Dis Primers* 2019;5(1):5.)

Symptomatic Management

Clinical Pearls

- Patients with brain metastases who have experienced a clinical seizure requiring treatment with an anticonvulsant should be treated with levetiracetam because it does not get metabolized through the liver's cytochrome P450 system and will be less likely to interfere with chemotherapy.
- There is guideline evidence against the use of antiepileptic medications for patients with brain metastases unless they have had a clinical seizure.

CNS symptoms may vary based on the size and location of the tumor. If present, the chief components of symptomatic management include reducing peritumoral edema and seizure treatment. Dexamethasone is the standard steroid used for managing peritumoral edema due to its high potency, CNS penetration, long half-life, and lack of significant mineralocorticoid activity.⁹ Seizures are less common in patients with BM than in primary brain tumors.¹⁰ For those who do develop seizures, standard first-line monotherapy, especially levetiracetam, is recommended because of its lack of hepatic enzyme induction which decreases the risk of drug–drug interactions with chemotherapy.¹¹ The use of antiepileptic therapy for “seizure prophylaxis” in patients who have never had a clinical seizure is not recommended for patients with BMs, as there is no evidence that it is effective.¹²

Local Management of Single Brain Metastasis

Clinical Pearls

- In patients with no systemic disease and/or with a large brain metastasis with mass effect, surgical resection is recommended if the tumor is accessible.
- Stereotactic radiosurgery (SRS) is as effective for prolonging OS as surgical resection.
- The use of postoperative SRS is preferred to WBRT due to superior cognitive outcomes even though the risk of tumor recurrence in the operative bed is higher.

Patients with single BM are often considered for upfront surgical resection, especially when symptomatic from mass effect and/or there is a lack of extracranial sites of disease (solitary BM).¹³ Surgery also helps diagnose histologically and provide mutational profiles of symptomatic BMs in patients with no discernible primary tumor. In addition, for large brain metastasis, retrospective data demonstrate improved local control from surgery compared with radiotherapy alone.¹⁴ These management principles are supported by the most recent American Society for Clinical Oncology (ASCO)–Society for Neuro-oncology (SNO)–American Society for Radiation Oncology (ASTRO) guidelines.¹⁵ In support of the importance of surgical resection is an older randomized controlled trial that demonstrated prolonged survival (40 vs. 15 weeks) and better quality of life in those treated with surgery and WBRT compared with WBRT

alone.¹⁶ Moreover, postoperative radiotherapy after surgical resection is important in reducing the risk of recurrence but does not impact overall survival (OS) or patient function.¹⁷

Radiation therapy has evolved with time (→ Fig. 2). Although postoperative WBRT was traditionally used after resection of brain metastasis, SRS targeted focally to the resection cavity is now more often performed.¹⁸ This is supported by two phase 3 trials, one supporting the role of postoperative SRS compared with surgical resection alone and a second comparing postoperative SRS to WBRT. In a phase 3 trial conducted at MD Anderson Cancer Center, Mahajan et al compared postoperative SRS with observation in 132 patients and demonstrated higher freedom from recurrence (72 vs. 43%) in favor of postoperative SRS.¹⁹ In the N107c trial comparing postoperative WBRT to postoperative SRS, the risk of cognitive deterioration was only 52% with SRS compared with 85% with WBRT. However, it is important to note that the SRS group had worse local control in the surgical bed at 6 months.^{20,21} Therefore, patient selection is critical to deciding on the optimal approach, and should include consideration of tumor histology, assessment of the extent of resection, cavity size, tumor location, and preoperative dural involvement. Recent trials are aimed at optimizing focal approaches to improve local disease control, such as fractionated SRS or the integration of preoperative SRS.

Primary SRS is the alternative to surgery or WBRT for small, inaccessible tumors less than 3 cm in maximum dimension. The decision to approach such tumors must be made individually, and an adequately powered randomized trial is needed to compare the two approaches. A Cochrane systematic review reported no definitive superiority of SRS versus surgical resection.²² The RTOG 9508 trial compared the combination of WBRT and SRS to WBRT in 333 enrolled patients, showing a significant survival advantage in the former group with a median survival of 6.5 versus 4.9 months. Patients enrolled in the combination arm also reported stable or improved Karnofsky performance status (KPS) at 6 months. Based on the results of this prespecified subgroup analysis, the study concluded that combination therapy improved functionality and survival for patients with single unresectable metastasis and suggested this approach in patients with two to three BMs.²³ ASTRO also strongly recommends SRS for limited BM in patients with an Eastern Cooperative Oncology Group (ECOG) functional score of 0 to 2.²⁴

Local Management of Multiple Brain Metastases

Clinical Pearls

- Multiple societies of neuro-oncologists, radiation oncologists, medical oncologists, and neurosurgeons agree that SRS is the treatment of choice for patients with multiple brain metastases (up to 20) due to improved memory function with an exception for patients with significant mass effect who would benefit from surgical resection.

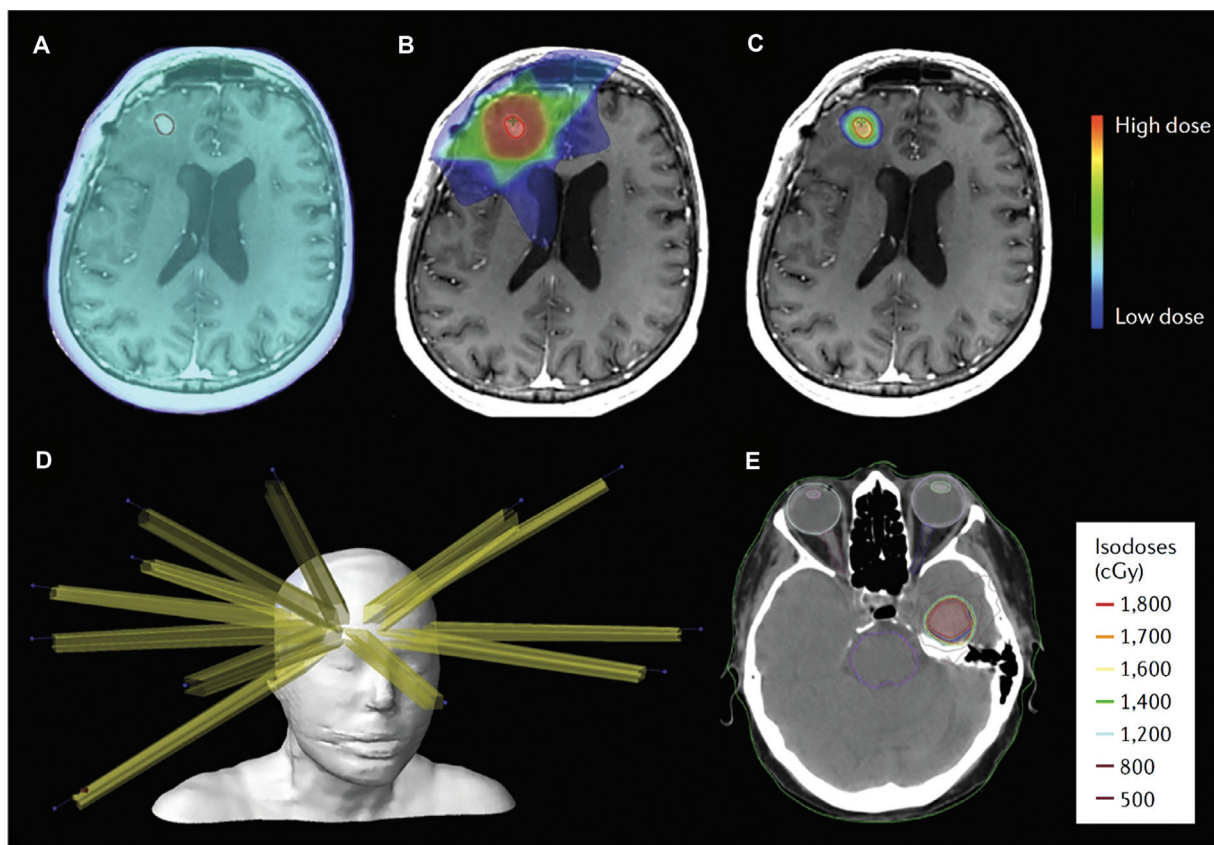


Fig. 2 Radiation therapy modalities for BMs. (A) Whole-brain radiation therapy. (B) Three-dimensional-conformal radiation therapy. (C–E) Stereotactic radiosurgery. (Reproduced with permission from Achrol AS, Rennert RC, Anders C, et al. Brain metastases. *Nat Rev Dis Primers* 2019;5(1):5.)

- Newer recommendations, for patients whose tumors have actionable mutations, include combinations of SRS-SRT with immunotherapy.

Multiple societies' consensus statements and guidelines, such as ASCO, SNO, and ASTRO, recommended that SRS be the initial therapy of choice for patients with one to four BMs, excluding small cell lung cancer.¹⁵ In addition, prospective registry and recent comparative data exist for treating multiple BMs with upfront SRS, which is included in the current NCCN guidelines (version 2.2022). For example, the JLGK0901 registry study included 208 patients with 5 to 10 BMs who underwent SRS and reported no significant survival differences from those with 2 to 4 BMs ($n = 531$).²⁵ An update of prospectively accumulated databases, including 1,515 patients with 5 to 10 tumors and 804 patients with 11 to 20 tumors treated with primary SRS, also demonstrated that carefully selected patients with multiple lesions (>10) could also be treated with upfront SRS.²⁶

Moreover, in carefully selected patients with actionable molecular alterations, survival may be unimpacted by BM number,²⁷ and therefore such patients may be considered for SRS given long-term expected survival. Li et al also presented the results of a randomized controlled trial of SRS versus WBRT for patients with 4 to 15 BMs, and a clinically meaningful and statistically significant benefit with SRS was

observed in memory function preservation.²⁸ It is also important to note that the Congress of Neurological Surgeons (CNS) recommended surgery in patients with multiple BM only when there is symptomatic mass effect and, if achieved, without inducing further neurological compromise.²⁹

Currently, major trials are underway on the integration and timing of SRS with systemic therapy. A systematic review of 77 abstracts with 6,384 patients showed the combination of SRS and systemic therapy (chemotherapy, immunotherapy, and targeted therapy) appears to be safe.³⁰ SRS delivers a large dose of RT in a single treatment, whereas stereotactic radiotherapy (SRT) fractionates that dose over multiple days. Chen et al showed that the concurrent administration of SRS-SRT with immune checkpoint inhibitors (ICIs) was associated with favorable survival (24.7 months) versus treating with SRS-SRT only (12.9 months) or SRS-SRT with non-concurrent immunotherapy (14.5 months).³¹

Novel Local Therapies

Clinical Pearls

- Laser interstitial thermal therapy, focused ultrasound, and magnetic hyperthermic therapy are newer alternatives to surgery but are just finding their roles, even in tertiary medical centers.

Laser Interstitial Thermal Therapy

Magnetic resonance-guided laser interstitial thermal therapy (MR-LITT) is an alternative to traditional surgical resection for certain metastatic tumors. The laser ablation of abnormal neurological tissue using robotic NeuroBlate system (LAANTERN) study is an ongoing trial that is studying the efficacy of LITT by collecting real-world outcomes and quality-of-life (QoL) data of enrolled patients. The investigators analyzed 223 patients across 14 centers, with 92 having metastatic disease. Presently, the results show that LITT improves QoL from the baseline. OS in the enrolled population was similar to those with primarily recurrent disease studied previously.³²

The Laser Ablation after Stereotactic Radiosurgery (LAASR) trial evaluated LITT after SRS in 20 patients with recurrent BM and 19 with proven radiation necrosis. PFS and OS rates at 26 weeks were 74 and 72%, respectively, concluding that LITT, after SRS stabilized KPS, maintained neurocognition and quality of life.³³ Shah et al extensively studied the application of LITT on brain tumors and found that the PFS in patients with BM was the longest at 55.9 months compared with patients with primary brain tumors.³⁴ An important predictor of recurrence is incomplete ablation.³⁵ Tumor control rates for recurrent BM reached 80% in one systematic review.³⁶ LITT also increases the permeability of the BBB, with the highest permeability within the first 1 to 3 weeks post-LITT.³⁷ This might facilitate effective drug permeation and delivery.

Focused Ultrasound

Focused ultrasound is a noninvasive, non-radiation-involving strategy where both high-intensity and low-intensity options are being explored. High-intensity focused ultrasound can perform local ablation, although this has yet to become standard of care. Low-intensity focused ultrasound (LIFU) has emerged as a promising technique for enhancing systemic drug delivery in brain metastases by transiently disrupting the BBB.³⁸ This noninvasive method utilizes precisely targeted ultrasound waves with acoustic feedback to induce mechanical effects at the cellular level, resulting in localized BBB disruption. Work is needed to identify the most optimal integration of systemic and local therapies with targeted and immune therapies to enhance their efficacy in brain metastases. Hence, FDA-approval intent clinical trials are underway studying combining MR-guided LIFU with systemic therapies.^{38,39}

Magnetic Hyperthermic Therapy

Magnetic hyperthermic therapy (MHT) uses magnetic nanoparticles that convert electromagnetism to heat by an alternating magnetic field. MHT is a novel technique that can prove to be a promising hyperthermic therapy. It has been studied in clinical trials in glioblastoma multiforme (GBM). In one study, 59 patients with recurrent GBM underwent MHT with RT. It showed that MHT with a reduced radiation dose was safe, leading to longer OS since the first tumor recurrence.⁴⁰ Novel techniques currently being studied in

vitro include targeted delivery of photothermal agents using antibody or aptamer conjugation.⁴¹

Systemic Therapies

Clinical Pearls

- For each type of solid tumor cancer diagnosis, there are increasingly available systemic therapies that can cross the BBB and help improve the tumor control rates beyond those provided by focused neurosurgical and radiation therapies.

The role of novel systemic therapies in the treatment of brain metastases is evolving and holds promise for improving outcomes in patients with this challenging condition. Outcomes of systemic therapy are evaluated using OS or PFS, or intracranial objective response rate (iORR). Novel systemic therapies have demonstrated the ability to cross the BBB and exert their effects directly on BM. Immunotherapies and antiangiogenic agents have demonstrated the potential to modulate the tumor microenvironment, enhancing the immune response or inhibiting blood vessel formation, respectively. These approaches may improve treatment efficacy in brain metastases.

Systemic therapies can be combined with local therapies to maximize treatment effectiveness. For example, systemic therapies may be administered alongside RT to enhance tumor response or sensitize tumor cells to radiation. By utilizing a multimodal treatment approach, novel systemic therapies can complement existing local therapies and potentially improve outcomes. Discussed below are systemic therapies categorized by the primary tumor site of origin; however, tissue-agnostic driver mutations are being increasingly recognized.

Systemic Therapies for Brain Metastases from Lung Cancer

Clinical Pearls

- Epidermal growth factor receptor (EGFR) mutation is an important driver of lung cancer and is present much more commonly in Hispanic and Asian patients than in Caucasians.
- EGFR is a very “druggable” target to erlotinib or gefitinib which can produce more than an 80% partial response (PR) rate in the tumor.
- Patients whose tumors harbor BRAFv600 mutated BM from non-small cell lung cancer (NSCLC) can be treated with dabrafenib/trametinib.
- Programmed death ligand 1 protein expression is an important biomarker that can predict tumor response to immunotherapy.

Chemotherapy

Conventional cytotoxic therapies have historically demonstrated limited results in managing BMs, secondary to the inability of traditional cytotoxic drugs to cross the BBB. The use of cisplatin, paclitaxel, and pemetrexed has been limited

to refractory cases, owing to substantial side effects and limited efficacy.^{42,43} Although practice-changing advances in conventional chemotherapy have been limited, a few exciting therapies are on the horizon. Patupilone is a novel microtubule disruptor that can penetrate the BBB. Patupilone conferred a median OS of 8.8 months, 65% survival at 6 months, and a progression-free survival rate at 9 weeks of 36% in 49 pretreated NSCLC BM patients.⁴⁴

Targeted Therapies

Previously, the biomarker profiles of the primary tumor and the brain metastases were used for prognostication but did not guide management. However, in the modern era, a molecular profile of brain metastases permits the effective utilization of various targeted therapies and immunotherapies. Targeted therapies specifically aim at inhibiting the activity of driver mutations essential for tumor growth, reducing systemic toxicity. These therapies have been driven by genomic profiling, initially only of the primary tumor but later also of the BM (►Fig. 3; ►Table 1).

Epidermal Growth Factor Receptor

EGFR mutations are common in lung cancer, accounting for around 15% of tumors in Caucasian patients and 25 to 50% in Hispanic and Asian patients.^{45,46} Early reports of the activity of tyrosine kinase inhibitors that included four NSCLC patients with BM treated with erlotinib revealed two with PR and two with stable disease (SD). A phase II study prospectively evaluated EGFR mutant NSCLC patients treated with erlotinib or gefitinib and noted that 83% achieved a PR and 11% achieved a SD without a statistically significant difference in PFS or OS.⁴⁷⁻⁵²

Anaplastic Lymphoma Kinase

Anaplastic lymphoma kinase (ALK) mutations occur in ~5% of NSCLC cases. ALK inhibition has led to breakthrough improvements in the survival of patients with ALK-mutant NSCLC with brain metastases, previously a terminal disease.⁵³ Novel ALK inhibitors being utilized include crizotinib, alectinib, brigatinib, and lorlatinib, with ensartinib the latest agent on the horizon.⁵⁴⁻⁵⁹

RET Mutations

RET mutations are rare and found in 1 to 2% of cases of NSCLC, particularly the adenocarcinomatous histology.⁶⁰⁻⁶²

BRAF Mutations

Five percent to 8% of NSCLC is driven by BRAF mutations. Although BRAFv600E mutations are present in 90% of solid tumors, it accounts only for half of the BRAF mutations.⁴⁵ Complete intracranial response in BRAFv600 mutated BM from NSCLC was seen with the combination of dabrafenib, a BRAF inhibitor, with trametinib, a MEK inhibitor in one patient with treatment-naïve asymptomatic non-measurable BM. The RECIST 1.1 CNS evaluation criteria were employed.⁶³ Encorafenib and binimetinib are currently being tested in the PHAROS phase 2 trial.⁶⁴

KRAS Mutations

KRAS mutations are the second most common mutations in NSCLC, accounting for up to 20 to 25% of cases of NSCLC.⁶⁵ KRAS was historically considered undruggable; however, novel breakthrough anti-KRAS agents sotorasib and adagrasib have demonstrated efficacy, including for brain metastases.⁶⁶⁻⁶⁹

MET Mutations

MET mutations are rare and found in less than 5% of patients with NSCLC.^{45,70}

ROS-1 Mutations

Brain metastases are found in 19 to 36% of ROS1-positive NSCLC patients at diagnosis.⁷¹ ROS-1 mutations are present in 1 to 2% of patients with NSCLC.^{45,72-74}

HER2/EGFR Exon 20 Insertions

About 0.3 to 3.7% of patients with NSCLC harbor EGFR exon 20 insertion mutations, while 2 to 4% harbor the HER2 mutations, with EGFR exon 20 insertions consisting of 90%.⁷⁵⁻⁷⁷

NTRK Mutations

NTRK mutations drive less than 1% of NSCLC cases.⁴⁵ NTRK inhibitors such as larotrectinib and entrectinib have been used as targeted therapy in patients harboring this driver mutation.⁷⁸⁻⁸⁰

Immunotherapy

Goldberg et al demonstrated intracranial response in 42 patients with BM with positive programmed death ligand 1 (PD-L1) expression. The iORR was 29.7% in those with PD-L1 \geq 1% ($n = 37$) and 0% in those with PD-L1 $<$ 1% ($n = 5$) using modified RECIST. The OS rates at 1 and 2 years were 40 and 34%, respectively.⁸¹ Frost et al demonstrated that this response was not in frail patients with symptomatic BMs.⁸² Atezolizumab and durvalumab can also be effective.^{83,84}

Systemic Therapies for Brain Metastases from Breast Cancer

HER2-Positive Breast Cancer (HER2 +)

Clinical Pearls

- Estrogen and progesterone receptors are important in the growth of some breast cancers. These are termed hormone receptor+ (HR+).
- The HER2 gene makes the HER2 protein which also drives breast cancer cells to grow and there are targeted therapies toward the HER2 receptors which can be utilized.
- Breast cancer types are characterized by the presence or absence of both HER2 and HR.
- "Triple negative" breast cancer means that ER, PR, and HER2 are not active within the tumor cell. These make up ~10% of breast cancers and are very refractory to treatment.

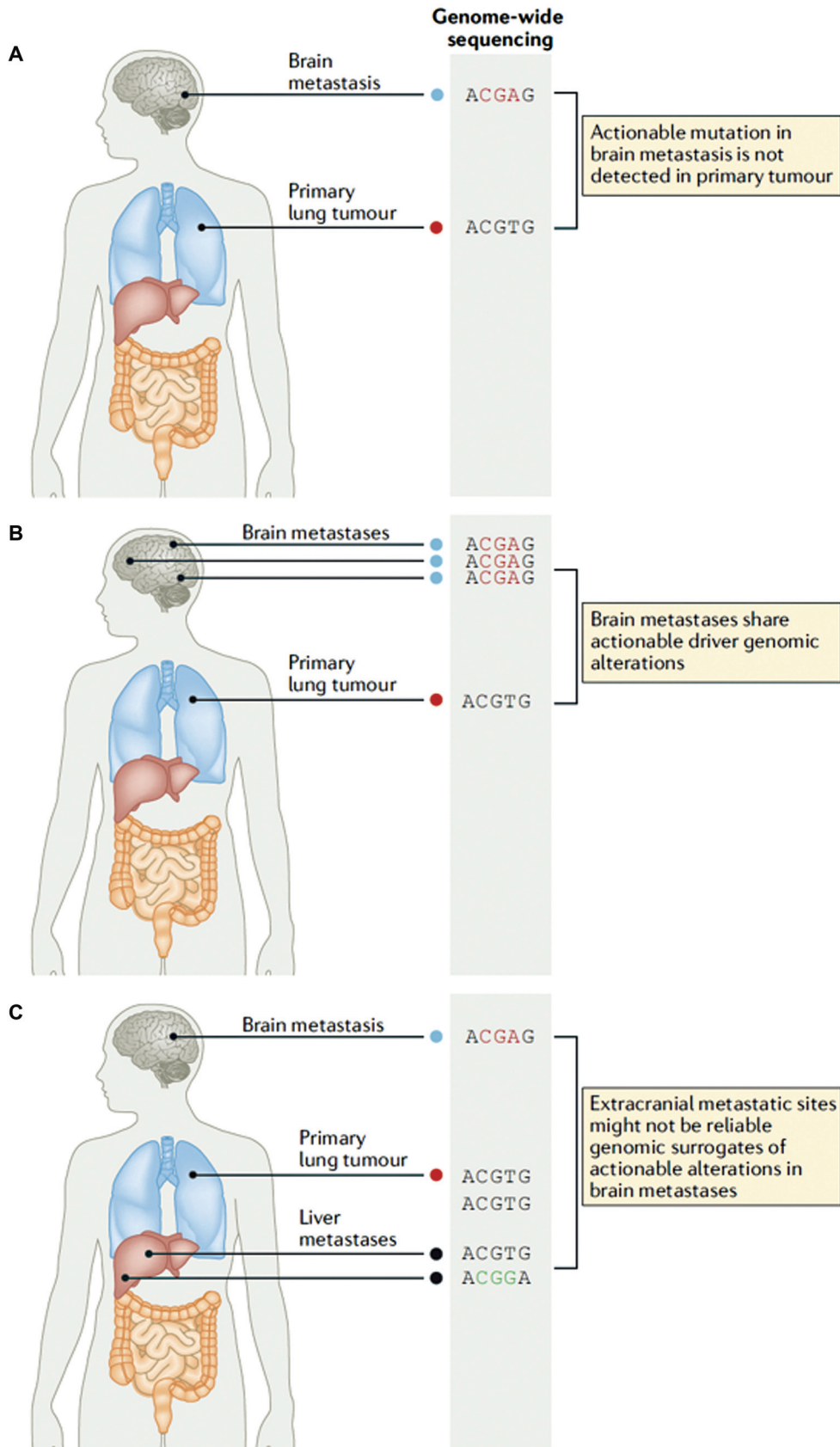


Fig. 3 Genetic profiling of the primary tumor site in lung cancer and of the brain metastases. (Reproduced with permission from Suh JH, Kotecha R, Chao ST, Ahluwalia MS, Sahgal A, Chang EL. Current approaches to the management of brain metastases. *Nat Rev Clin Oncol* 2020;17(5):279–299.)

This document was downloaded for personal use only. Unauthorized distribution is strictly prohibited.

Table 1 Targeted therapy used in brain metastases

Driver mutation	Incidence of BM	Targeted therapy
Lung cancer		
EGFR	15–50%	Osimertinib, erlotinib, gefitinib
KRAS	20–25%	Sotorasib, adagrasib
ALK	5–6%	Alectinib, brigatinib, lorlatinib, ceritinib, crizotinib
MET exon 14	2–5%	Capmatinib, tepotinib
BRAF	1–3%	Dabrafenib + trametinib
HER2	1–3%	Trastuzumab, pertuzumab
RET	1–2%	Selpercatinib, pralsetinib
ROS-1	1–2%	Entrectinib, ensartinib, repotrectinib
NTRK	0.1–0.9%	Larotrectinib, entrectinib
Breast cancer		
HER2+	9–12%	Trastuzumab, T-DM1, T-DXd, pertuzumab, tucatinib, lapatinib, neratinib
HER2– HR+	68%	Tamoxifen
Triple-negative	10%	Avelumab, pembrolizumab, atezolizumab
Melanoma		
BRAF/MEK	50%	Vemurafenib, dabrafenib + trametinib, encorafenib + binimetinib

Abbreviations: ALK, anaplastic lymphoma kinase; BM, brain metastasis; EGFR, epidermal growth factor receptor.

The HER2 gene is human EGFR2 which makes the HER2 protein that drives breast cancer cells to grow. HRs are estrogen and progesterone. Breast cancer incidence, therefore, is based on molecular subtype and is divided into HER2 +/HR +, HER2 –/HR +, HER2 +/HR –, and triple-negative breast cancer (meaning HER2, estrogen, and progesterone receptors) HER2 –/HR –. The incidence of HR+ breast cancer is roughly 68%, and HER2 + BC is 9 to 12%.⁸⁵

Hormone therapy with tamoxifen is standard of care for patients with HR+ breast cancer brain metastases (BCBM), mainly for patients with estrogen receptor-positive BC.⁸⁶ The tumor microenvironment of microglia is crucial to developing brain metastases.^{87,88} The presence of these microglia aids the tumor in spreading as the lack of them inhibits dissemination.⁸⁹ Tamoxifen modulates these microglia, thereby suppressing growth and spread.⁹⁰ A retrospective study of 198 patients with HR+ BCBM reported a higher overall median survival in those receiving hormone therapy –15 versus 4 months for those who did not.⁹¹

The recent development of targeted therapies toward HER2 receptors and tyrosine kinase has been significant in treating HER2 + BC. However, the treatment of HER2 + BCBM needs further exploration. Currently, the supportive evidence of the efficacy of targeted therapies is mainly retrospective. Recent advancements in immunohistochemistry led to a new subclass of HER2 + cancers: HER2– “low”; these cells have low expression of HER2. Antibody–drug conjugates like trastuzumab–deruxtecan (T-DXd) are helpful in their treatment.⁹²

Trastuzumab is a monoclonal antibody that blocks HER2 receptors halting tumor cell growth and is first-line therapy in HER2 + BC.⁹³ There is limited evidence of trastuzumab's efficacy in treating BCBM. A retrospective analysis of 251

patients with HER2 + BC found that trastuzumab delayed the onset of BMs and prolonged survival due to control of the primary disease.⁹⁴ The PATRICIA trial evaluated the efficacy of high-dose trastuzumab with pertuzumab in 40 pretreated BMs. Phase II showed that 68 and 51% demonstrated clinical benefit at 4 and 6 months, respectively, and an iORR of 11% in patients with measurable BMs ($n = 37$).⁹⁵

Trastuzumab–emtansine (T-DM1) is an antibody–drug conjugate that has not yet been tested in clinical trials focusing exclusively on patients with BCBM. There is evidence of efficacy in successfully treating BMs from retrospective analyses and post-approval clinical trials.^{96,97} There is an extensive literature for other agents that have also shown some activity in breast cancer.^{95,98–109}

Triple Negative Breast Cancer

Triple negative breast cancer accounts for 10% of breast cancer cases.⁸⁵ Most studies that have evaluated immunotherapy in breast cancer excluded BMs owing to poor prognosis and limited penetration across the BBB.^{110–112}

Systemic Therapies for Brain Metastases from Melanoma

Clinical Pearls

- Just as in lung cancer, patients whose tumors harbor BRAFv600 mutated BM from melanoma can be treated with dabrafenib/trametinib.
- Immunotherapies with ipilimumab and/or nivolumab can be very important in treating BM from melanoma and was successful in creating an OS of more than 80% at 9 months

which is markedly improved over historical 2- to 3-month control rates from radiation therapy.

BRAF is a human gene that creates a protein called B-raf. Genetic profiling of melanomas identified BRAF mutations in almost 50% of cases, of which 90% harbor BRAFV600E mutations. The BRAF oncogene is made particularly active by the V600E mutation which can lead to uncontrolled tumor growth.¹¹³ Melanoma with brain metastases (MBMs) are treated with targeted therapy and immunotherapy.

Chemotherapy

Chemotherapy has been shown to have no significant role in BMs from melanomas, even when used with RT. Temozolomide and fotemustine combined with WBRT have neither demonstrated clinically significant tumor activity nor improved survival.^{114,115}

Targeted Therapies: BRAF + MEK Inhibition

The mitogen-activated extracellular signal-regulated kinase (MEK) is a very well-known oncogenic driver in the cancer pathway. In targeted therapy for melanoma brain metastases, BRAF with or without MEK inhibition has emerged as the promising approach. BRAF inhibitors include vemurafenib, dabrafenib, and encorafenib.^{116–123}

Immunotherapy

ICIs have been a pillar in treating MBMs. Ipilimumab is a cytotoxic T-lymphocyte-associated protein 4 (CTLA-4) in-

hibitor that allows cytotoxic T lymphocytes to recognize tumor antigens and destroy tumor cells.¹²⁴ A phase II trial reported the efficacy of ipilimumab in 51 patients with MBM who were asymptomatic and not on steroids and 21 patients who were symptomatic on a stable dose of steroids. The iORR at 12 weeks for the former group was 16 versus 5% in the latter group, also concluding that ipilimumab shows activity in patients with small brain metastases. This study used the modified World Health Organization (mWHO) and the immune-related response criteria (irRC).¹²⁵ The CheckMate 204 trial reported the efficacy of combining ipilimumab with nivolumab, a PD-1 inhibitor. Among 94 patients, the iORR was 55%. The PFS was 64.2% at 6 months and 59.5% at 9 months. The OS rates at 6 and 9 months were 92.3 and 82.8%, respectively.¹²⁶

The ABC trial assessed the above combination compared with nivolumab monotherapy in 79 patients across three cohorts. Thirty-nine belonged to the treatment arm, 27 to the control arm, and 16 who failed local therapy or had symptomatic BMs or leptomeningeal disease. The iORRs were 45, 20, and 5% in the three groups, respectively.¹²⁷ Meanwhile, Kluger et al studied the efficacy of pembrolizumab in MBMs and concluded that pembrolizumab is active in MBMs with an acceptable toxicity profile. Twenty-six percent of the patients enrolled had a clinical response. The PFS and OS were 2 and 17 months, respectively. Forty-eight percent of the 23 patients were alive at the end of 1 year.¹²⁸ The trials mentioned earlier used the RECIST 1.1 criteria.

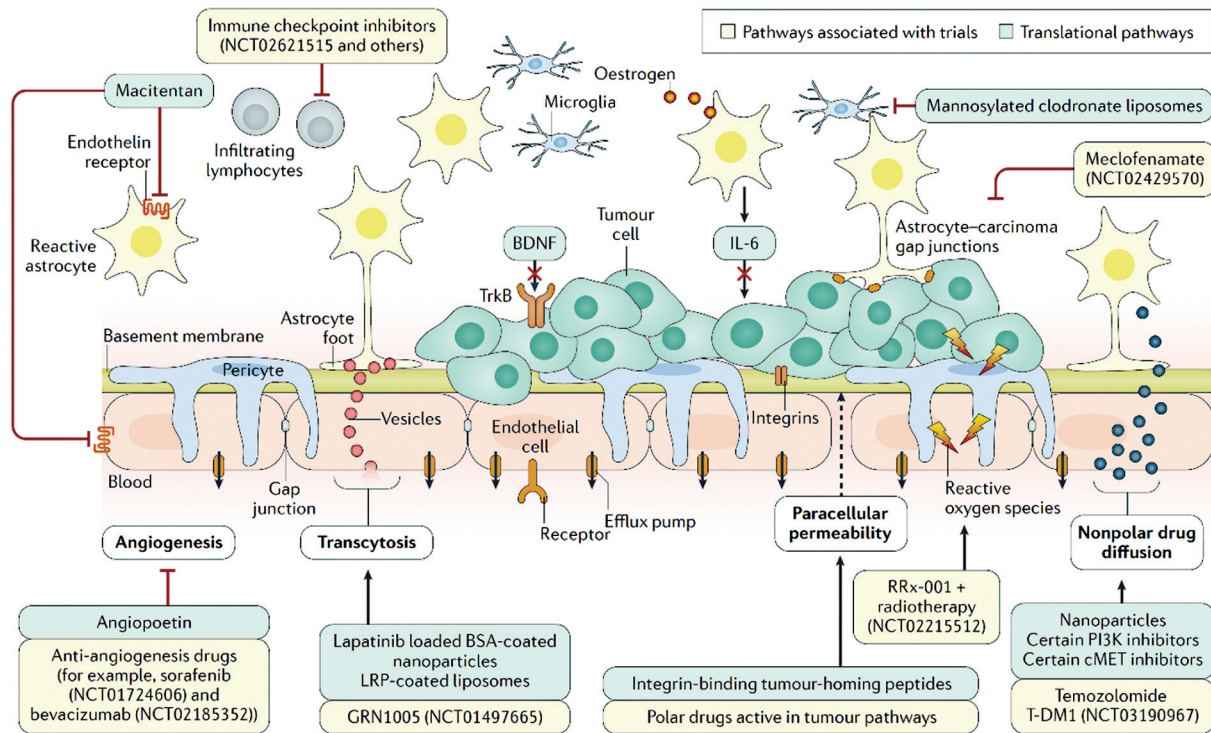


Fig. 4 Potential targets for systemic therapies for brain metastases, along with currently promising drugs in the pipeline against them. (Reproduced with permission from Achrol AS, Rennert RC, Anders C, et al. Brain metastases. Nat Rev Dis Primers 2019;5(1):5.)

This document was downloaded for personal use only. Unauthorized distribution is strictly prohibited.

Future Directions

Potential Targets and Future Systemic Therapies

Because of advances in our understanding of the pathogenesis and mechanisms of tumor resistance for BM, especially in the tumor microenvironment, several potential targets have been identified and many systemic therapies are on the horizon, as summarized in ►Fig. 4.

Conclusions

The incidence of brain metastases is likely to continue to increase due to the aging population, longer survival of cancer patients, and the availability of more effective systemic therapies. The intracranial efficacy of local and systemic treatments has been well-demonstrated. Despite this, the prognosis for people diagnosed with brain metastases remains poor. Ongoing trials may help identify the optimal integration of systemic and local therapies with targeted therapies and immunotherapy. Multi-institutional collaborations remain key to pooling translational and clinical expertise and pursuing large randomized controlled trials.

Author Contributions

S.B: Conceptualization, methodology, original draft preparation, revising the manuscript, submission. A.A.K: Conceptualization, methodology, original draft preparation, revising the manuscript. A.O: Conceptualization, methodology, original draft preparation, revising the manuscript. R.K: Conceptualization, revising the manuscript. M.W.McD: Conceptualization, revising the manuscript. M.S.A: Conceptualization, revising the manuscript, supervision.

Funding

None.

Conflict of Interest

M.S.A. has provided updated disclosures that encompass a range of professional involvements. In terms of grants, he has received support from Seagen. Additionally, his consultations extend to various organizations, including but not limited to Bayer, Novocure, Kiyatec, Insightec, GSK, Xofig, Nuvation, Cellularity, SDP Oncology, Apollomics, Prelude, Janssen, Tocagen, Voyager Therapeutics, Viewray, Caris Lifesciences, Pyramid Biosciences, Varian Medical Systems, Cairn Therapeutics, Anheart Therapeutics, Theraguix, Menarini Ricerche, Sumitomo Pharma Oncology, Autem therapeutics, and GT Medical Technologies. Furthermore, he serves on the Scientific Advisory Board of Cairn Therapeutics, Pyramid Biosciences, Modifi biosciences, and Bugworks. Additionally, his stock holdings include shares in Mimivax, Cytodyn, MedInnovate Advisors LLC, and Trisalus Lifesciences. These disclosures aim to provide transparency regarding his professional engagements and affiliations.

References

- Ostrom QT, Price M, Neff C, et al. CBTRUS Statistical Report: primary brain and other central nervous system tumors diagnosed in the United States in 2015–2019. *Neuro-oncol* 2022;24 (suppl 5):v1–v95
- Barnholtz-Sloan JS, Sloan AE, Davis FG, Vigneau FD, Lai P, Sawaya RE. Incidence proportions of brain metastases in patients diagnosed (1973 to 2001) in the Metropolitan Detroit Cancer Surveillance System. *J Clin Oncol* 2004;22(14): 2865–2872
- Sperduto PW, Mesko S, Li J, et al. Survival in patients with brain metastases: summary report on the updated diagnosis-specific graded prognostic assessment and definition of the eligibility quotient. *J Clin Oncol* 2020;38(32):3773–3784
- Arvanitis CD, Ferraro GB, Jain RK. The blood-brain barrier and blood-tumour barrier in brain tumours and metastases. *Nat Rev Cancer* 2020;20(01):26–41
- Sperduto PW, Yang TJ, Beal K, et al. Estimating survival in patients with lung cancer and brain metastases: an update of the graded prognostic assessment for Lung Cancer Using Molecular Markers (Lung-molGPA). *JAMA Oncol* 2017;3(06): 827–831
- Sperduto PW, Jiang W, Brown PD, et al. Estimating survival in melanoma patients with brain metastases: an update of the graded prognostic assessment for Melanoma Using Molecular Markers (Melanoma-molGPA). *Int J Radiat Oncol Biol Phys* 2017; 99(04):812–816
- Sperduto PW, Deegan BJ, Li J, et al. Estimating survival for renal cell carcinoma patients with brain metastases: an update of the Renal Graded Prognostic Assessment tool. *Neuro-oncol* 2018;20 (12):1652–1660
- Sperduto PW, Berkey B, Gaspar LE, Mehta M, Curran W. A new prognostic index and comparison to three other indices for patients with brain metastases: an analysis of 1,960 patients in the RTOG database. *Int J Radiat Oncol Biol Phys* 2008;70(02): 510–514
- Le Rhun E, Weller M, Brandsma D, et al; EANO Executive Board and ESMO Guidelines Committee. EANO–ESMO Clinical Practice Guidelines for diagnosis, treatment and follow-up of patients with leptomeningeal metastasis from solid tumours. *Ann Oncol* 2017;28(suppl 4):iv84–iv99
- Lote K, Stenwig AE, Skullerud K, Hirschberg H. Prevalence and prognostic significance of epilepsy in patients with gliomas. *Eur J Cancer* 1998;34(01):98–102
- van der Meer PB, Maschio M, Dirven L, Taphoorn MJB, Koekkoek JAF, Italian League Against Epilepsy Brain Tumor-Related Epilepsy Study Group. First-line levetiracetam versus enzyme-inducing antiepileptic medication in glioma patients with epilepsy. *Epilepsia* 2023;64(01):162–169
- Chang SM, Messersmith H, Ahluwalia M, et al. Anticonvulsant prophylaxis and steroid use in adults with metastatic brain tumors: ASCO and SNO endorsement of the Congress of Neurological Surgeons Guidelines. *J Clin Oncol* 2019;37(13): 1130–1135
- Patel TR, Knisely JP, Chiang VL. Management of brain metastases: surgery, radiation, or both? *Hematol Oncol Clin North Am* 2012; 26(04):933–947
- Prabhu RS, Kandula S, Liebman L, et al. Association of clinical response and long-term outcome among patients with biopsied orbital pseudotumor receiving modern radiation therapy. *Int J Radiat Oncol Biol Phys* 2013;85(03):643–649
- Vogelbaum MA, Brown PD, Messersmith H, et al. Treatment for brain metastases: ASCO–SNO–ASTRO Guideline. *J Clin Oncol* 2022;40(05):492–516
- Patchell RA, Tibbs PA, Walsh JW, et al. A randomized trial of surgery in the treatment of single metastases to the brain. *N Engl J Med* 1990;322(08):494–500

- 17 Patchell RA, Tibbs PA, Regine WF, et al. Postoperative radiotherapy in the treatment of single metastases to the brain: a randomized trial. *JAMA* 1998;280(17):1485–1489
- 18 Chin AL, Li G, Gephart MH, et al. Stereotactic radiosurgery after resection of brain metastases: changing patterns of care in the United States. *World Neurosurg* 2020;144:e797–e806
- 19 Mahajan A, Ahmed S, McAleer MF, et al. Post-operative stereotactic radiosurgery versus observation for completely resected brain metastases: a single-centre, randomised, controlled, phase 3 trial. *Lancet Oncol* 2017;18(08):1040–1048
- 20 Brown PD, Ballman KV, Cerhan JH, et al. Postoperative stereotactic radiosurgery compared with whole brain radiotherapy for resected metastatic brain disease (NCCTG N107C/CEC-3): a multicentre, randomised, controlled, phase 3 trial. *Lancet Oncol* 2017;18(08):1049–1060
- 21 Palmer JD, Klamer BG, Ballman KV, et al. Association of long-term outcomes with stereotactic radiosurgery vs whole-brain radiotherapy for resected brain metastasis: a secondary analysis of the N107C/CEC.3 (Alliance for Clinical Trials in Oncology/Canadian Cancer Trials Group) Randomized Clinical Trial. *JAMA Oncol* 2022;8(12):1809–1815
- 22 Fuentes R, Osorio D, Expósito Hernandez J, Simancas-Racines D, Martínez-Zapata MJ, Bonfill Cosp X. Surgery versus stereotactic radiotherapy for people with single or solitary brain metastasis. *Cochrane Database Syst Rev* 2018;8(08):CD012086
- 23 Andrews DW, Scott CB, Sperduto PW, et al. Whole brain radiation therapy with or without stereotactic radiosurgery boost for patients with one to three brain metastases: phase III results of the RTOG 9508 randomised trial. *Lancet* 2004;363(9422):1665–1672
- 24 Gondi V, Bauman G, Bradfield L, et al. Radiation therapy for brain metastases: an ASTRO Clinical Practice Guideline. *Pract Radiat Oncol* 2022;12(04):265–282
- 25 Yamamoto M, Serizawa T, Shuto T, et al. Stereotactic radiosurgery for patients with multiple brain metastases (JLKG0901): a multi-institutional prospective observational study. *Lancet Oncol* 2014;15(04):387–395
- 26 Yamamoto M, Serizawa T, Sato Y, Higuchi Y, Kasuya H. Stereotactic radiosurgery results for patients with 5–10 versus 11–20 brain metastases: a retrospective cohort study combining 2 databases totaling 2319 patients. *World Neurosurg* 2021;146:e479–e491
- 27 Balasubramanian SK, Sharma M, Venur VA, et al. Impact of EGFR mutation and ALK rearrangement on the outcomes of non-small cell lung cancer patients with brain metastasis. *Neuro-oncol* 2020;22(02):267–277
- 28 Li J, Ludmir EB, Wang Y, et al. Stereotactic radiosurgery versus whole-brain radiation therapy for patients with 4–15 brain metastases: a phase III randomized controlled trial. *Int J Radiat Oncol Biol Phys* 2020;108(03):S21–S22
- 29 Ammirati M, Nahed BV, Andrews D, Chen CC, Olson JJ. Congress of neurological surgeons systematic review and evidence-based guidelines on treatment options for adults with multiple metastatic brain tumors. *Neurosurgery* 2019;84(03):E180–E182
- 30 Borius PY, Régis J, Carpentier A, Kalamirides M, Valery CA, Latorzeff I. Safety of radiosurgery concurrent with systemic therapy (chemotherapy, targeted therapy, and/or immunotherapy) in brain metastases: a systematic review. *Cancer Metastasis Rev* 2021;40(01):341–354
- 31 Chen L, Douglass J, Kleinberg L, et al. Concurrent immune checkpoint inhibitors and stereotactic radiosurgery for brain metastases in non-small cell lung cancer, melanoma, and renal cell carcinoma. *Int J Radiat Oncol Biol Phys* 2018;100(04):916–925
- 32 Kim AH, Tatter S, Rao G, et al. Laser Ablation of Abnormal Neurological Tissue Using Robotic NeuroBlate System (LAAN-TERN): 12-month outcomes and quality of life after brain tumor ablation. *Neurosurgery* 2020;87(03):E338–E346
- 33 Ahluwalia M, Barnett GH, Deng D, et al. Laser ablation after stereotactic radiosurgery: a multicenter prospective study in patients with metastatic brain tumors and radiation necrosis. *J Neurosurg* 2018;130(03):804–811
- 34 Shah AH, Semonche A, Eichberg DG, et al. The role of laser interstitial thermal therapy in surgical neuro-oncology: series of 100 consecutive patients. *Neurosurgery* 2020;87(02):266–275
- 35 Bastos DCA, Rao G, Oliva ICG, et al. Predictors of local control of brain metastasis treated with laser interstitial thermal therapy. *Neurosurgery* 2020;87(01):112–122
- 36 Alattar AA, Bartek J Jr, Chiang VL, et al. Stereotactic laser ablation as treatment of brain metastases recurring after stereotactic radiosurgery: a systematic literature review. *World Neurosurg* 2019;128:134–142
- 37 Leuthardt EC, Duan C, Kim MJ, et al. Hyperthermic laser ablation of recurrent glioblastoma leads to temporary disruption of the peritumoral blood brain barrier. *PLoS One* 2016;11(02):e0148613
- 38 Meng Y, Pople CB, Budiansky D, et al. Current state of therapeutic focused ultrasound applications in neuro-oncology. *J Neuro-oncol* 2022;156(01):49–59
- 39 Meng Y, Suppiah S, Surendrakumar S, Bigioni L, Lipsman N. Low-intensity MR-guided focused ultrasound mediated disruption of the blood-brain barrier for intracranial metastatic diseases. *Front Oncol* 2018;8:338
- 40 Maier-Hauff K, Ulrich F, Nestler D, et al. Efficacy and safety of intratumoral thermotherapy using magnetic iron-oxide nanoparticles combined with external beam radiotherapy on patients with recurrent glioblastoma multiforme. *J Neurooncol* 2011;103(02):317–324
- 41 Chitgupi U, Qin Y, Lovell JF. Targeted nanomaterials for phototherapy. *Nanotheranostics* 2017;1(01):38–58
- 42 Cortes J, Rodriguez J, Aramendia JM, et al. Front-line paclitaxel/cisplatin-based chemotherapy in brain metastases from non-small-cell lung cancer. *Oncology* 2003;64(01):28–35
- 43 Dinglin XX, Huang Y, Liu H, Zeng YD, Hou X, Chen LK. Pemetrexed and cisplatin combination with concurrent whole brain radiotherapy in patients with brain metastases of lung adenocarcinoma: a single-arm phase II clinical trial. *J Neurooncol* 2013;112(03):461–466
- 44 Nayak L, DeAngelis LM, Robins HI, et al. Multicenter phase 2 study of patupilone for recurrent or progressive brain metastases from non-small cell lung cancer. *Cancer* 2015;121(23):4165–4172
- 45 Chevallier M, Borgeaud M, Addeo A, Friedlaender A. Oncogenic driver mutations in non-small cell lung cancer: past, present and future. *World J Clin Oncol* 2021;12(04):217–237
- 46 Raez LE, Cardona AF, Arrieta O, Lopes G. Lung cancer disparities in Hispanics: molecular diagnosis and use of immunotherapy. *JCO Glob Oncol* 2020;6(06):784–788
- 47 Deng Y, Feng W, Wu J, et al. The concentration of erlotinib in the cerebrospinal fluid of patients with brain metastasis from non-small-cell lung cancer. *Mol Clin Oncol* 2014;2(01):116–120
- 48 Welsh JW, Komaki R, Amini A, et al. Phase II trial of erlotinib plus concurrent whole-brain radiation therapy for patients with brain metastases from non-small-cell lung cancer. *J Clin Oncol* 2013;31(07):895–902
- 49 Ceresoli GL, Cappuzzo F, Gregorc V, Bartolini S, Crinò L, Villa E. Gefitinib in patients with brain metastases from non-small-cell lung cancer: a prospective trial. *Ann Oncol* 2004;15(07):1042–1047
- 50 Hou X, Li M, Wu G, et al. Gefitinib plus chemotherapy vs gefitinib alone in untreated EGFR-mutant non-small cell lung cancer in patients with brain metastases: the GAP BRAIN Open-Label, Randomized, Multicenter, Phase 3 Study. *JAMA Netw Open* 2023;6(02):e2255050
- 51 Kiura K, Yoh K, Katakami N, et al. Osimertinib in patients with epidermal growth factor receptor T790M advanced non-small

- cell lung cancer selected using cytology samples. *Cancer Sci* 2018;109(04):1177–1184
- 52 Reungwetwattana T, Nakagawa K, Cho BC, et al. CNS response to osimertinib versus standard epidermal growth factor receptor tyrosine kinase inhibitors in patients with untreated EGFR-mutated advanced non-small-cell lung cancer. *J Clin Oncol* 2018;36(33):jco2018783118
 - 53 Du X, Shao Y, Qin H-F, Tai Y-H, Gao H-J. ALK-rearrangement in non-small-cell lung cancer (NSCLC). *Thorac Cancer* 2018;9(04):423–430
 - 54 Solomon BJ, Cappuzzo F, Felip E, et al. Intracranial efficacy of crizotinib versus chemotherapy in patients with advanced ALK-positive non-small-cell lung cancer: results from PROFILE 1014. *J Clin Oncol* 2016;34(24):2858–2865
 - 55 Peters S, Camidge DR, Shaw AT, et al; ALEX Trial Investigators. Alectinib versus crizotinib in untreated ALK-positive non-small-cell lung cancer. *N Engl J Med* 2017;377(09):829–838
 - 56 Camidge DR, Kim HR, Ahn MJ, et al. Brigatinib versus crizotinib in advanced ALK inhibitor-naïve ALK-positive non-small cell lung cancer: second interim analysis of the phase III ALTA-1L trial. *J Clin Oncol* 2020;38(31):3592–3603
 - 57 Soria JC, Tan DSW, Chiari R, et al. First-line ceritinib versus platinum-based chemotherapy in advanced ALK-rearranged non-small-cell lung cancer (ASCEND-4): a randomised, open-label, phase 3 study. *Lancet* 2017;389(10072):917–929
 - 58 Shaw AT, Bauer TM, de Marinis F, et al; CROWN Trial Investigators. First-line lorlatinib or crizotinib in advanced ALK-positive lung cancer. *N Engl J Med* 2020;383(21):2018–2029
 - 59 Yang Y, Zhou J, Zhou J, et al. Efficacy, safety, and biomarker analysis of ensartinib in crizotinib-resistant, ALK-positive non-small-cell lung cancer: a multicentre, phase 2 trial. *Lancet Respir Med* 2020;8(01):45–53
 - 60 Ferrara R, Auger N, Auclin E, Besse B. Clinical and translational implications of RET rearrangements in non-small cell lung cancer. *J Thorac Oncol* 2018;13(01):27–45
 - 61 Subbiah V, Gainor JF, Oxnard GR, et al. Intracranial efficacy of selpercatinib in RET fusion-positive non-small cell lung cancers on the LIBRETTO-001 trial. *Clin Cancer Res* 2021;27(15):4160–4167
 - 62 Gainor JF, Curigliano G, Kim DW, et al. Pralsetinib for RET fusion-positive non-small-cell lung cancer (ARROW): a multicohort, open-label, phase 1/2 study. *Lancet Oncol* 2021;22(07):959–969
 - 63 Planchard D, Kim TM, Mazieres J, et al. Dabrafenib in patients with BRAF(V600E)-positive advanced non-small-cell lung cancer: a single-arm, multicentre, open-label, phase 2 trial. *Lancet Oncol* 2016;17(05):642–650
 - 64 Riely GJ, Ahn MJ, Felip E, et al. Encorafenib plus binimetinib in patients with BRAF^{V600}-mutant non-small cell lung cancer: phase II PHAROS study design. *Future Oncol* 2022;18(07):781–791
 - 65 Addeo A, Banna GL, Friedlaender A. KRAS G12C mutations in NSCLC: from target to resistance. *Cancers (Basel)* 2021;13(11):2541
 - 66 Nakajima EC, Drezner N, Li X, et al. FDA approval summary: sotorasib for KRAS G12C-mutated metastatic NSCLC. *Clin Cancer Res* 2022;28(08):1482–1486
 - 67 Ramalingam S, Skoulidis F, Govindan R, et al. P52.03 efficacy of sotorasib in KRAS p.G12C-mutated NSCLC with stable brain metastases: a post-hoc analysis of CodeBreaK 100. *J Thorac Oncol* 2021;16(10, suppl):S1123
 - 68 Sabari JK, Velcheti V, Shimizu K, et al. Activity of Adagrasib (MRTX849) in brain metastases: preclinical models and clinical data from patients with KRASG12C-mutant non-small cell lung cancer. *Clin Cancer Res* 2022;28(15):3318–3328
 - 69 Jänne PA, Riely GJ, Gadgeel SM, et al. Adagrasib in non-small-cell lung cancer harboring a KRAS^{G12C} mutation. *N Engl J Med* 2022;387(02):120–131
 - 70 Paik PK, Felip E, Veillon R, et al. Tepotinib in non-small-cell lung cancer with MET exon 14 skipping mutations. *N Engl J Med* 2020;383(10):931–943
 - 71 Patil T, Smith DE, Bunn PA, et al. The incidence of brain metastases in stage IV ROS1-rearranged non-small cell lung cancer and rate of central nervous system progression on crizotinib. *J Thorac Oncol* 2018;13(11):1717–1726
 - 72 Drilon A, Chiu CH, Fan Y, et al. Long-term efficacy and safety of entrectinib in ROS1 fusion-positive NSCLC. *JTO Clin Res Rep* 2022;3(06):100332
 - 73 Cho BC, Drilon AE, Doebele RC, et al. Safety and preliminary clinical activity of repotrectinib in patients with advanced ROS1 fusion-positive non-small cell lung cancer (TRIDENT-1 study). *J Clin Oncol* 2019;37(15, suppl):9011
 - 74 Drilon AE, Cho BC, Felip E, et al. Intracranial and systemic efficacy of repotrectinib in advanced ROS1 fusion-positive (ROS1+) non-small cell lung cancer (NSCLC) and central nervous system metastases (CNS mets) in the phase 1/2 TRIDENT-1. *J Clin Oncol* 2023;41(16, suppl):9017
 - 75 Baraibar I, Mezquita L, Gil-Bazo I, Planchard D. Novel drugs targeting EGFR and HER2 exon 20 mutations in metastatic NSCLC. *Crit Rev Oncol Hematol* 2020;148:102906
 - 76 Le X, Cornelissen R, Garassino M, et al. Poziotinib in non-small-cell lung cancer harboring HER2 exon 20 insertion mutations after prior therapies: ZENITH20-2 trial. *J Clin Oncol* 2022;40(07):710–718
 - 77 Le X, Garassino MC, Cornelissen R, et al. CNS activity of poziotinib in NSCLC with exon 20 insertion mutations. *J Clin Oncol* 2021;39(15, suppl):9093
 - 78 Drilon A, Tan DSW, Lassen UN, et al. Efficacy and safety of larotrectinib in patients with tropomyosin receptor kinase fusion-positive lung cancers. *JCO Precis Oncol* 2022;6(06):e2100418
 - 79 Hong DS, DuBois SG, Kummar S, et al. Larotrectinib in patients with TRK fusion-positive solid tumours: a pooled analysis of three phase 1/2 clinical trials. *Lancet Oncol* 2020;21(04):531–540
 - 80 Drilon A, Paz-Ares L, Doebele RC, et al. 543P entrectinib in NTRK fusion-positive NSCLC: updated integrated analysis of STARTRK-2, STARTRK-1 and ALKA-372-001. *Ann Oncol* 2020;31:S474–S47-5
 - 81 Goldberg SB, Schalper KA, Gettinger SN, et al. Pembrolizumab for management of patients with NSCLC and brain metastases: long-term results and biomarker analysis from a non-randomised, open-label, phase 2 trial. *Lancet Oncol* 2020;21(05):655–663
 - 82 Frost N, Kollmeier J, Misch D, et al. Pembrolizumab as first-line palliative therapy in PD-L1 overexpressing ($\geq 50\%$) NSCLC: real-world results with special focus on PS ≥ 2 , brain metastases, and steroids. *Clin Lung Cancer* 2021;22(05):411–422
 - 83 Gadgeel SM, Lukas RV, Goldschmidt J, et al. Atezolizumab in patients with advanced non-small cell lung cancer and history of asymptomatic, treated brain metastases: exploratory analyses of the phase III OAK study. *Lung Cancer* 2019;128:105–112
 - 84 Patel P, Alrfai D, McDonald F, Forster MAstraZeneca UK Limited. Beyond chemoradiotherapy: improving treatment outcomes for patients with stage III unresectable non-small-cell lung cancer through immuno-oncology and durvalumab (Imfinzi[®], AstraZeneca UK Limited). *Br J Cancer* 2020;123(suppl 1):18–27
 - 85 Giaquinto AN, Sung H, Miller KD, et al. Breast Cancer Statistics, 2022. *CA Cancer J Clin* 2022;72(06):524–541
 - 86 Osborne CK. Tamoxifen in the treatment of breast cancer. *N Engl J Med* 1998;339(22):1609–1618
 - 87 Graeber MB, Scheithauer BW, Kreutzberg GW. Microglia in brain tumors. *Glia* 2002;40(02):252–259

- 88 Watters JJ, Schartner JM, Badie B. Microglia function in brain tumors. *J Neurosci Res* 2005;81(03):447–455
- 89 Pukrop T, Dehghani F, Chuang H-N, et al. Microglia promote colonization of brain tissue by breast cancer cells in a Wnt-dependent way. *Glia* 2010;58(12):1477–1489
- 90 Ma G, He J, Yu Y, et al. Tamoxifen inhibits ER-negative breast cancer cell invasion and metastasis by accelerating Twist1 degradation. *Int J Biol Sci* 2015;11(05):618–628
- 91 Bergen ES, Berghoff AS, Medjedovic M, et al. Continued endocrine therapy is associated with improved survival in patients with breast cancer brain metastases. *Clin Cancer Res* 2019;25(09):2737–2744
- 92 Modi S, Jacot W, Yamashita T, et al; DESTINY-Breast04 Trial Investigators. Trastuzumab deruxtecan in previously treated HER2-low advanced breast cancer. *N Engl J Med* 2022;387(01):9–20
- 93 Vogel CL, Cobleigh MA, Tripathy D, et al. Efficacy and safety of trastuzumab as a single agent in first-line treatment of HER2-overexpressing metastatic breast cancer. *J Clin Oncol* 2002;20(03):719–726
- 94 Park YH, Park MJ, Ji SH, et al. Trastuzumab treatment improves brain metastasis outcomes through control and durable prolongation of systemic extracranial disease in HER2-overexpressing breast cancer patients. *Br J Cancer* 2009;100(06):894–900
- 95 Lin NU, Pegram M, Sahebjam S, et al. Pertuzumab plus high-dose trastuzumab in patients with progressive brain metastases and HER2-positive metastatic breast cancer: primary analysis of a phase II study. *J Clin Oncol* 2021;39(24):2667–2675
- 96 Jacot W, Pons E, Frenel JS, et al. Efficacy and safety of trastuzumab emtansine (T-DM1) in patients with HER2-positive breast cancer with brain metastases. *Breast Cancer Res Treat* 2016;157(02):307–318
- 97 Fabi A, Alesini D, Valle E, et al. T-DM1 and brain metastases: clinical outcome in HER2-positive metastatic breast cancer. *Breast* 2018;41:137–143
- 98 Montemurro F, Delalogue S, Barrios CH, et al. Trastuzumab emtansine (T-DM1) in patients with HER2-positive metastatic breast cancer and brain metastases: exploratory final analysis of cohort 1 from KAMILLA, a single-arm phase IIIb clinical trial^{*}. *Ann Oncol* 2020;31(10):1350–1358
- 99 Krop IE, Lin NU, Blackwell K, et al. Trastuzumab emtansine (T-DM1) versus lapatinib plus capecitabine in patients with HER2-positive metastatic breast cancer and central nervous system metastases: a retrospective, exploratory analysis in EMILIA. *Ann Oncol* 2015;26(01):113–119
- 100 Jerusalem G, Park YH, Yamashita T, Hurvitz SA, Modi S, Andre F, Krop IE, González Farré X, You B, Saura C, Kim SB, Osborne CR, Murthy RK, Gianni L, Takano T, Liu Y, Cathcart J, Lee C, Perrin C. Trastuzumab Deruxtecan in HER2-Positive Metastatic Breast Cancer Patients with Brain Metastases: A DESTINY-Breast01 Subgroup Analysis. *Cancer Discov* 2022 Dec 2;12(12):2754–2762
- 101 Cortés J, Kim SB, Chung WP, et al; DESTINY-Breast03 Trial Investigators. Trastuzumab deruxtecan versus trastuzumab emtansine for breast cancer. *N Engl J Med* 2022;386(12):1143–1154
- 102 Bartsch R, Berghoff AS, Furtner J, et al. Trastuzumab deruxtecan in HER2-positive breast cancer with brain metastases: a single-arm, phase 2 trial. *Nat Med* 2022;28(09):1840–1847
- 103 Pérez-García JM, Vaz Batista M, Cortez P, et al. Trastuzumab deruxtecan in patients with central nervous system involvement from HER2-positive breast cancer: The DEBBRAH trial. *Neurooncol* 2023;25(01):157–166
- 104 Lockman PR, Mittapalli RK, Taskar KS, et al. Heterogeneous blood-tumor barrier permeability determines drug efficacy in experimental brain metastases of breast cancer. *Clin Cancer Res* 2010;16(23):5664–5678
- 105 Lin NU, Murthy RK, Abramson V, et al. Tucatinib vs placebo, both in combination with trastuzumab and capecitabine, for previously treated ERBB2 (HER2)-positive metastatic breast cancer in patients with brain metastases: updated exploratory analysis of the HER2CLIMB randomized clinical trial. *JAMA Oncol* 2023;9(02):197–205
- 106 Bachelot T, Romieu G, Campone M, et al. Lapatinib plus capecitabine in patients with previously untreated brain metastases from HER2-positive metastatic breast cancer (LANDSCAPE): a single-group phase 2 study. *Lancet Oncol* 2013;14(01):64–71
- 107 Lin NU, Diéras V, Paul D, et al. Multicenter phase II study of lapatinib in patients with brain metastases from HER2-positive breast cancer. *Clin Cancer Res* 2009;15(04):1452–1459
- 108 Seligmann JF, Wright-Hughes A, Pottinger A, et al. Lapatinib plus capecitabine versus trastuzumab plus capecitabine in the treatment of human epidermal growth factor receptor 2-positive metastatic breast cancer with central nervous system metastases for patients currently or previously treated with trastuzumab (LANTERN): a phase II randomised trial. *Clin Oncol (R Coll Radiol)* 2020;32(10):656–664
- 109 Yan M, Ouyang Q, Sun T, et al. Pyrotinib plus capecitabine for patients with human epidermal growth factor receptor 2-positive breast cancer and brain metastases (PERMEATE): a multicentre, single-arm, two-cohort, phase 2 trial. *Lancet Oncol* 2022;23(03):353–361
- 110 Dirix LY, Takacs I, Jerusalem G, et al. Avelumab, an anti-PD-L1 antibody, in patients with locally advanced or metastatic breast cancer: a phase 1b JAVELIN Solid Tumor study. *Breast Cancer Res Treat* 2018;167(03):671–686
- 111 Cortes J, Cescon DW, Rugo HS, et al; KEYNOTE-355 Investigators. Pembrolizumab plus chemotherapy versus placebo plus chemotherapy for previously untreated locally recurrent inoperable or metastatic triple-negative breast cancer (KEYNOTE-355): a randomised, placebo-controlled, double-blind, phase 3 clinical trial. *Lancet* 2020;396(10265):1817–1828
- 112 Schmid P, Adams S, Rugo HS, et al; IMpassion130 Trial Investigators. Atezolizumab and Nab-paclitaxel in advanced triple-negative breast cancer. *N Engl J Med* 2018;379(22):2108–2121
- 113 Rishi A, Yu HM. Current treatment of melanoma brain metastasis. *Curr Treat Options Oncol* 2020;21(06):45
- 114 Margolin K, Atkins B, Thompson A, et al. Temozolomide and whole brain irradiation in melanoma metastatic to the brain: a phase II trial of the Cytokine Working Group. *J Cancer Res Clin Oncol* 2002;128(04):214–218
- 115 Jacquillat C, Khayat D, Banzet P, et al. Final report of the French multicenter phase II study of the nitrosourea fotemustine in 153 evaluable patients with disseminated malignant melanoma including patients with cerebral metastases. *Cancer* 1990;66(09):1873–1878
- 116 Sala E, Mogni L, Truffa S, Gaetano C, Bollag GE, Gambacorti-Passerini C. BRAF silencing by short hairpin RNA or chemical blockade by PLX4032 leads to different responses in melanoma and thyroid carcinoma cells. *Mol Cancer Res* 2008;6(05):751–759
- 117 Dummer R, Goldinger SM, Turtzsch CP, et al. Vemurafenib in patients with BRAF(V600) mutation-positive melanoma with symptomatic brain metastases: final results of an open-label pilot study. *Eur J Cancer* 2014;50(03):611–621
- 118 McArthur GA, Maio M, Arance A, et al. Vemurafenib in metastatic melanoma patients with brain metastases: an open-label, single-arm, phase 2, multicentre study. *Ann Oncol* 2017;28(03):634–641
- 119 Long GV, Trefzer U, Davies MA, et al. Dabrafenib in patients with Val600Glu or Val600Lys BRAF-mutant melanoma metastatic to the brain (BREAK-MB): a multicentre, open-label, phase 2 trial. *Lancet Oncol* 2012;13(11):1087–1095

- 120 Davies MA, Saiag P, Robert C, et al. Dabrafenib plus trametinib in patients with BRAF^{V600}-mutant melanoma brain metastases (COMBI-MB): a multicentre, multicohort, open-label, phase 2 trial. *Lancet Oncol* 2017;18(07):863–873
- 121 Syeda MM, Wiggins JM, Corless BC, et al. Circulating tumour DNA in patients with advanced melanoma treated with dabrafenib or dabrafenib plus trametinib: a clinical validation study. *Lancet Oncol* 2021;22(03):370–380
- 122 Dummer R, Ascierto PA, Gogas HJ, et al. Encorafenib plus binimetinib versus vemurafenib or encorafenib in patients with BRAF-mutant melanoma (COLUMBUS): a multicentre, open-label, randomised phase 3 trial. *Lancet Oncol* 2018;19(05):603–615
- 123 Holbrook K, Lutzky J, Davies MA, et al. Intracranial antitumor activity with encorafenib plus binimetinib in patients with melanoma brain metastases: a case series. *Cancer* 2020;126(03):523–530
- 124 Tarhini AA, Iqbal F. CTLA-4 blockade: therapeutic potential in cancer treatments. *OncoTargets Ther* 2010;3:15–25
- 125 Margolin K, Ernstoff MS, Hamid O, et al. Ipilimumab in patients with melanoma and brain metastases: an open-label, phase 2 trial. *Lancet Oncol* 2012;13(05):459–465
- 126 Tawbi HA, Forsyth PA, Algazi A, et al. Combined nivolumab and ipilimumab in melanoma metastatic to the brain. *N Engl J Med* 2018;379(08):722–730
- 127 Long GV, Atkinson V, Lo S, et al. Combination nivolumab and ipilimumab or nivolumab alone in melanoma brain metastases: a multicentre randomised phase 2 study. *Lancet Oncol* 2018;19(05):672–681
- 128 Kluger HM, Chiang V, Mahajan A, et al. Long-term survival of patients with melanoma with active brain metastases treated with pembrolizumab on a phase II trial. *J Clin Oncol* 2019;37(01):52–60