



Bulldog Scalp Syndrome

Mohd Altaf Mir¹ Jaya Jain¹ Prince Kumar¹ Rajesh Maurya¹ Manjit Kaur Rana²
Aakansha Giri Goswami¹

¹Department of Burns and Plastic Surgery, All India Institute of Medical Sciences, Bathinda, Punjab, India

²Department of Pathology, All India Institute of Medical Sciences, Bathinda, Punjab, India

Indian J Plast Surg 2023;56:544–547.

Address for correspondence Mohd Altaf Mir, MCh, Department of Burns and Plastic Surgery, All India Institute of Medical Sciences, Bathinda 151001, Punjab, India (e-mail: draltafmir@gmail.com).

Jaya Jain, Department of Burns and Plastic Surgery, All India Institute of Medical Sciences, Bathinda 151001, Punjab, India (e-mail: ijayajain@gmail.com).

Abstract

Bulldog scalp syndrome or cutis verticis gyrata (CVG) is a rare cutaneous disorder with an incidence of just 0.026 to 1 per 100,000 population and cosmetic problems should not be ignored as they can affect the quality of life of patients in social and psychological aspects. In CVG the scalp thickens to form folds resembling sulci and gyri just as the skin fold of bulldog. It is a clinical diagnosis with various etiologies. It is classified as primary essential or nonessential and secondary CVG. It can manifest with symptoms ranging from mild to severe intensity. Cosmetic problems are the major concern that can affect patients' social and psychological health. If the folds are heavy, they can cause mass symptoms. Thus, surgery remains the definitive treatment option for improving the cosmetic appearance. Both our cases have different etiologies, however, were managed surgically with removal of skin folds (gyrae) and scoring of aponeuroses of the scalp followed by stretching of the scalp and closure to improve appearance. The surgical team as well as patients were satisfied with the appearance of the scalp after healing. CVG though a rare disease with various etiologies is a benign condition with good prognosis with no reports of malignant transformation so far.

Keywords

- ▶ bulldog scalp
- ▶ cutis verticis gyrata
- ▶ scalp flap

Introduction

Cutis verticis gyrata (CVG) is a rare skin condition characterized by ridges and furrows resembling the brain CVG.^{1,2} These folds cannot be settled down by either traction or pressure. These are benign and usually organized in an anteroposterior direction. Albert reported the first case of CVG but Unna was the first one to coin the term CVG. It affects around 1 in 100,000 males and 0.026 in 100,000 females.¹ It is classified as primary essential or nonessential and secondary CVG. Cosmetic problems affecting social and psychological health of patient is the major presenting complaint. The histological appearance of primary CVG may range from normal skin architecture to thickened connective

tissue, while secondary CVG may show characteristic skin histology if present. Thus, it must be remembered that CVG is a clinical diagnosis. There are no medical management options available and surgery is the definitive treatment.³

Case I

A young Asian female in her twenties presented to the plastic surgery outpatient department with a cosmetic problem of heavy convoluted surface of the scalp hanging down on the neck. There was a history of brown, black plaque of lemon size since birth which progressed to occupy the occiput, left parietal and temporal scalp, hanging down on the neck. On examination convoluted folds and deep furrows of skin

article published online
November 24, 2023

DOI <https://doi.org/10.1055/s-0043-1776897>.
ISSN 0970-0358.

© 2023. Association of Plastic Surgeons of India. All rights reserved. This is an open access article published by Thieme under the terms of the Creative Commons Attribution-NonDerivative-NonCommercial-License, permitting copying and reproduction so long as the original work is given appropriate credit. Contents may not be used for commercial purposes, or adapted, remixed, transformed or built upon. (<https://creativecommons.org/licenses/by-nc-nd/4.0/>)
Thieme Medical and Scientific Publishers Pvt. Ltd., A-12, 2nd Floor, Sector 2, Noida-201301 UP, India

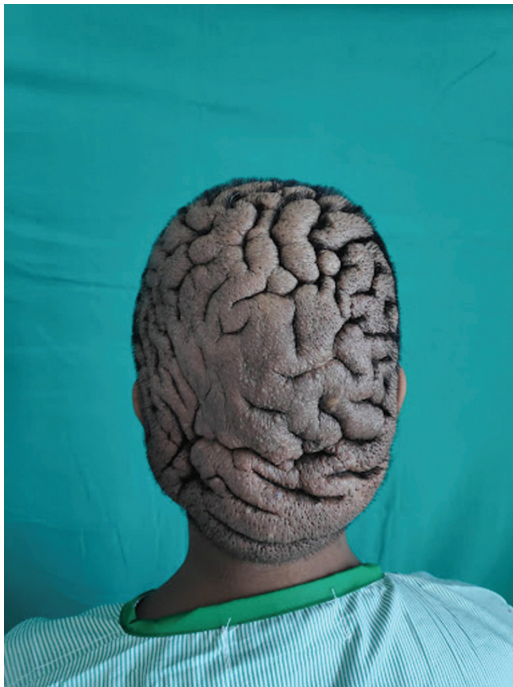

Fig. 1 Posterior view of the scalp showing convoluted skin fold occupying the whole occiput hanging down the neck.

covered with hair and acne were seen. Neurological examination was normal (► **Fig. 1**). But the history points toward CVG due to a secondary pathology of intradermal nevus.

Routine investigations like complete blood count, thyroid-stimulating hormone serum dosage, free T4, fasting blood glucose, total cholesterol and fractions, and venereal disease research laboratory test were all normal which helped exclude conditions associated with CVG like myxedema, leukemia, acanthosis nigricans, diabetes mellitus, and syphilis. Acromegaly and pachydermoperiostosis were ruled out on skull X-ray and magnetic resonance imaging (MRI). However, MRI showed irregular sheet-like scalp soft thickening showing ridges and grooves resembling gyriform appearance of the cerebral cortex with few prominent superficial scalp vessels—likely branches of superficial temporal and occipital arteries suggestive of CVG. Any malignancy and intracranial spread were ruled out. Postoperative biopsy findings showed nests of nevus cells in dermis and subcutis adding evidence to our provisional diagnosis upon history taking (► **Fig. 2**).

Debulking procedure with scalp and neck hairline reconstruction was performed. A curvilinear scalp skin incision was made extending from the left occipito-temporofrontal region and 50% of scalp skin was raised as flaps and relaxation incisions (scoring) was done in galea aponeurotica in transverse and vertical direction to release the gyri and sulci. The scalp skin was then retracted back and then the excess skin was removed from the margins of the flaps. Cosmetic correction of hanging tissue over the nape and temporal region was done with hairline correction. The wound was then closed.

The patient was followed up for 6 months. The sutures were removed on postoperative day 14. There were good cosmetic results with normal hair growth on third month of follow-up (► **Fig. 3**). The healing was satisfactory with con-

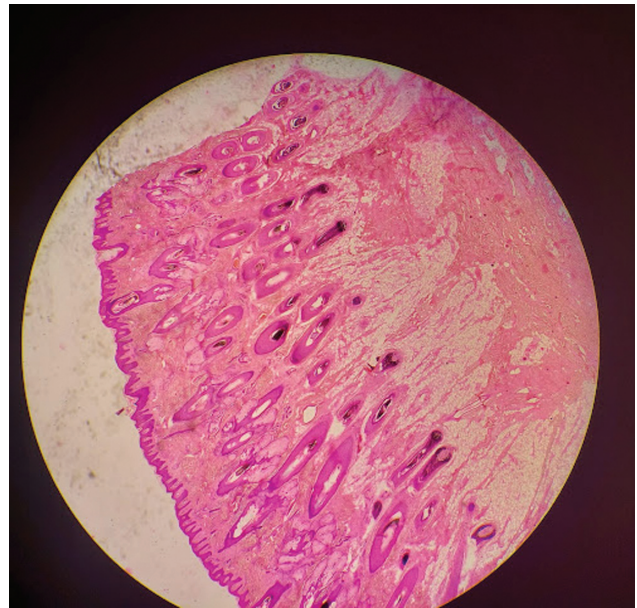

Fig. 2 Low power microscopic image of histopathology analysis of the lesion: Individual cells exhibit minimal atypia. Dermis shows sheets and nests of nevus cells reaching up to the subcutis, adding evidence to our intraoperative finding, suggestive of melanocytic nevi.

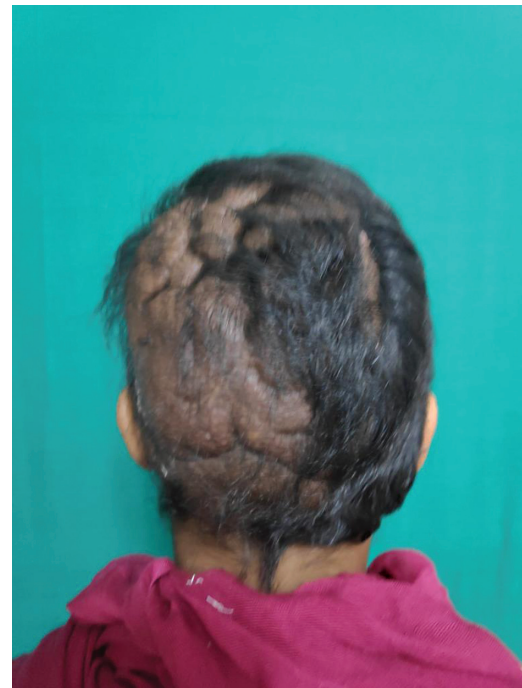

Fig. 3 Postoperative day 14 image showing good cosmetic results.

cealed scarring by hair growth. The patient was satisfied with the aesthetic outcome of surgery. Patient resumed social relations after successful surgery.

Case II

A Southeast Asian teenager presented to the outpatient department with complaints of convoluted folds and deep furrows on the scalp since birth (► **Fig. 4**).

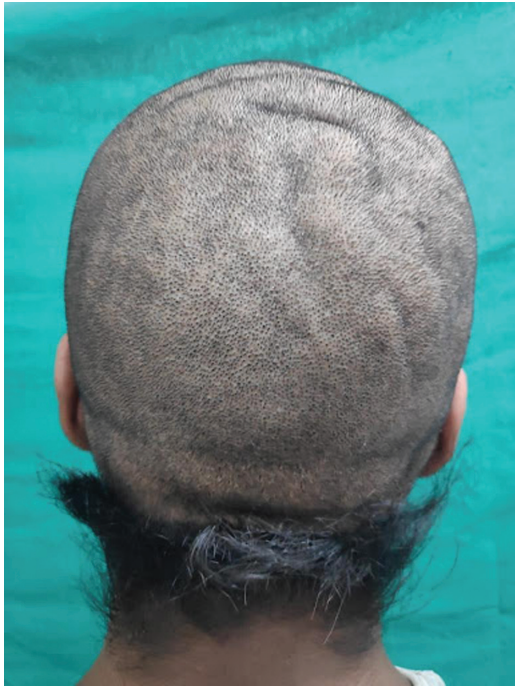

Fig. 4 Posterior view of the scalp showing 2 to 3 regular gyri and sulci.

The lesion was static and did not increase in size. There were no associated itching, pain, acne, or pressure symptoms. No neuropsychiatric or ophthalmic symptoms were seen. The past and family history were nonsignificant. The patient wanted only cosmetic results. On examination two folds resembling gyri could be seen on the occipital region arranged in the alphabetic T pattern. The neurological examination was normal.

On noncontrast computed tomography of head, diffuse thickening of the skin and subcutaneous tissue was seen in the scalp and there were no intracranial abnormalities, thus suggestive of CVG. All the serum chemistries and thyroid profile were done and came to be normal. Postoperative biopsy sample sent for histopathological study showed normal skin histology (→**Fig. 5**). Thus, secondary pathologies were ruled out.

Debulking and cosmetic correction was done under general anesthesia. Since the patient had regular gyri isolated resection of the largest gyri was done. Marking of two gyri was done, one transverse and the smaller one was vertical. Both were arranged in alphabet T.

First, the transverse gyri were resected. The flaps were then stretched and the vertical gyri disappeared and hence was not resected. The incision was then closed.

The patient was followed up for 6 months. On the 10th day after the operation, the stitches were taken out. The patient experienced positive cosmetic outcomes and observed normal hair regrowth, as shown in →**Fig. 6**. The healing process was pleasing, with concealed scars by hair growth on the third month. The patient expressed satisfaction with the surgery's aesthetic results and was able to resume social interactions following the successful procedure.

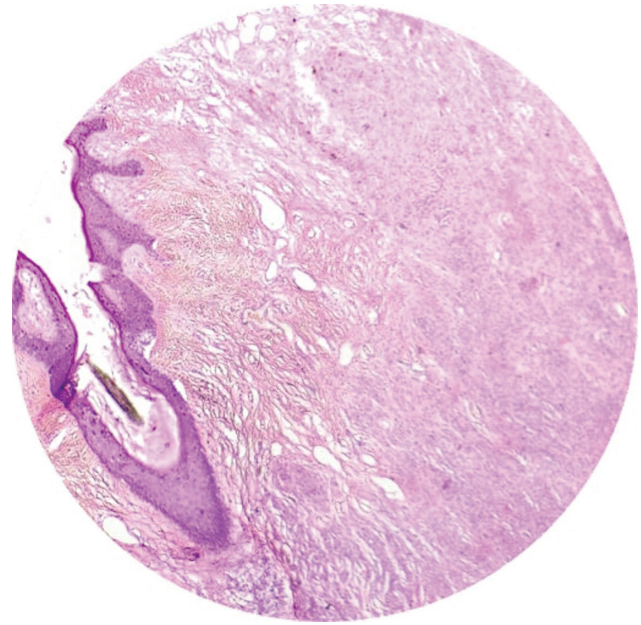


Fig. 5 Microscopic images of histopathological specimen showing convoluted epidermis and dermis suggestive of cutis verticis gyrata. However, other histological features are normal.

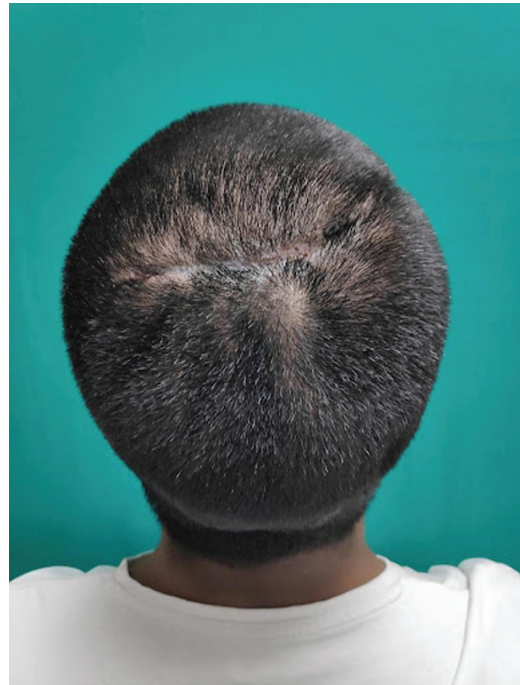


Fig. 6 Postoperative day 10 image of patient showing good cosmetic results with hair growth.

Discussion

Classification

CVG can be classified into primary and secondary. Primary can be essential and nonessential.

1. Primary essential CVG is a standalone entity where the cause of the condition is unknown. It has no other associated abnormalities.

2. Primary nonessential CVG can be associated with neuropsychiatric disorders including cerebral palsy, epilepsy, seizures, and ophthalmologic abnormalities, most commonly cataracts.
3. Secondary CVG occurs as a consequence of several diseases or drugs that produce changes in scalp structure. These include acromegaly, the use of growth hormone itself, or the use of drugs that mimic the effect of growth hormone (such as GHRP-6 and CJC-1295). It may also arise in association with melanocytic nevi (moles), birthmarks (including connective tissue nevi, fibromas, and nevus lipomatosus), and inflammatory processes (e.g., eczema, psoriasis, Darier disease, folliculitis, impetigo, atopic dermatitis, and acne).

Alibert in 1837 reported the first case of CVG but it was not until 1907 when Unna coined the term CVG. Robert described CVG in 1843. Polan in 1955 was the first to classify CVG as primary (idiopathic) or secondary.⁴ Primary CVG was further distinguished as essential or nonessential by Garden in 1984. Nonessential CVG are associated with either neuropsychiatric pathology such as seizures, mental retardation, epilepsy, cerebral palsy, or any ophthalmic abnormalities like cataract, blindness, strabismus, and retinitis pigmentosa. Secondary CVG etiology may consist of inflammatory pathologies like psoriasis, impetigo, eczema, erysipelas, folliculitis, pemphigus or nevi, neoplasms like pachydermoperiostosis that cause changes in the scalp structure acromegaly, hamartomas, and drugs like anabolic steroids. Some of the other causes are pituitary tumors, amyloidosis, intracerebral aneurysm, acanthosis nigricans, tuberous sclerosis, myxedema, cerebriform intradermal nevus, dermatofibroma, and syphilis. Various syndromes like Noonan syndrome, Ehlers–Danlos syndrome, and Turner syndrome may have CVG as one of its manifestations.^{4,5}

Primary CVG rarely occurs in young children, postpubertal being the most common age group with 90% cases seen before 30 years of age. The essential form is five times more prevalent in men than women. Primary CVG usually involves the vertex and occiput with symmetric folds running in anterior to posterior direction. There is no age and gender predilection in secondary CVG. And the folds seen are variable, with no longitudinal alignment.

The histological appearance of primary CVG may range from normal skin architecture to thickened connective tissue. The adnexa may be hypertrophied or have hyperplasia with or without an associated collagen fibers increase. These fibers might trap the apocrine and eccrine glands.

In secondary CVG the histology of skin folds resembles the underlying etiology.³

Scalp hygiene needs to be maintained to prevent secretion accumulation, unpleasant odor, secondary infections, and maceration.⁶

CVG is associated with high cosmetic and psychological concerns. Thus, surgery is the mainstay treatment option. The surgery type depends on the location and size of the folds. Options range from simple excisions of folds to tissue expansion and skin grafts. Smaller localized folds are usually excised and closed with care to avoid distortion of the nearby structures like brow, eyelid, and hairline. Larger folds are approached in a staged manner. First, tissue expansion technique is used followed by local flap reconstruction. Alternatively, partial resection of the most abundant segment of the lesion may be done. Free flaps like latissimus dorsi muscle or myocutaneous flaps are also suggested for complete resection of excess skin folds.^{1,7} Studies have highlighted that the safest and most effective procedure is partial resection with immediate closure. Further resection can be done after 1 year.⁸

Conflict of Interest

None declared.

References

- 1 Shareef S, Horowitz D, Kaliyadan F. Cutis Verticis Gyrata. 2023 Jul 10. In: StatPearls [Internet]. Treasure Island (FL): StatPearls Publishing; 2023 Jan
- 2 Yang JJ, Sano DT, Martins SR, Tebcherani AJ, Sanchez AP. Primary essential cutis verticis gyrata - case report. *An Bras Dermatol* 2014;89(02):326–328
- 3 Larsen F, Birchall N. Cutis verticis gyrata: three cases with different aetiologies that demonstrate the classification system. *Australas J Dermatol* 2007;48(02):91–94
- 4 Lamelas AM, Taub PJ, Silver L, Kressel A. Congenital primary essential cutis verticis gyrata. *Eplasty* 2016;16:ic13
- 5 Schöttler L, Denisjuk N, Körber A, Grabbe S, Dissemond J. Asymptomatic cerebriform folds of the scalp. Diagnosis: primary cutis verticis gyrata (CVG) [in German]. *Hautarzt* 2007;58(12):1058–1061
- 6 Ross JB, Tompkins MG. Cutis verticis gyrata as a marker of internal malignancy. *Arch Dermatol* 1989;125(03):434–435
- 7 Tani T, Miyamoto Y, Kurozumi N. Surgical treatment of cutis verticis gyrata: a report of 2 cases. *Br J Plast Surg* 1977;30(03):235–239
- 8 Koregol S, Yatagiri RV, Warad SR, Itagi NR. A rare association of scleromyxedema with cutis verticis gyrata. *Indian Dermatol Online J* 2016;7(03):186–189