Article published online: 2024-01-29

Aspergillus and the Lung

Iris Janssens, MD[1,2,3] Bart N. Lambrecht, MD, PhD[1,2,3,4] Eva Van Braeckel, MD, PhD[1,2]

[1] Department of Internal Medicine and Paediatrics, Faculty of Medicine and Health Sciences, Ghent University, Ghent, Belgium
[2] Department of Respiratory Medicine, Ghent University Hospital, Ghent, Belgium
[3] VIB Center for Inflammation Research, Ghent, Belgium
[4] Department of Pulmonary Medicine, ErasmusMC; Rotterdam, The Netherlands

Address for correspondence Eva Van Braeckel, MD, PhD, Department of Internal Medicine and Paediatrics, Ghent University Hospital 7K12E, Corneel Heymanslaan 10, BE-9000 Ghent, Belgium (e-mail: eva.vanbraeckel@ugent.be).

Semin Respir Crit Care Med 2024;45:3–20.

Abstract

The filamentous fungus *Aspergillus* causes a wide spectrum of diseases in the human lung, with *Aspergillus fumigatus* being the most pathogenic and allergenic subspecies. The broad range of clinical syndromes that can develop from the presence of *Aspergillus* in the respiratory tract is determined by the interaction between host and pathogen. In this review, an oversight of the different clinical entities of pulmonary aspergillosis is given, categorized by their main pathophysiological mechanisms. The underlying immune processes are discussed, and the main clinical, radiological, biochemical, microbiological, and histopathological findings are summarized.

Keywords
- *Aspergillus*
- *Aspergillus fumigatus*
- immunology
- pathophysiology

Aspergillus is a ubiquitous filamentous fungus, found worldwide in soil, water, food, and air. It is particularly present in decaying vegetation. While inhalation of its spores is common, this rarely causes disease in a host with normal immunological defense mechanisms.[1] Conversely, in a susceptible host, *Aspergillus* spp. can cause a wide variety of clinical syndromes, with the lung being the most frequent site of disease.[2] The development of a clinical syndrome, its invasiveness, and its prognosis all depend largely on the host's level of immune compromise or immune hyperresponsiveness.[3] There is no defined inoculum to determine the likelihood or severity of *Aspergillus* infection.[1] More than 200,000 life-threatening infections are documented annually, predominantly in immunocompromised hosts.[4] With the development of new therapies undermining the host immune system, the incidence of aspergillosis is on the rise.[1] *Aspergillus fumigatus*, the most pathogenic and allergenic *Aspergillus* species, is associated with an extremely high mortality rate (30–95%) in invasive infection.[4] Despite their high mortality rates, invasive mycoses remain understudied and underdiagnosed when compared to other infectious diseases.[4]

Aspergillus Mycology, Immunology, and Pathophysiology

The genus *Aspergillus* indicates an asexual ascomycete fungus that produces spore chains or columns radiating from central structures. It was first described in 1729 by Micheli and derives its name from the resemblance it bears to a holy water sprinkler named aspergillum.[5] At present and supported by molecular techniques, *Aspergillus* encompasses more than 250 species.[6,7] Only a number of these species are known to cause disease in humans, the most important being *A. fumigatus* (50–67% of isolates in invasive disease), *Aspergillus flavus* (8–14%), *Aspergillus terreus* (5–9%), and *Aspergillus niger* (3–5%).[1] These species are all found in a wide variety of substrata, including soil, compost piles, fruits, organic debris, animals, and, occasionally, humans.[8] *A. fumigatus* is known to cause disease in humans, but it does not typically colonize the healthy human respiratory tract. Genomic analyses of its encoded enzymes show that the enzymatic activity of the fungus is more related to the degradation of plant organic matter than to that of animal organic matter. This underpins the

Issue Theme Pulmonary Aspergillosis; Guest Editors: Eva Van Braeckel, MD, PhD, and Oliver A. Cornely, MD, FACP, FIDSA, FAAM, FECMM

DOI https://doi.org/10.1055/s-0043-1777259.
ISSN 1069-3424.

© 2024. The Author(s).
This is an open access article published by Thieme under the terms of the Creative Commons Attribution-NonDerivative-NonCommercial-License, permitting copying and reproduction so long as the original work is given appropriate credit. Contents may not be used for commercial purposes, or adapted, remixed, transformed or built upon. (https://creativecommons.org/licenses/by-nc-nd/4.0/)
Thieme Medical Publishers, Inc., 333 Seventh Avenue, 18th Floor, New York, NY 10001, USA

hypothesis that aspergillosis is more a result of human immune system failure than of *Aspergillus* virulence.[9]

A. fumigatus remains the major causative agent of pulmonary aspergillosis. A possible explanation is the abundant presence of its small reproductive spores, called conidia, in the environment. In air sampling during construction works, *A. fumigatus* is the dominant fungal species, even in hospital environments.[10,11] The fungal spores can stay airborne for hours after release and remain viable for months. The conidial hydrophobic outer layer plays a key role in the supreme survival of this species and provides protection against desiccation and freezing. Furthermore, *A. fumigatus* has a superior ability to grow in a wide range of environmental conditions. This includes challenging thermal (12–65°C), acidic (pH 2.2–8.8), and nutritional (wide variety of substrates degraded by a wide range of glycosylhydrolases and proteinases) conditions.[8,12]

A careful balance between antifungal protective responses and airway homeostasis needs to be maintained in order to (1) clear regularly encountered fungal pathogens with minimal effect on the host and (2) contain commensal fungi without reducing barrier integrity.[2] Clearing the encountered pathogen is complicated by the small size of the conidia, which have a diameter of 2 to 3.5 µm in *A. fumigatus*. Once inhaled, the spores travel through the tree-like structure of the bronchi. The branching of the airways causes a turbulent flow which deposits most of the foreign substances (e.g., pathogens, antigens, and pollutants) in the lining airway mucus. This mucus contains microbicidal peptides, which cause immediate inactivation of the pathogen, and soluble pathogen recognition receptors (PRRs) that opsonize the fungus, which leads to more downstream inactivation.[13] The ciliary beat of the epithelium constantly clears the mucus and propels it upward to be coughed up and expelled or swallowed into the gastrointestinal tract. This process is called mucociliary clearance. Due to their small size, the conidia are able to penetrate deep into the peripheral airways, largely bypassing the mucociliary clearance mechanisms of the bronchial epithelium, and thus escaping the first barrier of defense of the respiratory tract.[1,13–15]

In the event that the conidia do become trapped in mucus, they retain low immunogenicity due to their hydrophobic rodlet layer exterior composed of regularly arranged hydrophobin RodA.[13,16,17] However, within 4 to 6 hours after inhalation, uncleared conidia shed their rodlet layer, swell, and germinate into germ tubes and hyphae to form a colony.[18] In an *A. fumigatus* colony, an extracellular matrix (ECM) enrobes the hyphae to form a biofilm.[19] To be able to proliferate, the fungus must withstand microbial antagonism and earn its place among other microorganisms in the mucus. The liberation of nutrients, such as iron and zinc, is indispensable for this process.[20–22] Therefore, the fungus releases proteases that challenge the airway barrier integrity by damaging the epithelial cells. The majority of fungal diseases arise from poorly cleared infection or disrupted barrier integrity,[23] and clinical syndromes only develop in hosts with dysfunctional immune responses.[1] In addition, the pathogen is extremely versatile and able to survive in multiple microenvironments, ranging from the respiratory tract microbiome in the mucus during colonization, the biofilm environment of an aspergilloma, to the hypoxic environment of necrotic tissue.[18] As a result of this interaction with changing environments, fungi interact with humans through the establishment of symbiotic, commensal, latent, or pathogenic relationships.[24]

After shedding the conidial rodlet layer, fungal antigens are revealed and trigger the local innate immune system, which is the highly conserved but rapid branch of our human defense mechanism. The antigens are pathogen-associated molecular patterns (PAMPs) present on the fungal cell wall, categorized as β-glucans (polymers of glucose), chitin (polymer of N-acetylglucosamine), and mannans (chains of several hundred mannose molecules).[18] These PAMPs are bound by actors of the complement system or by a range of PRRs, such as toll-like receptors, C-type lectin receptors (CLRs), and NOD-like receptors. An example of a PAMP is 1,3-β-D-glucan, a universal fungal cell wall component that is recognized by dectin-1, a CLR. As a response to dectin-1 binding by 1,3-β-D-glucan, pentraxin-3 (PTX3), a soluble PRR, is released by neutrophils, mononuclear phagocytes, dendritic cells (DCs), and endothelial cells. PTX3 opsonizes fungal conidia, which makes it indispensable in the host defense against *A. fumigatus*. This is illustrated in hematologic stem cell recipients with polymorphisms in the *PTX3* gene, who are more susceptible to invasive aspergillosis independent of neutropenia[25,26].

PRR binding leads to immune cell activation, and in the early phase of infection, alveolar macrophages clear fungal conidia, whereas neutrophils impede hyphal tissue invasion.[27] The action of these phagocytes largely depends on the nicotinamide adenine dinucleotide phosphate (NADPH) oxidation complex to form reactive oxygen species (ROS). The vital role of this complex in clearing the pathogen is supported by the notable susceptibility of patients with chronic granulomatous disease (CGD) to invasive aspergillosis. These patients lack the normal function of the NADPH complex due to genetic mutations in components of the complex. They are extensively studied to unravel the role of the NADPH complex in immune defense against *Aspergillus* spp. In alveolar macrophages, NADPH-induced LC3-associated phagocytosis plays a nonredundant role in fungal conidial engulfment and digestion of the fungal conidia. Furthermore, the NADPH complex in neutrophils mediates ROS-induced hyphal damage and the release of neutrophil extracellular traps (NETs).[27,28] NETs are released in a certain form of cell death, called NETosis, in which neutrophils expel threads of condensed deoxyribonucleic acid (DNA) decorated with cationic histones to immobilize fungal hyphae. Furthermore, NETosis causes the release of chelators of essential ions (e.g., calprotectin which traps Fe^{2+} and Zn^{2+}) to deplete essential nutrients in their immediate environment.[29] Neutrophils are able to sense the microbial size and selectively release NETs in response to the presence of the large pathogen and capture hyphae and large aggregated conidia.[29] The role of NETosis in killing *A. fumigatus* remains unclear[30,31]; presumably, they confine infection rather than eliminate it. On the contrary, NETosis might also be harmful and cause lung tissue damage,[32] making the NET-mediated control of fungal outgrowth a subject of debate. The pathogen eludes innate

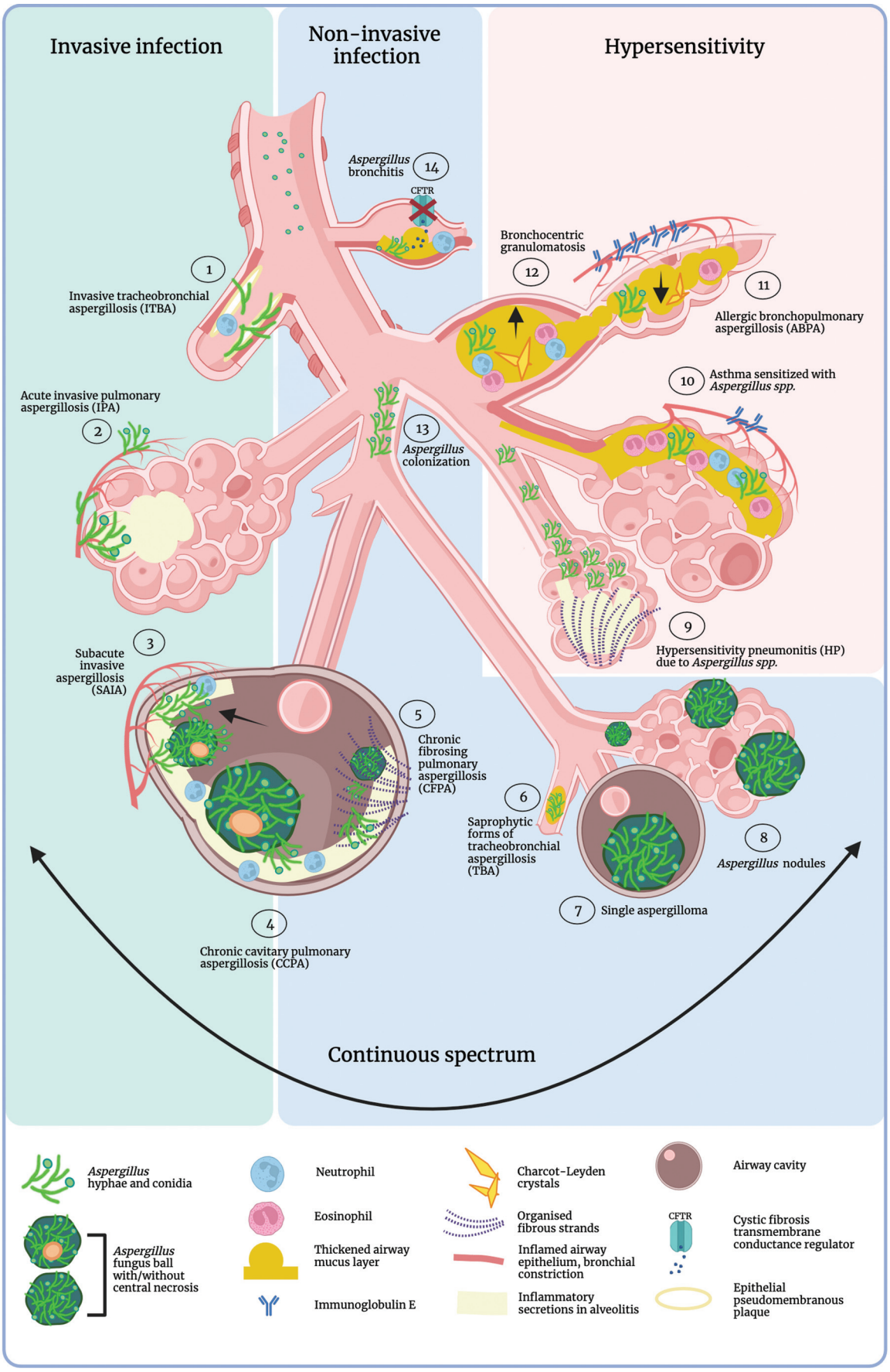

Fig. 1 *Clinical spectrum of pulmonary aspergillosis.* The clinical spectrum of pulmonary aspergillosis is divided into three categories: invasive infection (*left panel*), noninvasive infection (*middle panel*), and manifestations of hypersensitivity (*right panel*). The different clinical entities that

immune responses through species-specific evasion mechanisms such as complement inhibition and the release of toxins, proteases, and phospholipases.[1,18]

Antigen-presenting cells (APCs) such as DCs activate the adaptive immune system by trafficking antigen to lymph nodes in order to induce the differentiation of naive CD4 and CD8 T cells. CD4 T cells differentiate into T helper (Th) 1, Th2, Th17, or Th9 cell subsets.[24] These T helper subset cells produce cytokines related to the four following specific antifungal responses. A Th1 response is characterized by the release of interferon gamma (IFNγ) and is associated with a favorable outcome in experimental aspergillosis.[2,33] Release of the main cytokines involved in Th2 responses, interleukin (IL)-4, IL-5, and IL-13 results in eosinophil recruitment and a polyclonal immunoglobulin (Ig)E response. The Th2 response does not eradicate the fungi but generates an intense inflammatory reaction characterized by mast cell degranulation and the influx of large numbers of eosinophils and neutrophils.[24] These patients may develop a hypersensitivity syndrome.[34] A Th9 response is characterized by a type 2 innate lymphoid cell (ILC2)-driven allergic inflammation and fibrosis, through IL-9 and transforming growth factor-β release.[35] A Th17 response involves IL-17 and IL-22 and results in neutrophil recruitment with NETosis and the production of antimicrobial peptides by the airway epithelium.[36] Antigen-loaded APCs also activate CD8 T cells to differentiate into effector cytotoxic lymphocytes that can induce immediate cytotoxicity. Conversely, tolerogenic DCs induce immune tolerance through CD4 regulatory T cells (Tregs) and type 1 regulatory T cells (Tr1 cells).[24] Treg cells induce tolerance against fungal components in human allergy, whereas Tr1 cells regulate the expansion of antigen-specific T cells, thus limiting immunopathology.[18] In conclusion, the host immune response to fungi is evolutionary conserved and balances between resistance and tolerance, where the former corresponds to the limitation of fungal burden, whereas the latter corresponds to the limitation of pathogen- or immune-mediated host damage.[24,37]

Clinical Spectrum of Pulmonary Aspergillosis

The respiratory clinical syndromes caused by *Aspergillus* in humans can be divided into three main categories: (1) invasive infections, (2) noninvasive infections, and (3) manifestations of hypersensitivity. The allocation of a clinical entity to a category is based on the underlying immune defect[3] (►**Fig. 1**). Although this categorization facilitates diagnosis and treatment, the different disease entities are not strictly delineable and make part of a continuous clinical spectrum. One form of clinical disease may evolve into another over time, irrespective of the initial immunopathogenesis. Moreover, different disease entities may exist at the same time. The resulting clinical syndrome depends on the underlying host risk factors (►**Table 1**) and is determined by clinical, radiological, biochemical, microbiological and histopathological characteristics (►**Table 2**).

Invasive Manifestations of Aspergillosis: Impaired Cell-Mediated Immunity

Acute Invasive Pulmonary Aspergillosis

Although there has been a remarkable improvement in the early diagnosis and treatment of acute invasive pulmonary aspergillosis (IPA) over the past decade,[38] the disease is still a major cause of morbidity and mortality in severely immunocompromised patients. The main risk factors include prolonged neutropenia or impaired neutrophil function, immunosuppressive medication, and CD4 T-cell counts below 100/μL.[39] Almost half of this population does not respond to treatment resulting in a mortality of 20 to 30% within 6 weeks after treatment initiation.[40,41] The diagnosis is established based on the combination of a typical host factor, suggestive radiological findings, and a microbiological or histopathological proof of fungal presence[42] (►**Table 2**).

can develop from the presence of *Aspergillus* are numbered 1 to 14, accompanied by an illustration of their main pathophysiological characteristics. (1) Invasive tracheobronchial aspergillosis (ITBA) is described in an ulcerative form and a pseudomembranous form; here, the pseudomembranous form is depicted with pseudomembranous inflammatory ulcerative plaques in a proximal airway with invasiveness in the enrobing tissue. (2) Acute invasive pulmonary aspergillosis (IPA), depicted here in a neutropenic environment with fungal hyphae invading the alveolar capillary, pointing out the tissue- and possible angio-invasiveness of the disease. (3) Subacute invasive aspergillosis (SAIA), a disease entity with characteristics of both IPA and chronic cavitary pulmonary aspergillosis. The rapid progression of cavitation in this disease is indicated with the arrow. Tissue invasiveness is often described. (4) Chronic cavitary pulmonary aspergillosis (CCPA) is characterized by one or more cavities with or without a thickened wall. The cavities can be filled with solid or fluid material and a fungal ball can be present. Local tissue invasion may occur depending on the host immune status. (5) Chronic fibrosing pulmonary aspergillosis (CFPA) is considered a fibrotic end-stage of CCPA. (6) Saprophytic forms of tracheobronchial aspergillosis (TBA) are bronchial aspergillosis, endobronchial aspergillosis, and mucoid impaction. The fungal hyphae are restricted to the airway lumen. (7) A single aspergilloma does not induce a clinical inflammatory response, neither does an *Aspergillus* nodule (8). (9) Hypersensitivity pneumonitis (HP) due to *Aspergillus* spp. can present with or without fibrosis. (10) Asthma sensitized by *Aspergillus* spp. involves airway constriction, mucus production and a T helper 2 (Th2) immune response with eosinophilia and immunoglobulin E (IgE) production. (11) Allergic bronchopulmonary aspergillosis (ABPA) involves Th2 inflammation with eosinophilia, Charcot–Leyden crystals, and overzealous IgE production which results in mucus plugging, airway constriction and congestion, central bronchiectasis (indicated by the black arrow pointing upward), and atelectasis (indicated by the black arrow pointing downwards). (12) Bronchocentric granulomatosis can present as ABPA that is confined to the bronchi. (13) Uncomplicated airway colonization with *Aspergillus* spp. (14) *Aspergillus* bronchitis is described in cystic fibrosis (CF) and non-CF bronchiectasis. Bronchiectasis and sticky airway mucus in CF is a result from the absence or malfunctioning of the ion transporter cystic fibrosis transmembrane conductance regulator (CFTR). These 14 different disease entities are not strictly delineable and make part of a continuous clinical spectrum. One form of clinical disease may evolve into another over time, depending on the degree of immune compromise or hyperresponsiveness of the host. Each of these different disease presentations can evolve into one another irrespective of the initial immunopathogenesis. Moreover, different disease entities may exist at the same time. *This figure was created with BioRender.*

Table 1 Immune defects and risk factors of the clinical entities of pulmonary aspergillosis

Clinical entity	Main pathophysiological mechanism	Risk population	Risk factors
Acute invasive pulmonary aspergillosis	Impaired cell-mediated immune response	Acute leukemia, myelodysplastic syndrome, aplastic anemia, and other causes of marrow failure; GvHD after hematopoietic stem cell transplantation; solid organ transplantation (lung), AIDS, CGD[39]	Prolonged neutropenia, immunosuppressive medication, CD4 T cell count <100 /μL, defective NADPH oxidase (in CGD)
Invasive tracheobronchial aspergillosis			
Subacute invasive aspergillosis		Preexisting structural lung disease (e.g., emphysema, previous cavitary tuberculosis, sarcoidosis)	Coexisting conditions ,e.g., diabetes mellitus, malnutrition, alcoholism, advanced age, rheumatoid arthritis, COPD, connective tissue disorders, radiation therapy, nontuberculous mycobacterial infection[112] or AIDS[112]
Chronic cavitating pulmonary aspergillosis	Impaired mucosal barrier integrity		
Chronic fibrosing pulmonary aspergillosis			
Single aspergilloma		Pre-existing cavity in an otherwise immunocompetent host	Unknown
Aspergillus nodule		Unknown	Unknown
Saprophytic tracheobronchial aspergillosis		ABPA, asthma with fungal sensitization, AIDS	Unknown
Aspergillus bronchitis		Cystic fibrosis	Respiratory tract colonization with *Aspergillus*, continuous antibiotic therapy, bronchiectasis
Asthma with fungal sensitization	Hypersensitivity type 1, type 2 inflammation	Male sex	Respiratory tract colonization with *Aspergillus,* advanced age, longer asthma duration, higher maintenance oral corticosteroid and asthma biologic use, worse prebronchodilator airflow obstruction, radiological bronchiectasis[113]
Allergic bronchopulmonary aspergillosis		Cystic fibrosis, asthma	Pet ownership, renovation works, gardening
Hypersensitivity pneumonitis	Two-hit hypothesis: preexisting genetic susceptibility or environmental factors (i.e., the first hit) increases the risk for the development of HP after antigen exposure (the second hit). Th1-mediated granulomatous inflammation.[114]	Age > 65 years[108]	Exposure to high inoculum of *Aspergillus* (renovation works, horticulture)

Abbreviations: AIDS, acquired immunodeficiency syndrome; CGD, chronic granulomatous disease; COPD, chronic obstructive pulmonary disease; GvHD, graft versus host disease; HP, hypersensitivity pneumonitis; NADPH, nicotinamide adenine dinucleotide phosphate; Th, T helper.

In acute IPA, the fungal hyphae penetrate the tissue, which results in tissue infection and inflammation. In neutropenic patients, the hyphae may even penetrate the blood vessels (angio-invasion) and cause disseminated infection with secondary hemorrhagic infarction and necrosis, which is associated with poor outcome.[43] The population mainly affected by this aggressive infection are patients that suffer from a hematologic malignancy, as a consequence of the disease (e.g., in myelodysplastic syndrome) or the treatment (e.g., after induction chemotherapy in acute myeloid leukemia or myeloablative pretreatment for hematopoietic stem cell transplantation [HSCT]).[1,3] More specifically, a peak in acute

Table 2 Clinical signs, and radiological, biochemical, and microbiological findings for the different disease entities of pulmonary aspergillosis

Clinical entity	Clinical signs	Radiological findings	Relevant serological and biochemical findings	*Aspergillus* microbiology in respiratory samples	Histopathology
Acute invasive pulmonary aspergillosis	Acute cough, high fever, pleuritic chest pain	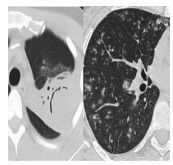 Typical findings (neutropenic patients)[a]: Scattered nodules, peripheral ground glass opacity (GGO) halo, air crescent/cavitation, hypodense sign/inverse halo sign, peripheral wedge-shaped infarcts, and consolidations[115] 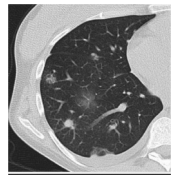 Atypical findings (nonneutropenic patients)[a]: Tracheal/bronchial wall thickening (large airways), tree-in-bud opacities (small airways), consolidations and nodules with or without cavitation and GGO with predominant peribronchial distribution (most common), nonspecific infiltrates (most common)[115]	Angio-invasive variant: positive serum galactomannan. Airway-invasive variant: serum galactomannan negative. In both cases BALF galactomannan positive.	Positive culture for *Aspergillus* spp. may be present	Angio-invasive variant: histologically proven hyphal invasion of blood vessels with resulting thrombosis, ischemic necrosis, or hemorrhagic infarction Airway-invasive variant: Aspergillus hyphae in tissue, pyogranulomatous inflammation with inflammatory necrosis.
Invasive tracheobronchial pulmonary aspergillosis	Chronic dry cough and decreased appetite to high fever, severe respiratory distress, and rapid development of respiratory and multiorgan failure.[52]	Mostly absent; but subtle tracheal thickening (arrow) associated with slight densification of the adjacent mediastinal fat can occur[53]	Positive *Aspergillus* specific IgG	Positive culture for *Aspergillus* spp. in combination with typical bronchoscopy findings are indicative for ITBA[38]	
Subacute invasive aspergillosis	Chronic symptoms of productive cough, dyspnea, hemoptysis, fatigue, weight loss	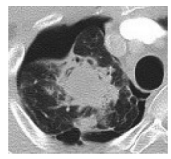 Fungal ball in quickly expanding cavity. A progressive consolidative lung opacity may undergo cavitation, and become the host site for an aspergilloma, or have thin walls and rapidly expand. Mycelia may invade the pleural space. The development of pleural thickening adjacent to lung cavities and/or para-cavitary lung opacities are signals of active disease.[116]		Positive culture for *Aspergillus* spp. may be present	
Chronic cavitating pulmonary aspergillosis		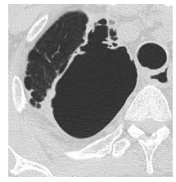 Lung cavities, thick or thin walled, with or without fungal ball.			No *Aspergillus* hyphae in tissue; fungal ball with mycelia and occasionally central necrosis

Table 2 (*Continued*)

Clinical entity	Clinical signs	Radiological findings	Relevant serological and biochemical findings	*Aspergillus* microbiology in respiratory samples	Histopathology
Chronic fibrosing pulmonary aspergillosis		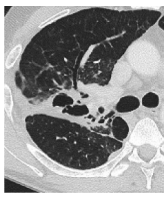 Lung cavities with encircling sign of fibrosis of at least two lung lobes, sometimes filled with aspergillomas.			
Single aspergilloma	Minor or no symptoms, very rarely hemoptysis, shortness of breath, or cough.[62]	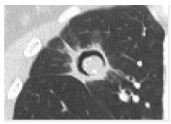 Monod sign: crescent of air around fungal ball. With effort (supine/prone position), the fungus ball can often be shown to be mobile within the cavity when the ball does not fill the entire cavity.[116]	Positive *Aspergillus* specific IgG may be present. Positive culture for *Aspergillus* spp. may be present.		
Aspergillus nodule	Absent	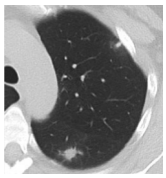 One or more dense nodules (<3 cm), which do not usually cavitate			Small fungal ball with mycelia and occasionally central necrosis
Saprophytic tracheobronchial aspergillosis	Productive cough or absent	Normal			Normal respiratory epithelium
Chronic *Aspergillus* bronchitis in cystic fibrosis	Chronic (>4 weeks) pulmonary symptoms (chronic productive cough, tenacious mucus production, dyspnea, and difficult airway clearance)[117]	Bronchial wall thickening (tram track sign, signet-ring sign). Very difficult to make a distinction from radiological findings frequently found in uncomplicated CF. No pulmonary infiltrates.	Total serum IgE levels <200 kU/l, *Aspergillus* IgG antibody detectable in serum. Negative *Aspergillus* IgE (lack of allergic response).[117] Positive sputum galactomannan.	Repeated positive sputum culture for *Aspergillus* spp.	Superficial invasion of mucosa by *Aspergillus* hyphae.[117]
Asthma with fungal sensitization	Cough, chest tightness, wheezing	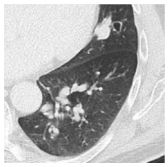 Normal or bronchiectasis, mucus plugging, bronchial wall thickening (tram track sign, signet-ring sign), air trapping.	Elevated *Aspergillus* specific IgE	Positive sputum culture for *A. fumigatus* is supportive but not diagnostic	Characteristic airway architecture for asthma: goblet cell metaplasia, excessive subepithelial collagen deposition, airway smooth muscle hyperplasia, and increased vascularity[86]
Allergic bronchopulmonary aspergillosis (ABPA) and bronchocentric granulomatosis (tracheobronchial presentation of ABPA)	Cough, chest tightness, wheezing, expectoration of brownish mucus plugs, pleuritic chest pain	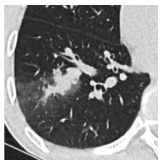 Central bronchiectasis, mucus plugging, finger-in-glove sign, high	Elevated *Aspergillus* specific IgE and IgG, elevated total IgE		Bronchocentric granulomatosis and extensive mucoid impaction with allergic mucin consisting of mucus, eosinophils, Charcot-Leyden crystals, fibrin, Curschmann spirals and fungal hyphae

(*Continued*)

Table 2 (*Continued*)

Clinical entity	Clinical signs	Radiological findings	Relevant serological and biochemical findings	*Aspergillus* microbiology in respiratory samples	Histopathology
		attenuation mucoid impaction,[118] bronchial wall thickening (tram track sign, signet-ring sign), air trapping.			
Extrinsic allergic alveolitis / hypersensitivity pneumonitis to *Aspergillus spp.*	Cough, fever, shortness of breath. Recurrent atypical pneumonia with a certain regularity (e.g., only at the workplace, after moving houses, only certain days of the week). Intense exposure to decaying plant material (e.g., farming).[108]	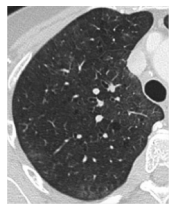 Nonfibrotic: lung infiltration (i.e., GGO mosaic attenuation) plus at least one HRCT abnormality suggestive of small airway disease (e.g., air trapping). Fibrotic: small airway disease and irregular fine or coarse reticulation with architectural lung distortion, sometimes with septal thickening, traction bronchiectasis in areas of GGO, honeycombing.[108]	BALF lymphocytosis,[108] *Aspergillus* spp. specific precipitins or IgG[119]	Not relevant[108]	Cellular interstitial pneumonia, chronic fibrotic interstitial pneumonia, cellular bronchiolitis, nonnecrotizing granulomas[108]

Abbreviations: ABPA, allergic bronchopulmonary aspergillosis; BALF, broncho-alveolar lavage fluid; CF, cystic fibrosis; GGO, ground glass opacities; Ig, immunoglobulin; ITBA, invasive tracheobronchial aspergillosis.
[a]Image courtesy of Ine Moors, MD

IPA incidence in these patients is observed after prolonged neutropenia corresponding with less than 500 neutrophils/µL for more than 10 consecutive days[44] (►**Table 1**). In non-neutropenic immunocompromised patients, the hyphae penetrate the tissue but usually do not become angio-invasive.[45] On a tissue level, they develop pyogranulomatous inflammation with inflammatory necrosis. Examples of patient groups susceptible to this disease are people with acquired immunodeficiency syndrome (AIDS) or CGD, as well as solid organ transplant (SOT) recipients (particularly lung transplant recipients),[46] people suffering from graft-versus-host disease (GvHD) or people who underwent an HSCT without myeloablative pretreatment.[3,38] Furthermore, IPA is increasingly reported in patients beyond the traditional risk groups such as chronic obstructive pulmonary disease (COPD) patients and critically ill patients (►**Table 1**, ►**Fig. 2**). Critically ill patients with viral pneumonia are particularly at risk of *Aspergillus* coinfection, which leads to worse outcomes,[23] even in previously immunocompetent patients. Influenza-associated pulmonary aspergillosis (IAPA) and coronavirus disease 2019 (COVID-19)-associated pulmonary aspergillosis (CAPA) are the two most common examples. In patients with severe influenza (predominantly influenza A) who develop IAPA, intensive care unit (ICU) mortality is as high as 45 to 61%, whereas mortality in ICU patients with influenza without IAPA is 20%.[47] The mortality in CAPA is comparable to IAPA (44–71%) and remarkably higher compared to patients with COVID-19 without CAPA (19–37%).[48,49] Moreover, most of the affected IAPA and CAPA patients were previously immunocompetent and thus lacking classical risk factors.[50] They also do not present typical radiological findings (►**Table 2**), which hinders a timely diagnosis.[50] IAPA and CAPA have distinct clinical characteristics as well, for example in terms of time of development (IAPA develops earlier in the ICU admission than CAPA) and in terms of the use of systemic corticosteroids.[50] The immunopathogenesis of IAPA and CAPA is still not fully unraveled but results from the interplay between the viral infection, *Aspergillus* itself, and the host immune response. It is hypothesized that heterologous immunity can play a role in the interplay of viral and fungal coinfections.[36] Heterologous immunity describes the influence of the immune response to a primary pathogen on the immune response to an unrelated pathogen.[51] For instance, alveolar epithelial damage caused by a virus can facilitate protrusion of the fungus into the tissue. This adds to the classic release of proteases and mycotoxins by the germinating fungal spores, enhancing the epithelial damage. In response, the airway epithelium produces type I and type III interferons in a sustained and uncontrolled fashion, which has a significant impact on innate and adaptive antifungal immunity. This results in impaired fungal clearance from the airway and unrestrained infection.[36]

Invasive Tracheobronchial Aspergillosis

Tracheobronchial aspergillosis (TBA) can be classified into invasive, saprophytic (noninvasive), and allergic disease entities. Invasive tracheobronchial aspergillosis (ITBA) is a rare but distinct clinical presentation of acute IPA and causes ulcerative and, in a later phase, extensive pseudomembranous lesions to the trachea.[52] This disease is difficult to diagnose as radiographical findings are mostly absent or subtle[53] (►**Table 2**). The diagnosis is made by direct inspection through bronchoscopy (►**Fig. 3**) and the histological study of tissue biopsies.[1,54] Ulcerative ITBA is characterized by discrete tracheal or bronchial ulcerations or inflammatory

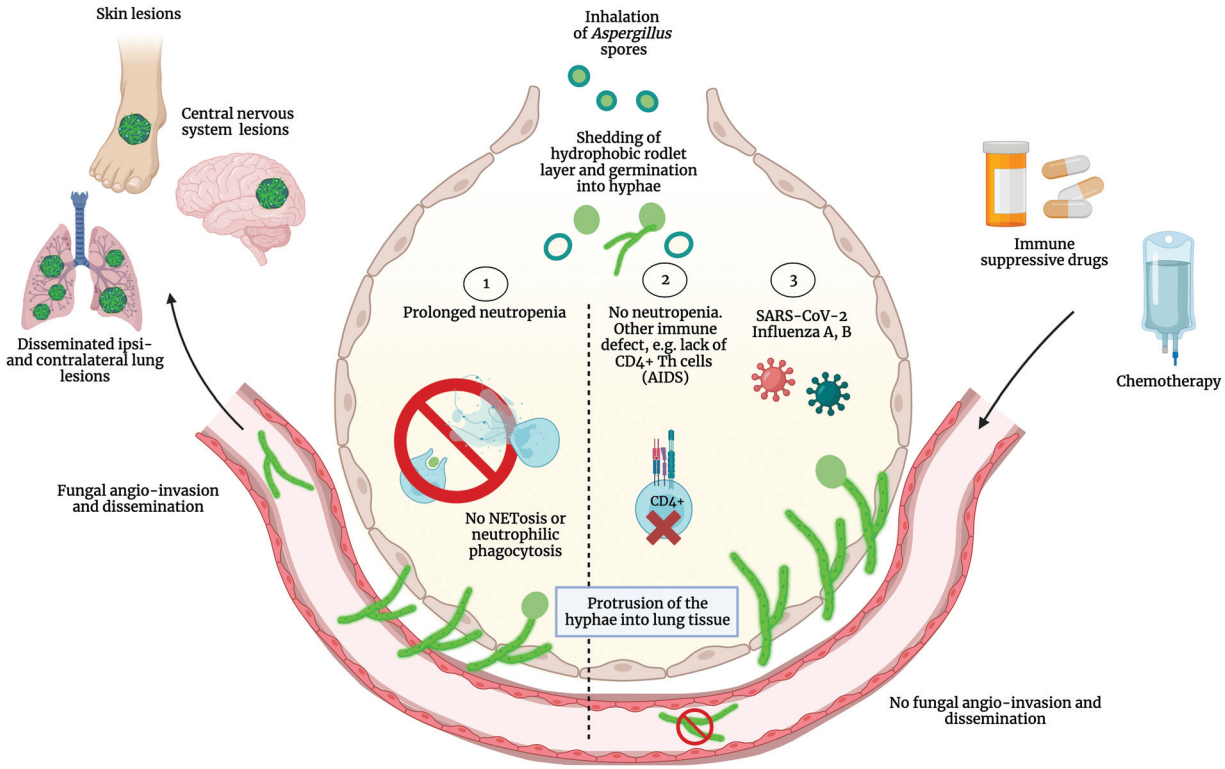

Fig. 2 *Pathogenesis of acute angio-invasive and tissue-invasive pulmonary aspergillosis (IPA). Aspergillus* spores are inhaled and, in the right circumstances, shed their hydrophobic rodlet layer and germinate into hyphae. In the absence of neutrophils (1), caused by the underlying disease or by the treatment regimen, neutrophil phagocytosis, neutrophil extracellular trap formation (NETosis) and neutrophil signaling is impaired, and fungal hyphae protrude into the lung tissue and the blood vessels, causing disseminated disease. In nonneutropenic patients, IPA can develop when another important immune defect is present, for example, lack of CD4 T cells in acquired immunodeficiency syndrome (AIDS) (2) or a severe acute respiratory syndrome coronavirus type 2 (SARS-CoV-2) or influenzavirus infection (3). However, angio-invasion is usually not observed without profound and prolonged neutropenia. Abbreviations: AIDS, acquired immunodeficiency syndrome; IPA, invasive pulmonary aspergillosis; NETosis, neutrophil extracellular trap formation; SARS-CoV-2, severe acute respiratory syndrome coronavirus type 2. This figure was created with BioRender.

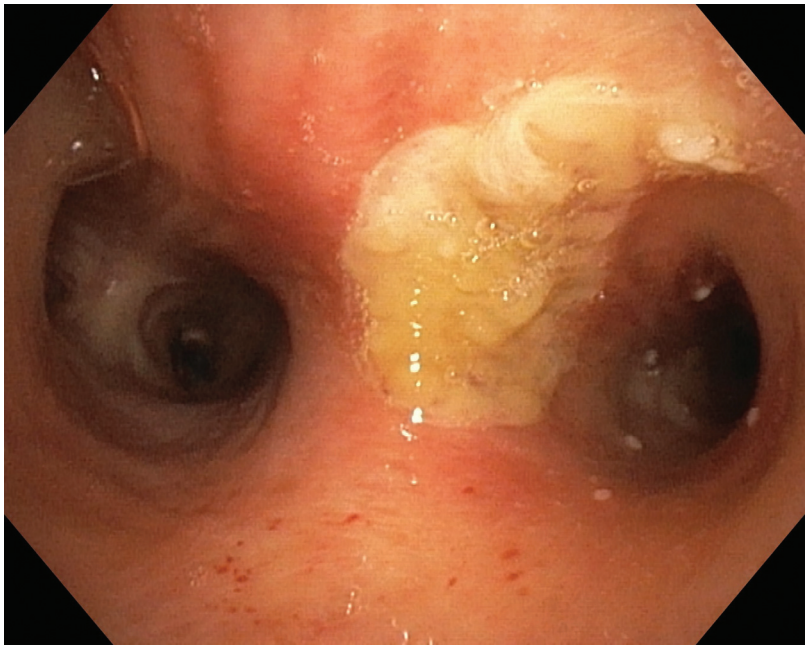

Fig. 3 *Ulcerative invasive tracheobronchial aspergillosis (ITBA).* Endoscopic image of ulcerative ITBA in a 43-year-old male that was treated for hairy cell leukemia. A sharply delineated ulcerative plaque covers the carina and a part of the left main stem bronchus. *A. fumigatus* was isolated from a cultured biopsy. *Image courtesy of Thomas Malfait, MD.*

plaques that have been described in people living with AIDS and in SOT recipients, mostly after lung transplantation.[52,55] This not only results from the intense immunosuppressive regimens but also from the allograft being directly exposed to fungi in the environment and from failure of the first barrier of defense, mucociliary clearance.[54] The mortality rate in lung transplant patients with ITBA is 23.7% and is favorable as compared to acute IPA, which has a mortality rate up to 81.5% in this population.[56] Local complications such as bronchomalacia, stenosis, and anastomotic dehiscence may occur though,[54] resulting in debilitating morbidity. Pseudomembranous ITBA is believed to evolve from ulcerative ITBA and is characterized by extensive pseudomembranes that cover the mucosa of a large part of the tracheobronchial tree, with fungal hyphae protruding in the mucosa and even the cartilage.[57,58] The excess of necrotic debris can even cause bronchial obstruction (pseudomembranous and obstructive TBA).[58] This presentation is described in severely immunocompromised patients suffering from hematologic malignancies or from GvHD in HSCT recipients.[38] The reported mortality rate of pseudomembranous ITBA is as high as 72.2% and an early diagnosis with prompt initiation of antifungal treatment is the key factor of survival.[52]

Subacute Invasive Aspergillosis

Subacute invasive aspergillosis (SAIA), previously termed chronic necrotizing aspergillosis, has clinical and radiological findings similar to those of chronic cavitary pulmonary aspergillosis (CCPA), but the disease progresses more rapidly, within three months[59] (►**Table 2**). The pulmonary cavities in which the disease develops enlarge quickly. On lung parenchyma biopsy, the hyphae protrude into the lung tissue and *Aspergillus*-specific antigens (galactomannan) are very likely to be detectable in broncho-alveolar lavage fluid (BALF). In contrast to acute IPA, SAIA develops in patients with moderate immune deficiencies such as iatrogenic immunosuppression because of underlying rheumatological or auto-immune disease (►**Table 1**).[59]

Noninvasive Manifestations of Pulmonary Aspergillosis: Impaired Mucosal Immunity

Chronic Pulmonary Aspergillosis

Chronic pulmonary aspergillosis (CPA) is an umbrella term for a spectrum of different disease entities with confinement of the fungal hyphae to the cavitary wall. The disease typically develops in patients with pre-existing pulmonary cavities caused by COPD, pulmonary tuberculosis (TB), cystic fibrosis (CF), connective tissue disease (CTD), bronchiectasis, thoracic radiotherapy, and allergic bronchopulmonary aspergillosis (ABPA). As a second susceptibility factor, these patients are often mildly immunocompromised due to conditions such as diabetes mellitus, alcoholism, malnutrition, advanced age, human immunodeficiency virus (HIV) infection, prolonged administration of corticosteroids or other moderately immunocompromising agents[3,59] (►**Table 1**). The greatest global burden of CPA develops following pulmonary TB (CPA prevalence of 1.74 million, affecting 30-81% of the CPA population depending on the study population),[60] whereas in low-TB-incidence countries, COPD is the most important underlying condition (29-48% of the CPA population).[61,62] Worldwide, a great number of CPA cases also evolve from underlying ABPA (CPA prevalence of 411.000) and sarcoidosis (CPA prevalence of 72.000).[63] The disease entities are defined by their radiological characteristics and the promptness by which the disease develops[59] (►**Table 2**).

Chronic Cavitary Pulmonary Aspergillosis

CCPA is characterized by one or more pulmonary cavities containing either solid or liquid material or a fungus ball. The diagnosis of CCPA requires chronic (>12 weeks) respiratory symptoms, characteristic radiological findings, and elevated *Aspergillus* specific immunoglobulin (Ig) G antibody or microbiological evidence in a person with no or minimal immunocompromise, usually with one or more underlying pulmonary disorders[38,59,64] (►**Tables 1** and **2**). If this condition is left untreated, cavities will enlarge and coalesce with the development of pericavitary infiltrates or even perforation into the pleural space and an aspergilloma may appear or disappear. This evolution shows the slow but malignant impact of the disease, and serological or microbiological evidence of *Aspergillus* spp. should be obtained timely.

Chronic Fibrosing Pulmonary Aspergillosis

Chronic fibrosing pulmonary aspergillosis (CFPA) is the debilitating end-stage presentation of CCPA with extensive solid pulmonary fibrotic destruction of at least two lung lobes with inlying pulmonary cavities, sometimes filled with aspergillomas.[63] This loss of lung tissue results in a major loss of pulmonary function. Serological or microbiological evidence implicating *Aspergillus* spp. is required for diagnosis[59] (►**Table 2**).

Single Aspergilloma

A single aspergilloma (SA) is a fungus ball in the lung cavity of an otherwise immunocompetent patient. It causes little or no symptoms. Serological or microbiological evidence of the presence of *Aspergillus* is possible but not obligatory. The cavity and the fungal ball remain unchanged over at least 3 months' time (►**Table 2**). The SA results from saprophytic growth in a lung cavity, that is, without infecting the epithelium and solely benefiting from the nutrients, humidity, and ideal environmental temperature of 37°C. The pathogenesis of SA is characterized by formation of a fungal biofilm, composed of hyphae embedded in an ECM.[19] This incites epithelial low-grade inflammation through mechanical stirring which can occasionally cause life-threatening hemoptysis.[59]

Aspergillus Nodule

An *Aspergillus* nodule is often a post-hoc diagnosis, after resection of one or more nodules (<3 cm), which do not usually cavitate and are not tissue invasive. They may mimic carcinoma of the lung, metastasis, tuberculoma, cryptococcoma, or nodular presentations of other pathogens and can

only be definitively diagnosed on histology (►**Table 2**). Nodules in patients with rheumatoid arthritis may be pure rheumatoid nodules or contain *Aspergillus*. If the lesions are larger than 3 centimeters, cavitation is common.[59,63]

Pathophysiology of Chronic Pulmonary Aspergillosis

The immunological processes leading to CPA are still unclear. CPA has been associated with a dysfunctional Th1/Th17 and NK-cell immune pathway in an immunocompetent host, determined by a significant impairment of IFN-γ, IL-12, and IL-17 production.[65,66] In addition, the possible role of Th2 inflammation and the role of serum IgE is under investigation.[67,68] Recently, the exposure of the respiratory epithelium to *Aspergillus* has been associated with the release of IL-33.[69–71] This is an epithelial alarmin, that activates ILC2s via the ST2 receptor, which in turn, release IL-5 and IL-13. Severe allergic inflammation is known to induce exhausted-like ILC2s with high expression of the inhibitory signal IL-10 and low expression of IL-5 and IL-13[66,69]. The high IL-10 expression may give rise to uncontrolled *Aspergillus* infection and may clarify why ABPA occasionally evolves to CPA.[66,69]

Noninvasive Tracheobronchial *Aspergillus* Disease

Aspergillus Colonization

Chronic airway colonization with *Aspergillus* spp. is determined by the isolation of an *Aspergillus* species from at least two lower respiratory tract samples in 1 year without other evidence of disease. Its exact repercussions have yet to be unraveled. Colonization is assumed to cause low-grade inflammation of the epithelium which can evolve into a clinical syndrome. For example, in lung transplant recipients, colonization with *Aspergillus* is a major risk factor for invasive aspergillosis, as well as for allograft failure due to chronic rejection.[54] The incidence of *Aspergillus* colonization after lung transplantation is up to 23%, and 4% of lung transplant candidates were already colonized pre lung transplant. Therefore, antifungal prophylaxis is commonly administered in lung transplant recipients, although the benefits and optimal regimens remain a subject of debate.[54] Moreover, the rate of *Aspergillus* colonization in lung transplant recipients is much higher among people living with CF (pwCF) compared to other underlying conditions. In a study by Samanta et al, 70% of pwCF had pretransplant *Aspergillus* colonization and 39% had *Aspergillus* recovered from intraoperative BALF.[54] Furthermore, in pwCF, airway colonization with *Aspergillus* is associated with a lower forced expiratory volume in 1 second in pwCF that were not chronically infected with *Pseudomonas aeruginosa*. The frequency of pulmonary exacerbations requiring antibiotic treatment in this population is also significantly higher than in pwCF without isolation of *Aspergillus* from their respiratory samples. In pwCF with cocolonization by *P. aeruginosa* and *Aspergillus* spp., the detrimental effect of the fungal presence is not clear anymore and might be veiled by the negative effect on lung function of *P. aeruginosa*.[72,73] Highly effective cystic fibrosis transmembrane conductance regulator (CFTR) modulator therapy caused a paradigm shift in CF treatment because it significantly increases pulmonary function and decreases exacerbation rate, in an unprecedented way. In pwCF who are not treated with CFTR modulators, airway colonization with *Aspergillus* is very common and estimated at 30%.[74] Up to date, it is not yet clear whether or not the introduction of CFTR modulators reduces the burden of fungal lung disease in CF.[75,76]

Aspergillus Bronchitis

A. fumigatus is the most prevalent colonizing fungus in CF respiratory samples, and *Aspergillus* colonization may cause acute or chronic *Aspergillus* bronchitis in pwCF and bronchiectasis.[77] Chronically affected patients present with recurrent, frequently relapsing acute bronchitis. They report thick sputum and shortness of breath. *Aspergillus* bronchitis is determined by active colonization with *Aspergillus*, absence of pulmonary infiltrates, no response to antibiotic treatment, total serum IgE levels <200 kU/L (exclusion of ABPA, a disease that also presents with mucus impaction) and treatment response to antifungal therapy. Clinically, the disease is indistinctive from CF lung disease. A prevalence of 9 to 30% in the risk population is reported, depending on which criteria are used.[73,74,77] Plastic bronchitis is a rare complication of *Aspergillus* bronchitis and entails mucoid impaction, requiring urgent bronchoscopic removal.[62]

Saprophytic Tracheobronchial Aspergillosis

Mucoid impaction, endobronchial aspergillosis, and obstructing bronchial aspergillosis are three saprophytic TBA presentations. These disease entities show a level of mucoid bronchial obstruction with the abundant presence of *Aspergillus* spp. without evidence of invasion or allergic reaction. Saprophytic TBA can be found in ABPA and also in asthma with fungal sensitization as well as nonallergic conditions, such as AIDS.[52]

Allergic Manifestations: Misdirected Acquired Immunity Toward *Aspergillus*

Aspergillus can also cause allergic fungal airway disease. Allergy is caused by allergens and allergens are defined by IgE binding. In *Aspergillus* spp., 195 allergenic proteins are described, with 72 specifically found in *A. fumigatus*.[78] The allergenic proteins are not always pathogen specific, many (up to 60%) are shared across species and genera.[79,80]

Asthma Sensitized with *Aspergillus* spp.

Asthma is a chronic inflammatory airway disease that occurs across all societies, ages, genders, health statuses, and social statuses. More than 360 million people worldwide have been diagnosed with asthma, and its prevalence is increasing.[81] Asthma symptoms comprise cough, mucus expectoration, chest tightness, wheezing, and (nocturnal) shortness of breath. Fungal sensitization is indicated by skin test positivity to *Aspergillus* antigens or elevated *Aspergillus* specific IgE levels. Exposure to *Aspergillus* is linked with worsening of asthma and sensitization to the pathogen has been

associated with increased asthma severity, increased hospital and intensive care admissions and even death in adults.[24] Severe cases are often termed severe asthma with fungal sensitization and encompass one-third of the patients suffering from severe asthma.[82,83]

Pathophysiology of Asthma Sensitized with *Aspergillus* spp.

Although fungal sensitized asthma and ABPA are presented as distinct manifestations of allergic pulmonary disease, it is generally accepted that the underlying pathophysiological mechanisms are similar. Both disease entities are characterized by IgE sensitization to filamentous fungi and eosinophilic inflammation through exaggerated Th2 inflammation.[82] Th2 inflammation and endotyping in asthma have been extensively studied and led to the development of targeted therapies.[84–86] Conversely, little is known about whether the fungus plays an active role, apart from its allergenic features. A key insight in this matter is that many fungal allergens are proteases that directly affect the respiratory epithelium through the generation of inflammatory signals and the recruitment and activation of immune cells.[87] *Aspergillus* secretes the clinically important allergen, alkaline protease 1 (also known as Asp f 13). In an asthma mouse model, Alp1 infiltrates the bronchial mucosa and provokes smooth muscle contraction and bronchoconstriction by degrading the ECM.[88] Furthermore, this infiltration causes junctional damage and mechanical stress. This is sensed by the mechanosensitive calcium channel TRPV4 (transient receptor potential cation channel subfamily V member 4) and causes calcium influx and calcineurin signaling within murine bronchiolar club cells, which results in a danger signal eliciting T helper cell-dependent lung eosinophilia[89] and murine Alp1 sensitization[89] (►**Fig. 5**, panel A). Moreover, the prototypical alarmin IL-33 was recently proposed to act as a soluble protease sensor that enables host cells to react to the threat of tissue injury. Uncharacterized *Aspergillus* proteases cleave IL-33 into a highly active form that activates ILC2s via the ST2 receptor to produce type 2 cytokines and drive IL-5-dependent eosinophil recruitment to the lungs[90] (►**Fig. 5**, panel A).

Allergic Bronchopulmonary Aspergillosis

ABPA almost exclusively occurs in people living with asthma (pwA) or CF. The highest prevalence is found in pwCF, estimated at 10% (range 3–25%).[91,92] ABPA is characterized by an overzealous hypersensitivity reaction to *Aspergillus* antigens, which leads to bronchial inflammation, mucus plugging (►**Fig. 4**), airway destruction, and fibrosis (bronchiectasis).[91] ABPA is associated with increased morbidity and accelerated lung function decline.[93] Existing diagnostic criteria, such as the CF Foundation (CFF) criteria for pwCF[94] or the Agarwal criteria for pwA,[95] rely on the combination of clinical signs and symptoms, chest radiography or computed tomography, and the presence of biomarkers such as total and *Aspergillus*-specific IgE and IgG.[91,96] Nevertheless, these combined criteria remain nonspecific, rendering the diagnosis of ABPA challenging.[94,96] ABPA is preceded by *Aspergillus* sensitization, which has a prevalence varying from 20 to 65% in pwCF.[92] Both the European CF Society and the United States CFF recommend annual screening for *Aspergillus* sensitization and ABPA.[97,98]

Pathophysiology of Allergic Bronchopulmonary Aspergillosis

In susceptible pwA or pwCF, APCs process *Aspergillus* antigens and present HLA-DR2- and HLA-DR5-restricted peptides to CD4 T-cells in the bronchoalveolar lymphoid tissue. This leads to differentiation in CD4 Th2 cells which subsequently release Th2 cytokines, such as IL-4, IL-5, and IL-13, as is described in Th2-high asthma. The IL-4-driven activation of B-lymphocytes results in isotype switching to IgE and an exorbitant production of IgE, IgG, and IgA,[99] facilitated in CF through a higher sensitivity to IL-4.[100] The combination of antibody production and the released cytokines launch mast cell and eosinophil degranulation, thereby releasing additional inflammatory mediators which further aggravate bronchial inflammation and bronchoconstriction.[91,99,101] This type-2 immune response causes the formation of allergic mucin, a significant alteration of the airway mucus, making it elastic and sticky. In all diseases where allergic mucin has been described, including asthma and ABPA, bipyramidal Charcot–Leyden crystals (CLCs) are abundantly present[102,103] (►**Figs. 4** and **5**). The constituent protein of these crystals is dimeric galectin-10 (Gal-10), which assembles into CLCs in the extracellular space upon release from eosinophils undergoing eosinophil extracellular trap cell death (EETosis).[104,105] It is demonstrated that CLCs are not only markers of eosinophilic inflammation but they also actively promote key features of asthma, including neutrophilic inflammation with the release of neutrophil extracellular traps (NETosis).[106] NETosis in turn not only causes a great amount of sputum extracellular DNA, which forms the rationale for the therapeutic use of inhaled DNase in pwCF, but also causes oxidative stress. This oxidative stress results in mucin (e.g., MUC5AC) crosslinking and increased tenacity of mucus[104] (►**Fig. 5**, *panel B*).

Bronchocentric Granulomatosis

Bronchocentric granulomatosis is characterized by the formation of necrotizing granulomas containing numerous inflammatory cells (mainly eosinophils) as a reaction to *Aspergillus* spp. These granulomas may destroy the bronchioles and cause bronchiolectasis. The inflammation results in mucoid impaction of the airway lumen (►**Fig. 6**). The necrotizing granulomas contain *Aspergillus* hyphae, without tissue invasion. Bronchocentric granulomatosis is a well-documented bronchial presentation of ABPA, but ABPA is no prerequisite.[107]

Hypersensitivity Pneumonitis

This disease entity is also called extrinsic allergic alveolitis. Hypersensitivity pneumonitis (HP) is an inflammatory and/or fibrotic disease, affecting the lung parenchyma and small airways, and manifests as an interstitial lung disease. It

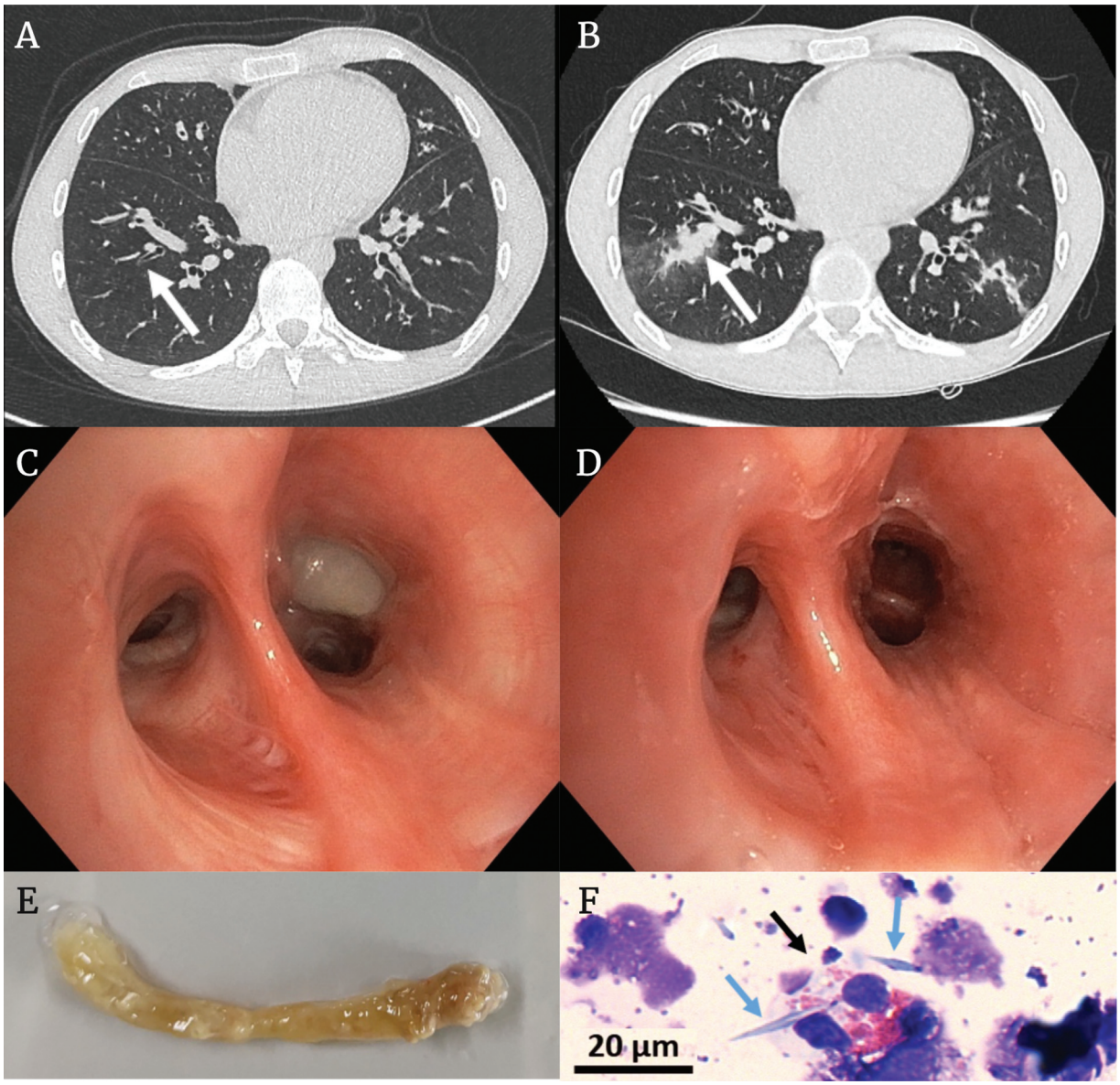

Fig. 4 *Mucusplugging in the right lower lobe of a patient with cystic fibrosis and allergic bronchopulmonary aspergillosis (ABPA).* Panel A shows a multidetector computed tomography (MDCT) section with an unplugged bronchus in the right lower lobe (indicated by the arrow), whereas in panel B, this very airway is plugged, causing lung parenchyma consolidation and ground-glass opacification along the more peripheral tract of the bronchus (indicated by the arrow). In panel C, an endoscopic image is shown with complete obliteration of the lateral segment of the right lower lobe by a mucus plug. In panel D, this plug is removed, revealing inflammatory bronchial epithelium. In panel E, a photograph of the removed mucus plug is shown, its total length is 4 centimeter. In panel F, a Rapid-Chrome Kwik–Diff staining from this sputum plug cytospin is shown. An eosinophil is indicated with the black arrow and two Charcot–Leyden crystals are indicated with the blue arrows. Endoscopic images courtesy of Yannick Vande Weygaerde, MD.

typically results from a type III or IV hypersensitivity reaction provoked by an overt or occult inhaled antigen in susceptible individuals. However, a consensus definition is lacking.[108] Intense exposure to *Aspergillus* antigens may result in HP. As the ecological niche of *Aspergillus* is decaying organic material, it is not surprising that a large inoculum is set free when people are professionally exposed to moldy hay, malt, or flour[109,110] (►**Table 1**). The same exposure may result either in HP or in IPA depending on the host's underlying immune status.[109] Massive spore exposure may result in infection rather than an allergic response but he coexistence of both entities also remains a possibility.[3] HP is a disease with heterogeneous clinical presentations and outcomes. According to the latest ATS/JRS/ALAT Clinical Practice Guideline (2020), the disease is classified into fibrotic and nonfibrotic as the presence of radiological or histopathological signs of fibrosis are the primary determinants of the prognosis. Clinical signs, such as dyspnea, cough, and mid-inspiratory squeaks, overlap with those of other acute and chronic lung diseases.[111] Constitutional symptoms such as weight loss, low-grade fever, and malaise are less frequent (►**Table 2**). The relationship between exposure to a certain antigen and development of symptoms can be an important clue for the diagnosis.

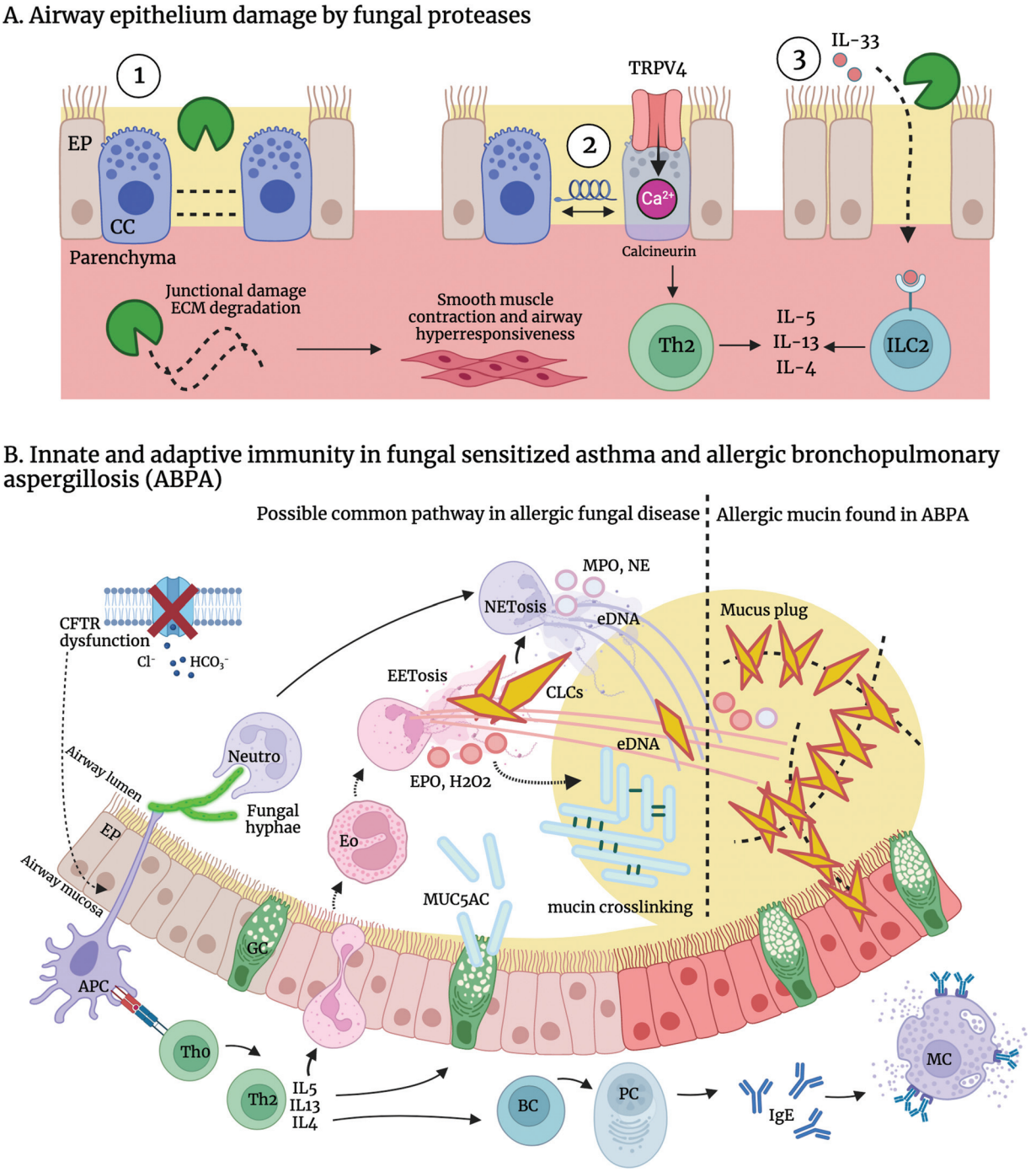

Fig. 5 *The pathogenesis of fungal sensitized asthma and allergic bronchopulmonary aspergillosis (ABPA).* Panel A shows how fungal allergens act as proteases that directly affect the respiratory epithelium: (1) in murine models, alkaline serine protease 1 (Alp1) degrades club cell junctions and the underlying extracellular matrix. This leads to smooth muscle contraction and airway hyperresponsiveness. (2) The junctional damage activates the mechanosensitive calcium channel TRPV4, which in turn causes calcium influx, calcineurin signaling and induction of a Th2 immunological response. (3) *Aspergillus* proteases cleave IL-33 into a highly active form that activates ILC2s to produce type 2 cytokines and drive IL-5-dependent eosinophil recruitment to the lungs. Panel B shows that Th2 immunity and mucus plug formation are the underlying immunopathogenesis of allergic fungal airway disease with ABPA as the most advanced presentation. In ABPA, Charcot–Leyden crystals (CLCs) tie the components of the plug together in a complex mesh. See text for a detailed description. Abbreviations: Alp1, alkaline serine protease 1; APC, antigen-presenting cell; BC, B cell; CC, club cell; ECM, extracellular matrix; eDNA, extracellular DNA; EET, eosinophil extracellular trap; Eo, eosinophil; EP, epithelium; EPO, eosinophil peroxidase; Gal-10: galectin-10; GC, goblet cell; H2O2, hydrogen peroxide; Ig, immunoglobulin; IL, interleukin; ILC2, innate like cell type 2; MC, mast cell; MPO, myeloperoxidase; NE, neutrophil elastase; NET, neutrophil extracellular trap; Neutro, neutrophil; PC, plasma cell; Th, T helper; TRPV4, transient receptor potential cation channel subfamily V member 4. This figure was created with BioRender.

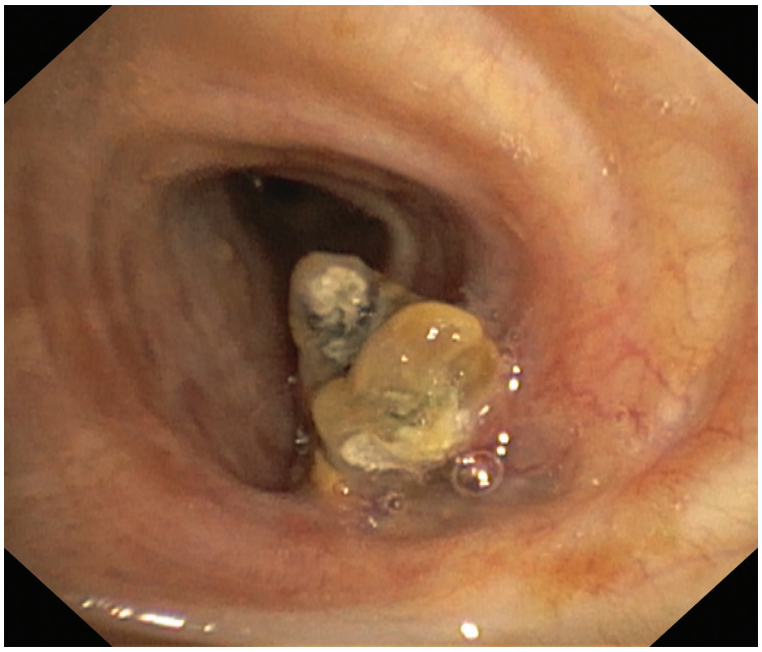

Fig. 6 *Bronchocentric granulomatosis.* Endoscopic image of bronchocentric granulomatosis in an 82-year-old female with a history of pulmonary tuberculosis. The granuloma is calcified and overgrown with *Aspergillus* hyphae. Image courtesy of Thomas Malfait, MD and Philippe Rogiers, MD.

Conclusion

The continuous interplay between *Aspergillus* and the human lung causes a wide variety of clinical syndromes in susceptible patients. The disease presentation is steered by the host's immune defect, which can be classified into impaired cell-mediated immune responses, impaired mucosal barrier integrity, and hyperresponsiveness. In the presence of *Aspergillus* spp., this results respectively in invasive disease, noninvasive (saprophytic) disease, and/or allergic disease.

Funding
I.J., B.N.L., and E.V.B. receive funding from an EOS consortium grant (G0H1222N) and the Forton Fund and Belgian Cystic Fibrosis Association through the King Baudouin Foundation.

Conflicts of Interest
None declared. E.V.B. is chair of the Chronic Pulmonary Aspergillosis Network (CPAnet).

References

1 Patterson TF. Aspergillus Species. In: Mandell, Douglas, and Bennett's Principles and Practice of Infectious Diseases. Elsevier; 2019
2 Griffiths JS, Camilli G, Kotowicz NK, Ho J, Richardson JP, Naglik JR. Role for IL-1 family cytokines in fungal infections. Front Microbiol 2021;12:633047
3 Kosmidis C, Denning DW. The clinical spectrum of pulmonary aspergillosis. Thorax 2015;70(03):270–277
4 Brown GD, Denning DW, Gow NAR, Levitz SM, Netea MG, White TC. Hidden killers: human fungal infections. Sci Transl Med 2012;4(165):165rv13
5 Ainsworth GC. Introduction to the History of Mycology. Cambridge University Press;; 1976
6 Balajee SA, Houbraken J, Verweij PE, et al. Aspergillus species identification in the clinical setting. Stud Mycol 2007;59:39–46
7 Index Fungorum [Database on the Internet]. Index Fungorum Partnership. Accessed September 11, 2023 at: Https://Www.Indexfungorum.Org.2023
8 Sugui JA, Kwon-Chung KJ, Juvvadi PR, Latgé JP, Steinbach WJ. *Aspergillus fumigatus* and related species. Cold Spring Harb Perspect Med 2014;5(02):a019786–a019786
9 Tekaia F, Latgé JP. *Aspergillus fumigatus*: saprophyte or pathogen? Curr Opin Microbiol 2005;8(04):385–392
10 Pini G, Faggi E, Donato R, Sacco C, Fanci R. Invasive pulmonary aspergillosis in neutropenic patients and the influence of hospital renovation. Mycoses 2008;51(02):117–122
11 Abdel Hameed AA, Yasser IH, Khoder IM. Indoor air quality during renovation actions: a case study. J Environ Monit 2004;6(09):740–744
12 Abad A, Fernández-Molina JV, Bikandi J, et al. What makes *Aspergillus fumigatus* a successful pathogen? Genes and molecules involved in invasive aspergillosis. Rev Iberoam Micol 2010;27(04):155–182
13 Park SJ, Mehrad B. Innate immunity to Aspergillus species. Clin Microbiol Rev 2009;22(04):535–551
14 Sutton DA, Fothergill AW, Rinaldi MG. Guide to Clinically Significant Fungi. 1st ed. Williams & Wilkins; 1998
15 Gugnani HC. Ecology and taxonomy of pathogenic aspergilli. Front Biosci 2003;8:s346–s357
16 Agarwal R, Sehgal IS, Dhooria S, et al. Allergic bronchopulmonary aspergillosis. Indian J Med Res 2020;151(06):529–549
17 Carrion SdeJ, Leal SM Jr, Ghannoum MA, Aimanianda V, Latgé JP, Pearlman E. The RodA hydrophobin on Aspergillus fumigatus spores masks dectin-1- and dectin-2-dependent responses and enhances fungal survival in vivo. J Immunol 2013;191(05):2581–2588
18 van de Veerdonk FL, Gresnigt MS, Romani L, Netea MG, Latgé JP. Aspergillus fumigatus morphology and dynamic host interactions. Nat Rev Microbiol 2017;15(11):661–674

19 Beauvais A, Latgé JP. Aspergillus biofilm in vitro and in vivo. Microbiol Spectr 2015;3(04):
20 de Vries RP, Visser J. Aspergillus enzymes involved in degradation of plant cell wall polysaccharides. Microbiol Mol Biol Rev 2001;65(04):497–522
21 Moore MM. The crucial role of iron uptake in *Aspergillus fumigatus* virulence. Curr Opin Microbiol 2013;16(06):692–699
22 Moreno MA, Ibrahim-Granet O, Vicentefranqueira R, et al. The regulation of zinc homeostasis by the ZafA transcriptional activator is essential for Aspergillus fumigatus virulence. Mol Microbiol 2007;64(05):1182–1197
23 Rautemaa-Richardson R, Richardson MD. Systemic fungal infections. Medicine (Baltimore) 2021;49(12):760–765
24 Romani L. Immunity to fungal infections. Nat Rev Immunol 2011; 11(04):275–288
25 Garlanda C, Hirsch E, Bozza S, et al. Non-redundant role of the long pentraxin PTX3 in anti-fungal innate immune response. Nature 2002;420(6912):182–186
26 Cunha C, Aversa F, Lacerda JF, et al. Genetic PTX3 deficiency and aspergillosis in stem-cell transplantation. N Engl J Med 2014;370 (05):421–432
27 Idol RA, Bhattacharya S, Huang G, et al. Neutrophil and macrophage NADPH oxidase 2 differentially control responses to inflammation and to *Aspergillus fumigatus* in mice. J Immunol 2022;209(10):1960–1972
28 Röhm M, Grimm MJ, D'Auria AC, Almyroudis NG, Segal BH, Urban CF. NADPH oxidase promotes neutrophil extracellular trap formation in pulmonary aspergillosis. Infect Immun 2014;82(05): 1766–1777
29 Branzk N, Lubojemska A, Hardison SE, et al. Neutrophils sense microbe size and selectively release neutrophil extracellular traps in response to large pathogens. Nat Immunol 2014;15 (11):1017–1025
30 Gazendam RP, van Hamme JL, Tool ATJ, et al. Human neutrophils use different mechanisms to kill aspergillus fumigatus conidia and hyphae: evidence from phagocyte defects. J Immunol 2016; 196(03):1272–1283
31 McCormick A, Heesemann L, Wagener J, et al. NETs formed by human neutrophils inhibit growth of the pathogenic mold Aspergillus fumigatus. Microbes Infect 2010;12(12-13):928–936
32 Block H, Zarbock A. A fragile balance: does neutrophil extracellular trap formation drive pulmonary disease progression? Cells 2021;10(08):1932
33 Cenci E, Perito S, Enssle KH, et al. Th1 and Th2 cytokines in mice with invasive aspergillosis. Infect Immun 1997;65(02):564–570
34 Knutsen AP. Lymphocytes in allergic bronchopulmonary aspergillosis. Front Biosci 2003;8(04):d589–d602
35 Moretti S, Renga G, Oikonomou V, et al. A mast cell-ILC2-Th9 pathway promotes lung inflammation in cystic fibrosis. Nat Commun 2017;8:14017
36 Salazar F, Bignell E, Brown GD, Cook PC, Warris A. Pathogenesis of respiratory viral and fungal coinfections. Clin Microbiol Rev 2022;35(01):e0009421
37 Schneider DS, Ayres JS. Two ways to survive infection: what resistance and tolerance can teach us about treating infectious diseases. Nat Rev Immunol 2008;8(11):889–895
38 Patterson TF, Thompson GR III, Denning DW, et al. Practice guidelines for the diagnosis and management of Aspergillosis: 2016 update by the infectious diseases Society of America. Clin Infect Dis 2016;63(04):e1–e60
39 Segal BH. Aspergillosis. N Engl J Med 2009;360(18):1870–1884
40 Colombo AL, de Almeida Júnior JN, Slavin MA, Chen SCA, Sorrell TC. Candida and invasive mould diseases in non-neutropenic critically ill patients and patients with haematological cancer. Lancet Infect Dis 2017;17(11):e344–e356
41 Herbrecht R, Denning DW, Patterson TF, et al. Invasive Fungal Infections Group of the European Organisation for Research and Treatment of Cancer and the Global Aspergillus Study Group. Voriconazole versus amphotericin B for primary therapy of invasive aspergillosis. N Engl J Med 2002;347(06):408–415
42 Uyeki TM, Bernstein HH, Bradley JS, et al. Clinical Practice Guidelines by the Infectious Diseases Society of America: 2018 Update on Diagnosis, Treatment, Chemoprophylaxis, and Institutional Outbreak Management of Seasonal Influenzaa. Clin Infect Dis 2019;68(06):895–902
43 Lin SJ, Schranz J, Teutsch SM. Aspergillosis case-fatality rate: systematic review of the literature. Clin Infect Dis 2001;32(03): 358–366
44 Gerson SL, Talbot GH, Hurwitz S, Strom BL, Lusk EJ, Cassileth PA. Prolonged granulocytopenia: the major risk factor for invasive pulmonary aspergillosis in patients with acute leukemia. Ann Intern Med 1984;100(03):345–351
45 Hope WW, Walsh TJ, Denning DW. The invasive and saprophytic syndromes due to Aspergillus spp. Med Mycol 2005;43(Suppl 1): S207–S238
46 Kauffman CA, Freifeld AG, Andes DR, et al. Endemic fungal infections in solid organ and hematopoietic cell transplant recipients enrolled in the Transplant-Associated Infection Surveillance Network (TRANSNET). Transpl Infect Dis 2014;16(02): 213–224
47 Schauwvlieghe AFAD, Rijnders BJA, Philips N, et al; Dutch-Belgian Mycosis study group. Invasive aspergillosis in patients admitted to the intensive care unit with severe influenza: a retrospective cohort study. Lancet Respir Med 2018;6(10): 782–792
48 van Arkel ALE, Rijpstra TA, Belderbos HNA, van Wijngaarden P, Verweij PE, Bentvelsen RG. COVID-19-associated pulmonary aspergillosis. Am J Respir Crit Care Med 2020;202(01):132–135
49 White PL, Dhillon R, Cordey A, et al. A national strategy to diagnose coronavirus disease 2019-associated invasive fungal disease in the intensive care unit. Clin Infect Dis 2021;73(07): e1634–e1644
50 Dewi IM, Janssen NA, Rosati D, et al. Invasive pulmonary aspergillosis associated with viral pneumonitis. Curr Opin Microbiol 2021;62:21–27
51 Balz K, Trassl L, Härtel V, Nelson PP, Skevaki C, Virus-Induced T. Virus-induced T cell-mediated heterologous immunity and vaccine development. Front Immunol 2020;11:513
52 Krenke R, Grabczak EM. Tracheobronchial manifestations of Aspergillus infections. ScientificWorldJournal 2011;11: 2310–2329
53 Nishiyama KH, Falcão Ede AA, Kay FU, Teles GBS, Bernardi FdelC, Funari Mde GAcute tracheobronchitis caused by Aspergillus: case report and imaging findings. Radiol Bras 2014;47(05): 317–319
54 Samanta P, Clancy CJ, Nguyen MH. Fungal infections in lung transplantation. J Thorac Dis 2021;13(11):6695–6707
55 Kemper CA, Hostetler JS, Follansbee SE, et al. Ulcerative and plaque-like tracheobronchitis due to infection with Aspergillus in patients with AIDS. Clin Infect Dis 1993;17(03):344–352d
56 Singh N, Husain S. Aspergillus infections after lung transplantation: clinical differences in type of transplant and implications for management. J Heart Lung Transplant 2003;22(03):258–266
57 Denning DW. Commentary: unusual manifestations of aspergillosis. Thorax 1995;50(07):812–813
58 Kramer MR, Denning DW, Marshall SE, et al. Ulcerative tracheobronchitis after lung transplantation. A new form of invasive aspergillosis. Am Rev Respir Dis 1991;144(3 Pt 1):552–556
59 Denning DW, Cadranel J, Beigelman-Aubry C, et al; European Society for Clinical Microbiology and Infectious Diseases and European Respiratory Society. Chronic pulmonary aspergillosis: rationale and clinical guidelines for diagnosis and management. Eur Respir J 2016;47(01):45–68
60 Denning DW, Pleuvry A, Cole DC. Global burden of chronic pulmonary aspergillosis as a sequel to pulmonary tuberculosis. Bull World Health Organ 2011;89(12):864–872

61 Laursen CB, Davidsen JR, Van Acker L, et al. CPAnet Registry—An International Chronic Pulmonary Aspergillosis Registry. J Fungi (Basel) 2020;6(03):96
62 Salzer HJF, Heyckendorf J, Kalsdorf B, Rolling T, Lange C. Characterization of patients with chronic pulmonary aspergillosis according to the new ESCMID/ERS/ECMM and IDSA guidelines. Mycoses 2017;60(02):136–142
63 Denning DW, Riniotis K, Dobrashian R, Sambatakou H. Chronic cavitary and fibrosing pulmonary and pleural aspergillosis: case series, proposed nomenclature change, and review. Clin Infect Dis 2003;37(Suppl 3):S265–S280
64 Salzer HJF, Reimann M, Oertel C, et al; CPAnet. Aspergillus-specific IgG antibodies for diagnosing chronic pulmonary aspergillosis compared to the reference standard. Clin Microbiol Infect 2023:S1198-743X(23)00416-0
65 Bongomin F, Harris C, Foden P, Kosmidis C, Denning DW. Innate and Adaptive Immune Defects In Chronic Pulmonary Aspergillosis. J Fungi (Basel) 2017;3(02):26
66 Colombo SAP, Hashad R, Denning DW, et al. Defective interferon-gamma production is common in chronic pulmonary aspergillosis. J Infect Dis 2022;225(10):1822–1831
67 Watanabe S, Suzuki J, Suzukawa M, et al. Serum total IgE may be a biomarker among chronic pulmonary aspergillosis patients with elevated serum total IgE levels: a cohort study with pathological evaluations. Med Mycol 2022;60(03):myac006
68 Sehgal IS, Dhooria S, Muthu V, et al. Identification of distinct immunophenotypes in chronic pulmonary aspergillosis using cluster analysis. Mycoses 2023;66(04):299–303
69 Ito Y, Takazono T, Obase Y, et al. Serum cytokines usefulness for understanding the pathology in allergic bronchopulmonary aspergillosis and chronic pulmonary aspergillosis. J Fungi (Basel) 2022;8(05):436
70 Khosravi AR, Shokri H, Hassan Al-Heidary S, Ghafarifar F. Evaluation of murine lung epithelial cells (TC-1 JHU-1) line to develop Th2-promoting cytokines IL-25/IL-33/TSLP and genes Tlr2/Tlr4 in response to *Aspergillus fumigatus*. J Mycol Med 2018;28(02): 349–354
71 Garth JM, Reeder KM, Godwin MS, et al. IL-33 signaling regulates innate IL-17A and IL-22 production via suppression of prostaglandin E_2 during Lung Fungal Infection. J Immunol 2017;199 (06):2140–2148
72 Düesberg U, Wosniok J, Naehrlich L, Eschenhagen P, Schwarz C. Risk factors for respiratory *Aspergillus fumigatus* in German Cystic Fibrosis patients and impact on lung function. Sci Rep 2020;10(01):18999
73 Brandt C, Roehmel J, Rickerts V, Melichar V, Niemann N, Schwarz C. Aspergillus bronchitis in patients with cystic fibrosis. Mycopathologia 2018;183(01):61–69
74 Armstead J, Morris J, Denning DW. Multi-country estimate of different manifestations of aspergillosis in cystic fibrosis. PLoS One 2014;9(06):e98502
75 European Cystic Fibrosis Society. Accessed September 26, 2023 at: Https://www.Ecfs.Eu/Projects/Ecfs-Patient-Registry/Annual-Reports;2023
76 Schwarz C. Clinical relevance of fungi in cystic fibrosis. Semin Respir Crit Care Med 2023;44(02):252–259
77 Chrdle A, Mustakim S, Bright-Thomas RJ, Baxter CG, Felton T, Denning DW. Aspergillus bronchitis without significant immunocompromise. Ann N Y Acad Sci 2012;1272:73–85
78 Accessed September 14, 2023 at: https://www.allergome.org
79 Denning DW, Pfavayi LT. Poorly controlled asthma—-easy wins and future prospects for addressing fungal allergy. Allergol Int 2023;72(04):493–506
80 Knutsen AP, Bush RK, Demain JG, et al. Fungi and allergic lower respiratory tract diseases. J Allergy Clin Immunol 2012;129(02): 280–291, quiz 292–293
81 Pavord ID, Beasley R, Agusti A, et al. After asthma: redefining airways diseases. Lancet 2018;391(10118):350–400
82 Wardlaw AJ, Rick EM, Pur Ozyigit L, Scadding A, Gaillard EA, Pashley CH. New perspectives in the diagnosis and management of allergic fungal airway disease. J Asthma Allergy 2021; 14:557–573
83 O'Driscoll BR, Hopkinson LC, Denning DW. Mold sensitization is common amongst patients with severe asthma requiring multiple hospital admissions. BMC Pulm Med 2005;5:4
84 Brusselle GG, Koppelman GH. Biologic therapies for severe asthma. N Engl J Med 2022;386(02):157–171
85 Ray A, Oriss TB, Wenzel SE. Emerging molecular phenotypes of asthma. Am J Physiol Lung Cell Mol Physiol 2015;308(02): L130–L140
86 Lambrecht BN, Hammad H, Fahy JV. The cytokines of asthma. Immunity 2019;50(04):975–991
87 Wiesner DL, Klein BS. Lung epithelium: barrier immunity to inhaled fungi and driver of fungal-associated allergic asthma. Curr Opin Microbiol 2017;40:8–13
88 Balenga NA, Klichinsky M, Xie Z, et al. A fungal protease allergen provokes airway hyper-responsiveness in asthma. Nat Commun 2015;6:6763
89 Wiesner DL, Merkhofer RM, Ober C, et al. Club cell TRPV4 serves as a damage sensor driving lung allergic inflammation. Cell Host Microbe 2020;27(04):614–628.e6
90 Cayrol C, Duval A, Schmitt P, et al. Environmental allergens induce allergic inflammation through proteolytic maturation of IL-33. Nat Immunol 2018;19(04):375–385
91 Janahi IA, Rehman A, Al-Naimi AR. Allergic bronchopulmonary aspergillosis in patients with cystic fibrosis. Ann Thorac Med 2017;12(02):74–82
92 Maturu VN, Agarwal R. Prevalence of Aspergillus sensitization and allergic bronchopulmonary aspergillosis in cystic fibrosis: systematic review and meta-analysis. Clin Exp Allergy 2015;45 (12):1765–1778
93 De Baets F, De Keyzer L, Van Daele S, et al. Risk factors and impact of allergic bronchopulmonary aspergillosis in Pseudomonas aeruginosa-negative CF patients. Pediatr Allergy Immunol 2018;29(07):726–731
94 Stevens DA, Moss RB, Kurup VP, et al; Participants in the Cystic Fibrosis Foundation Consensus Conference. Allergic bronchopulmonary aspergillosis in cystic fibrosis–state of the art: Cystic Fibrosis Foundation Consensus Conference. Clin Infect Dis 2003; 37(Suppl 3):S225–S264
95 Agarwal R, Sehgal IS, Dhooria S, Aggarwal AN. Developments in the diagnosis and treatment of allergic bronchopulmonary aspergillosis. Expert Rev Respir Med 2016;10(12):1317–1334
96 Steels S, Proesmans M, Bossuyt X, Dupont L, Frans G. Laboratory biomarkers in the diagnosis and follow-up of treatment of allergic bronchopulmonary aspergillosis in cystic fibrosis. Crit Rev Clin Lab Sci 2023;60(01):1–24
97 Ohn M, Robinson P, Selvadurai H, Fitzgerald DA. Question 11: how should allergic bronchopulmonary aspergillosis [ABPA] be managed in cystic fibrosis? Paediatr Respir Rev 2017;24:35–38
98 Castellani C, Duff AJA, Bell SC, et al. ECFS best practice guidelines: the 2018 revision. J Cyst Fibros 2018;17(02):153–178
99 Knutsen AP, Slavin RG. Allergic bronchopulmonary aspergillosis in asthma and cystic fibrosis. Clin Dev Immunol 2011;2011:843763
100 Knutsen AP, Hutchinson PS, Albers GM, Consolino J, Smick J, Kurup VP. Increased sensitivity to IL-4 in cystic fibrosis patients with allergic bronchopulmonary aspergillosis. Allergy 2004;59 (01):81–87
101 Lameire S, Hammad H. Lung epithelial cells: upstream targets in type 2-high asthma. Eur J Immunol 2023:e2250106
102 Jelihovsky T. The structure of bronchial plugs in mucoid impaction, bronchocentric granulomatosis and asthma. Histopathology 1983;7(02):153–167
103 Katzenstein AL, Liebow AA, Friedman PJ. Bronchocentric granulomatosis, mucoid impaction, and hypersensitivity reactions to fungi. Am Rev Respir Dis 1975;111(04):497–537

104 Persson EK, Verstraete K, Heyndrickx I, et al. Protein crystallization promotes type 2 immunity and is reversible by antibody treatment. Science 2019;364(6442):eaaw4295
105 Fahy JV, Locksley RM. Making asthma crystal clear. N Engl J Med 2019;381(09):882–884
106 Gevaert E, Delemarre T, De Volder J, et al. Charcot-Leyden crystals promote neutrophilic inflammation in patients with nasal polyposis. J Allergy Clin Immunol 2020;145(01):427–430.e4
107 Kousha M, Tadi R, Soubani AO. Pulmonary aspergillosis: a clinical review. Eur Respir Rev 2011;20(121):156–174
108 Raghu G, Remy-Jardin M, Ryerson CJ, et al. Diagnosis of hypersensitivity pneumonitis in adults. An Official ATS/JRS/ALAT Clinical Practice Guideline. Am J Respir Crit Care Med 2020; 202(03):e36–e69
109 Meeker DP, Gephardt GN, Cordasco EM Jr, Wiedemann HP. Hypersensitivity pneumonitis versus invasive pulmonary aspergillosis: two cases with unusual pathologic findings and review of the literature. Am Rev Respir Dis 1991;143(02):431–436
110 Gerfaud-Valentin M, Reboux G, Traclet J, Thivolet-Béjui F, Cordier JF, Cottin V. Occupational hypersensitivity pneumonitis in a baker: a new cause. Chest 2014;145(04):856–858
111 Reich JM. Chirping rales in bird-fancier's lung. Chest 1993;104 (01):326–327
112 Denning DW, Follansbee SE, Scolaro M, Norris S, Edelstein H, Stevens DA. Pulmonary aspergillosis in the acquired immunodeficiency syndrome. N Engl J Med 1991;324(10):654–662
113 Mistry H, Ajsivinac Soberanis HM, Kyyaly MA, et al. The clinical implications of *Aspergillus fumigatus* sensitization in difficult-to-treat asthma patients. J Allergy Clin Immunol Pract 2021;9 (12):4254–4267.e10
114 Selman M, Pardo A, King TE Jr. Hypersensitivity pneumonitis: insights in diagnosis and pathobiology. Am J Respir Crit Care Med 2012;186(04):314–324
115 Garg A, Bhalla AS, Naranje P, Vyas S, Garg M. Decoding the guidelines of invasive pulmonary aspergillosis in critical care setting: imaging perspective. Indian J Radiol Imaging 2023;33 (03):382–391
116 Greene R. The radiological spectrum of pulmonary aspergillosis. Med Mycol 2005;43(Suppl 1):S147–S154
117 Bercusson A, Jarvis G, Shah A. CF fungal disease in the age of CFTR Modulators. Mycopathologia 2021;186(05):655–664
118 Agarwal R. High attenuation mucoid impaction in allergic bronchopulmonary aspergillosis. World J Radiol 2010;2(01):41–43
119 Fenoglio CM, Reboux G, Sudre B, et al. Diagnostic value of serum precipitins to mould antigens in active hypersensitivity pneumonitis. Eur Respir J 2007;29(04):706–712