



# Gardner's Syndrome—A Case Report and Brief Literature

Mukul Shetty<sup>1</sup> Shrivya Saloni Mahaveeran<sup>2</sup> Arathi K.<sup>3</sup> Akhil Shetty<sup>4</sup>

<sup>1</sup>Department of Orthodontics and Dentofacial Orthopaedics, AB Shetty Memorial Institute of Dental Sciences, Nitte (Deemed to be) University, Mangaluru, Karnataka, India

<sup>2</sup>Department of Pediatric and Preventive Dentistry, Yenepoya Dental College, Yenepoya Deemed to be University, Mangaluru, Karnataka, India

<sup>3</sup>Department of Oral Pathology, AJ Institute of Dental Sciences, Mangaluru, Karnataka, India

Address for correspondence Shrivya Saloni Mahaveeran, MDS, Department of Pediatric and Preventive Dentistry, Yenepoya Dental College, Yenepoya Deemed to be University, Mangaluru 575018, Karnataka, India (e-mail: salonishrivya@gmail.com).

<sup>4</sup>Oral Pathologist, Private Dental Clinic, Mangalore, Karnataka, India

J Health Allied Sci<sup>NU</sup> 2024;14:570–574.

## Abstract

Gardner's syndrome has been recognized as a hereditary affliction that is autosomal in nature. This disorder is known to exhibit characteristics of familial adenomatous polyposis, of which it is also considered a variation. The features of this syndrome include the gradual development of osteomas and epidermoid cysts, including a characteristic feature that is the noted presence of intestinal polyps, which are generally multiple in number. Additionally, dental anomalies have been observed and recorded in a sizeable ratio of cases encompassing an increased frequency of multiple odontomas that are benign tumors linked to the development of a tooth and tooth agenesis/hypodontia that refers to developmental absence of one or more teeth. The other dental ascertainment includes abnormal morphology of the tooth/teeth as well as the presence of supernumerary teeth and impacted or unerupted teeth. This case report outlines the case of a 59-year-old male patient who had reported to the clinic, and was then diagnosed with Gardner's syndrome post a thorough examination.

## Keywords

- ▶ Gardner's syndrome
- ▶ osteoma
- ▶ odontoma
- ▶ sebaceous cyst

On radiographic examination, the manifestation of multiple osteomas in the frontal bone was revealed. The presence of a motley of diffused benign lesions of the bone in both the upper and lower jaw as well as the presence of an epidermoid cyst on the scalp was suggestive of an exemplar presentation of Gardner's syndrome.

## Introduction

Gardner's syndrome (GS) was first described by Gardner and Richard in the year 1951. The term GS does not cognominate a unique disease, but rather it remains a histologically oriented testimonial to Dr. Eldon Gardner.<sup>1</sup> The alternative synonyms of GS include familial polyposis of the colon or colorectal polyposis. It has also been referred to as familial adenomatous polyposis or abbreviated FAP. An alteration in the specific adenomatous polyposis coli gene is known and widely accepted to be responsible for GS. It is

commonly alluded to as the APC gene.<sup>2</sup> The particular chromosome responsible for the anomaly has been noted to be involving the bands 5q21 and q22. These chromosomes are located within the gene in concern at the moment, which is the APC gene.<sup>3</sup> The proteins within the genes are responsible in modulating and regulation of the growth of the cells in the body. The allayed activation or downregulation of the APC gene and the consequential latent activation of beta-catenin (a protein controlled by the APC gene) is observed that has been linked to cancerous growth of cells.

article published online  
December 1, 2023

DOI <https://doi.org/10.1055/s-0043-1777282>.  
ISSN 2582-4287.

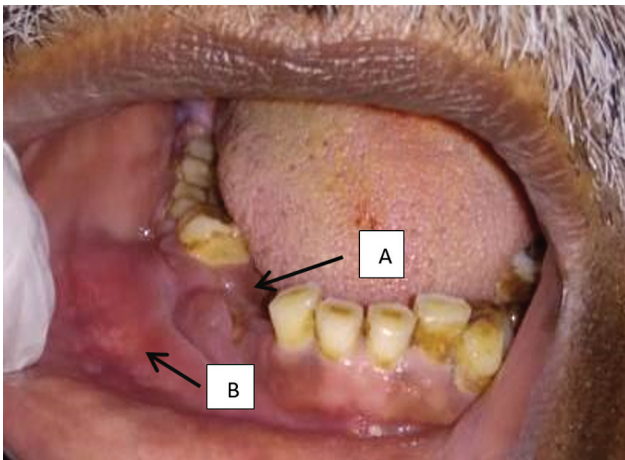
© 2023. The Author(s).

This is an open access article published by Thieme under the terms of the Creative Commons Attribution License, permitting unrestricted use, distribution, and reproduction so long as the original work is properly cited. (<https://creativecommons.org/licenses/by/4.0/>)  
Thieme Medical and Scientific Publishers Pvt. Ltd., A-12, 2nd Floor, Sector 2, Noida-201301 UP, India

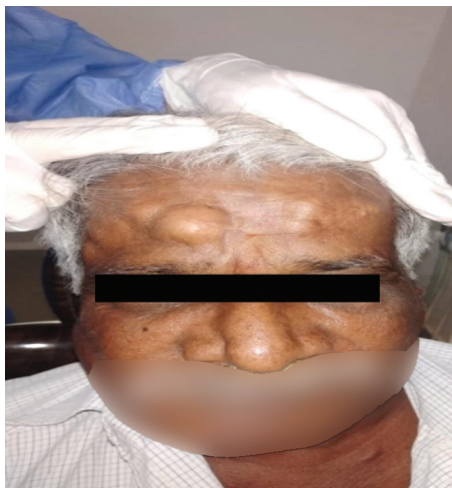## Case History

A male patient aged about 59 years old presented himself to our dental health center complaining of pain in the last 3 weeks in the lower right region of his jaw that was accompanied by a swelling. A thorough intraoral and extraoral examination was performed following which we observed the presence of grossly decayed, infected root stumps in relation to primary mandibular right canine (**► Fig. 1**).

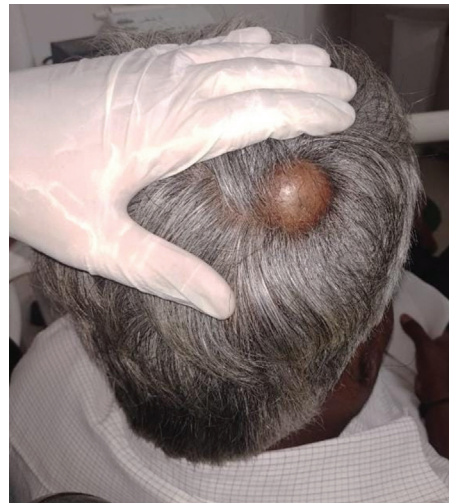On extraoral examination, we observed the presence of fixed nodular swellings on both the right and left side of the forehead. On the right side of the forehead, the nodular swellings averaged  $2.5 \times 2.5$  cm in size. Similarly on the left side of the forehead region, the fixed swellings averaged  $1 \times 1$  cm in measure (**► Fig. 2**). The overlying skin appeared typical with no effacing. These nodular swellings were non-tender on palpation and immovable, fixed to the underlying



**Fig. 1** Intraoral photograph showing (A) the presence of infected root stumps in relation to primary mandibular right canine. (B) The buccal mucosa adjacent to the infected tooth is turgid with partial obliteration.



**Fig. 2** On extraoral examination showing presence of nodular swellings on both the right and left region of the forehead.

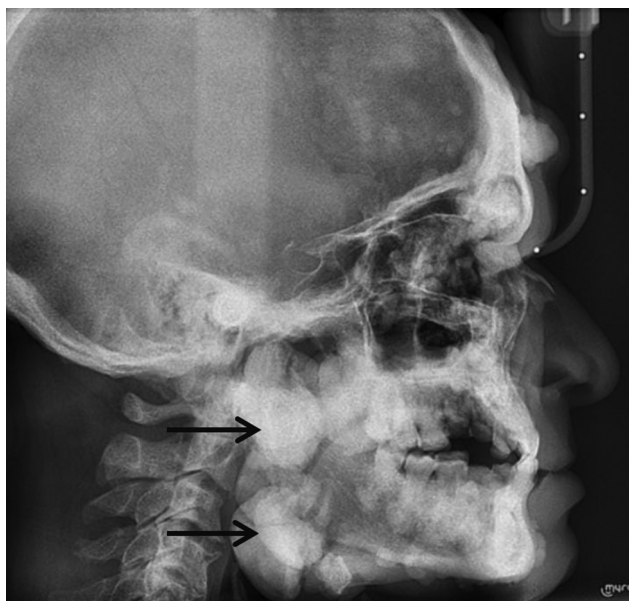


**Fig. 3** Presence of a well-circumscribed swelling on the scalp, soft on palpation that is suggestive of a sebaceous cyst.

bone. We also observed the presence of a sound swelling with finite borders that was located on the scalp. On tactual exploration, the swelling was yielding and soft to touch; to all appearances a sebaceous cyst measuring roughly about  $3.5 \times 3.5$  cm (**► Fig. 3**).

On further enquiry, the patient proffered information stating that the nodular swellings that were observable on both his forehead and scalp locale were present over the past 17 years. The initiation of the swellings started during his early teenage years that were diminutive in size initially, but gradually increased in dimension. The presence of these swellings did not hamper his day-to-day functioning since they were asymptomatic, nor was he concerned about aesthetics; hence, he did not sought treatment for the same. A thorough family history divulged the presence of similar findings among his immediate family members, which included his 32-year-old daughter, as well as his 10-year-old granddaughter. Both of them presented with similar nodular bony swellings.

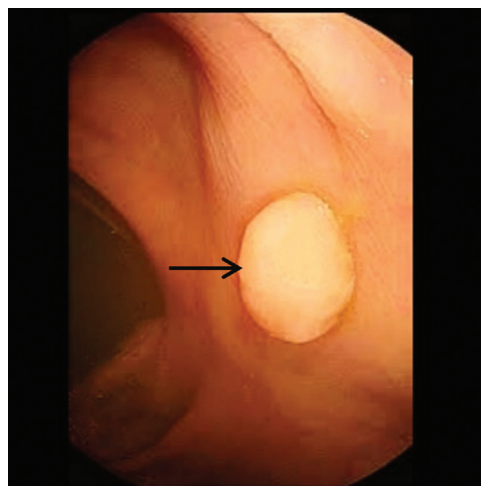
The patient was subjected to an orthopantomogram (OPG) and a lateral cephalogram where the radiographic findings revealed the presence of multiple growths of bone both in the maxilla and mandible. The panoramic radiograph showed numerous radio-opacities perceived in relation to the maxilla, mandible, frontal bone, frontal and ethmoidal sinuses that were suggestive of osteomas. The lateral cephalogram disclosed the appearance of osteomas that could be appreciated in the mandible, noticeably at the angle of the mandible and on the upper border of the ramus (**► Fig. 4**). We also discerned the manifestation of a motley of retained deciduous teeth in relation to teeth primary maxillary right first molar, primary maxillary right second molar, primary maxillary left canine, primary mandibular left canine, primary mandibular left first molar, and primary mandibular left second molar. Several impacted teeth in relation to permanent maxillary right first premolar, permanent maxillary left canine, permanent maxillary left first premolar, permanent mandibular left canine, permanent mandibular



**Fig. 4** Lateral cephalogram showing the presence of osteomas appreciable on the angle of mandible and upper border of the ramus.

right canine, and permanent mandibular right first premolar were also observed (→ **Fig. 5**).

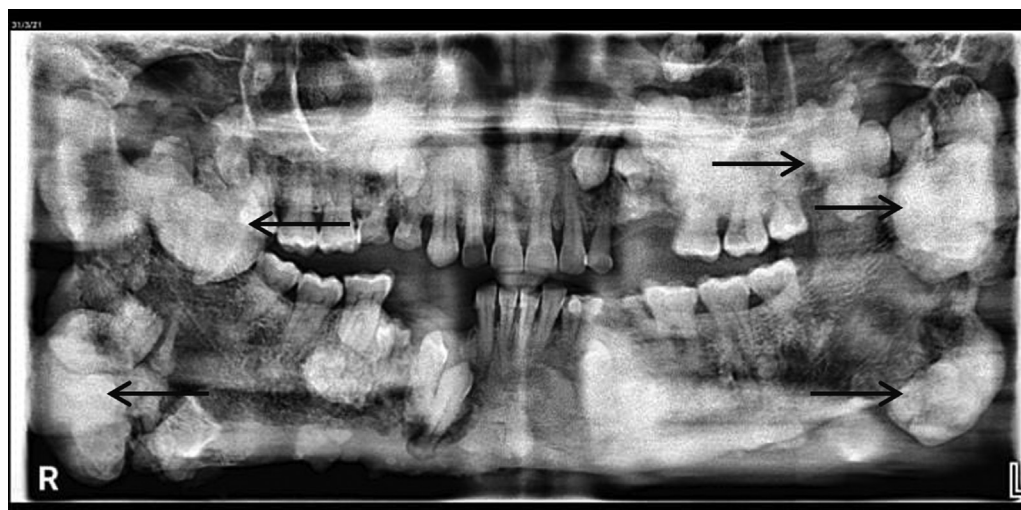The buccal mucosa on the lower right side adjacent to the region of the infected primary mandibular right canine root stumps and impacted permanent right mandibular canine and permanent right mandibular first premolar was found to be distended and turgid with partial obliteration. Broadly, the free and attached gingiva extending from the distal aspect of the permanent mandibular right lateral incisor up to the mesial most region of right side of the permanent mandibular right third molar was enlarged. The mucosa overlying the gingiva was found to be intact with pus exudate observable in the region of permanent mandibular right canine and permanent mandibular right first premolar.



**Fig. 6** The colonoscopy procedure revealed the presence of a sessile intestinal polyp in the colon that was excised and sent for biopsy.

Concerning the primary affliction of the patient, extraction was performed on the infected root stumps in relation to primary mandibular left canine. Post the surgical extraction of the impacted root stumps, the patient was subjected to an antibiotic coverage, following which adequate healing of the extraction wound was observed when recalled after a week.

We advised the patient to consult a gastroenterologist and undergo a colonoscopy procedure to detect the presence of intestinal polyps. The presence of intestinal polyps is one of the prime distinguishing features of GS and its presence ascertains a 100% risk of malignancy if left untreated. The colonoscopy procedure revealed the presence of a sessile intestinal polyp in the colon that was excised and sent for biopsy (→ **Fig. 6**). Sessile polyps are growths that could be flat or sometimes dome shaped and originate from the mucosal lining. These outgrowths are regarded precancerous. The biopsy specimen divulged the presence of typical mucosal lining of the colon. Another notable feature was sparse



**Fig. 5** Orthopantomography showing the presence of numerous radio-opacities in the maxilla, mandible, frontal bone, ethmoidal and frontal sinuses.

interspersing of relatively dense chronic inflammatory infiltrates within the sessile polyp. A collective inference was derived at, which was established following the thorough history, preclinical examination of the extraoral features, clinical examination of the intraoral features, radiographic investigations using the OPG and lateral cephalograms, a gastroenterologist consult, colonoscopy, and the histopathological diagnosis post-biopsy; all indicative that the patient had GS.

## Discussion

GS is rare and is generally acquired as an autosomal dominant disorder with a prevalence ranging between 1 in 4,000 and 1 in 12,000, depending on the region.<sup>4,5</sup> It has been noted that an alteration in the chromosome involving the bands 5q21 and q22 is responsible for GS. The deviant changes in the APC gene are culpable for this syndrome.<sup>3,4</sup>

A myriad of features including polyposis of the intestine/intestinal polyps, bony hard swellings, that is, osteomas, numerous anomalies of the dentition, and benign epidermoid cysts are observable.<sup>4</sup>

Bone abnormalities like osteomas are observed in skull, mandible and long bones. Osteomas are typically benign and also referred to as homoplastic osteomas. Their origin could either stem from compact bone or medullary bone. Depending on their location from where it originates, they are further classified into peripheral or central.<sup>6</sup> In some individuals, osteomas have a tendency to be mistaken for enostosis of bone that resemble small bony islands growing within another bone, especially if it originates from the medulla.<sup>7</sup>

According to study by Chimenos-Küstner et al,<sup>7</sup> osteomas were observed predominantly in the maxilla, as well as other locations that were three or more in number in about half the segment of the patients. This was concurrent with a similar observation made after a study performed by Ida et al which stated that we can distinguish the presence or absence of GS in an individual suspected to have the syndrome based on the conclusive presence of three or more osteomas.<sup>8</sup> The present case also showed the presence of osteomas in the mandible at the angle of the mandible and on the upper border of the ramus.

Another distinguishing and conclusive feature of GS is the presence of intestinal polyps. These polyps have a tendency to turn malignant if left unchecked and untreated. They are usually perceived during the early adolescence stage and can range in number, presenting either as a solitary polyp or numerous polyps all over the gastrointestinal tract or colon. Bony outgrowths or osteomas generally progress first in children in opposition to the development of colonic polyposis. The presence of these polyps is usually accompanied by ailments in regard to the colon including but not limited to episodes of diarrhea, abdominal cramps, and discharge from the colon which could include blood or mucosal discharge. As opposed to using the number of the osteomas present in the individual as a positive identity of this syndrome, a study by Herrmann et al stated that only positive detection of the

presence of polyps in the intestine could prove to be a confirmation of GS.<sup>9</sup> It was attested that these polyps had the proclivity for malignancy, which was documented to have a fatal eventuality if not diagnosed and treated in time.<sup>7,8</sup> In the present case, colonoscopy procedure revealed the presence of a sessile intestinal polyp in the colon that was excised and sent for biopsy.

Other attributes to this syndrome included the presence of calcified tissues called compound odontomas that are tumors bearing semblance to a tooth/teeth along with the presence of hypercementosis, a condition characterized by deposition of cementum along the root causing a misshapen appearance of the affected root/tooth.<sup>8</sup> Seventy percent of the patients with GS exhibit a multitude of orofacial aberrations. These include the presence of impacted or unerupted teeth, teeth missing due to congenital reasons, and hyperdontia or parateeth with multiple surface caries. Additionally, nontypical tooth morphology such as occurrence of fused molar roots, long drawn out conoid roots of molars, dentigerous cyst around unerupted teeth are noted.<sup>5,10</sup> The present case not only also showed classical dental findings in relation to retained deciduous teeth but also the presence of impacted permanent teeth.

Apart from the hard tissue findings involving the bone and teeth, lesions originating from the soft tissues have also been observed in some cases. This includes tumors of fibrous origin known as fibromas, tumors arising from within the nerves adeptly referred to as neurofibromas, and benign tumors arising in the uterus that are referred to as leiomyomas. Other noteworthy aberrations of soft tissue origin that were reported were cancers involving skin and muscles like lipoma and also benign growths involving the skin manifesting as sebaceous cysts.<sup>11</sup>

Radiologic examination of the mandible has proven to be a simple, noninvasive technique in order to detect the presence of bony lesions and in turn help in identifying young carriers of this syndrome. In this case, we noted the presence of multiple diffuse radiopacities that were visible in the OPG. The affected regions included both the maxillary and the mandibular jaws, in addition to the frontal bones. Radiopacities were also noticeably visible involving the frontal as well as the ethmoidal sinus regions on the OPG that are denotative of osteomas.

GS is often suspected and detected first by the dental healthcare provider as many dental clinical features associated with this syndrome such as odontoma, osteoma, supernumerary, and impacted teeth, which can be detected in the panoramic radiographs. These intraoral features appear years before the appearance of intestinal polyposis. Dental professionals should be knowledgeable about the significance of the syndrome as a precancerous condition

The management and ministrations of these individuals affected by GS are wholly symptomatic. Dental management includes extraction of the impacted teeth, cysts of the jaw or face, as well as resection of osteomas for cosmetic or functional reasons. Tooth extraction can be difficult because of complete absence of periodontal space caused by hypercementosis and generalized increased alveolar bone density.

Osteomas are known to have no absolute malignant potential; therefore, they are only removed on the basis of whether the lesion has turned symptomatic; or secondly, if the patient cites cosmetic reasons.

## Conclusion

GS has been recognized as a hereditary affliction that is autosomal in nature. It is known to afflict the various systems of the body, usually commencing as early as the adolescent phase or even the second decade of life. The characteristic feature of this syndrome are presence of multiple intestinal polyps. The classic triad of GS is said to enfold the presence of osteomas notably involving both the maxilla and the mandible; polyps in the intestine and the occurrence of slow growing epidermoid cysts. Additionally, dental anomalies have been observed and recorded in a sizeable ratio of cases encompassing an increased frequency of multiple odontomas that are benign tumors linked to the development of a tooth and tooth agenesis/hypodontia that refers to developmental absence of one or more teeth. It is imperative that if distinct features of the syndrome are identified, they should be attended promptly as there is an extreme probability that the lesions can transmute to malignancy over time. Dental healthcare personnel often times have the potential to be the first to suspect and detect this syndrome as many dental clinical features are associated with GS. The patient should then be guided through the various investigations required and steered towards the remedy/therapy regimen.<sup>12</sup>

It is imperative to differentiate sclerotic lesions (which are nonspecific in nature) in the mandible in distinction to true osteomas (found on the cranial bone of intramembranous ossification). Osteomas are speculated to have congenital, inflammatory, or traumatic factors responsible for their development. Mandibular osteomas in GS gravitate in multiple numbers, whereas in comparison, nonspecific sclerotic bony lesions are generally isolated in number and ascertained in close proximity to the tooth of interest.

The medical prognosis of an individual affected with GS is diversified wherein if timely treatment is not rendered, there is a high probability of the individual developing cancer of the colon. Early detection of the presence of pulp polyps in the colon is crucial due to the tendency of the polyps to almost always progress to malignancy gradually in due course of time.<sup>13</sup> Observation and frequent scrutiny are advocated in these individuals that include annual physical inspections, thyroid function evaluations, screening of the colon periodically, and the administration of pain-relieving medication if symptomatic symptoms arise.

### Declaration of Patient Consent

The authors certify that they have obtained all appropriate patient consent forms. The patient has given his

consent for his images and other clinical information to be reported in the journal. The patient has been informed that his name and initials will not be published and due efforts will be made to conceal the identity, but anonymity cannot be guaranteed.

### Financial Support and Sponsorship

None.

### Conflict of Interest

None declared.

### Acknowledgement

All authors have made substantive contribution to this manuscript and all have reviewed the final paper prior to its submission.

## References

- Gardner EJ, Richards RC. Multiple cutaneous and subcutaneous lesions occurring simultaneously with hereditary polyposis and osteomatosis. *Am J Hum Genet* 1953;5(02):139–147
- Wijn MA, Keller JJ, Giardiello FM, Brand HS. Oral and maxillofacial manifestations of familial adenomatous polyposis. *Oral Dis* 2007; 13(04):360–365
- Buch B, Noffke C, de Kock S. Gardner's syndrome—the importance of early diagnosis: a case report and a review. *SADJ* 2001;56(05): 242–245
- Dolan KD, Seibert J, Seibert RW. Gardner's syndrome. A model for correlative radiology. *Am J Roentgenol Radium Ther Nucl Med* 1973;119(02):359–364
- Madani M, Madani F. Gardner's syndrome presenting with dental complaints. *Arch Iran Med* 2007;10(04):535–539
- Herford AS, Stoffella E, Tandon R. Osteomas involving the facial skeleton: a report of 2 cases and review of the literature. *Oral Surg Oral Med Oral Pathol Oral Radiol* 2013;115(02):e1–e6
- Chimenos-Küstner E, Pascual M, Blanco I, Finestres F. Hereditary familial polyposis and Gardner's syndrome: contribution of the odonto-stomatology examination in its diagnosis and a case description. *Med Oral Patol Oral Cir Bucal* 2005;10(05): 402–409
- Ida M, Nakamura T, Utsunomiya J. Osteomatous changes and tooth abnormalities found in the jaw of patients with adenomatosis coli. *Oral Surg Oral Med Oral Pathol* 1981;52(01):2–11
- Herrmann SM, Adler YD, Schmidt-Petersen K, et al. The concomitant occurrence of multiple epidermal cysts, osteomas and thyroid gland nodules is not diagnostic for Gardner syndrome in the absence of intestinal polyposis: a clinical and genetic report. *Br J Dermatol* 2003;149(04):877–883
- Butler J, Healy C, Toner M, Flint S. Gardner syndrome – review and report of a case. *Oral Oncology Extra*. 2005;41:89–92
- Small IA, Shandler H, Husain M, David H. Gardner's syndrome with an unusual fibro-osseous lesion of the mandible. *Oral Surg Oral Med Oral Pathol* 1980;49(06):477–486
- Verma P, Surya V, Kadam S, Umarji HR. Classical presentation of Gardner's syndrome in an Indian patient: a case report. *Contemp Clin Dent* 2016;7(02):277–280
- Basaran G, Erkan M. One of the rarest syndromes in dentistry: Gardner syndrome. *Eur J Dent* 2008;2(03):208–212