

The Delto-acromial Flap in Reconstruction of the Face & Neck

C. J. T. Pinto * K. S. Goleria † C. V. Mehendale ‡

Department of Plastic Surgery, K. E. M. Hospital and Seth G. S. Medical College, Parel, Bombay-12.

A WIDE choice of methods is available in the reconstruction of skin and soft tissue defects of the face and neck. In superficial defects of the face, split or full thickness grafts are extensively used and are eminently suitable in some situations, such as in the eyelids. When large superficial areas in the face and neck are to be repaired free grafts are unpredictable in their colour match and have an annoying tendency to contract and may need replacement by flap skin.

In defects of contour and when cover and lining (e.g. following cancer cheek excisions) has to be provided, it becomes necessary to provide a flap brought from a distance.

It has been our experience that skin flaps brought from an area below the nipple line tends to be darker than the surrounding skin when brought up to the face. For a period of time we used an acromiopectoral tubed pedicle to meet the demands of both surface and contour reconstructions in the face and neck. The acromiopectoral tubed pedicle, while providing excellent repairs in terms of texture and colour, has its disadvantages since it involves a number of operative manoeuvres and prolonged

hospitalization.

We have laid down a few criteria for a good reconstruction :

(1) The colour match should be predictable and merge with surrounding skin.

(2) The method of reconstruction should be applicable to a wide range of circumstances and permit correction of both surface and contour defects.

(3) The time spent in reconstruction should be reduced so as to involve a minimum period of hospitalization.

(4) The patient should be free of cumbersome methods of immobilization during and after reconstruction.

The delto-acromial flap used by us in reconstruction fulfills all these conditions. This flap was described by Kazanjian and Converse (1949) but was not used extensively enough. Kirschbaum (1958) described its use in mentosternal contractures following burns

We have used a similar flap to reconstruct lesions needing both surface areas and contours in the face and neck and also to provide lining and cover in lesions around the cheek.

The flap has been used in twenty cases, sixteen of these needed a flap from one

* Honorary Professor and Honorary Plastic Surgeon

† Honorary Asstt. Professor and Honorary Asstt. Plastic Surgeon

‡ Honorary Asstt. Professor and Honorary Asstt. Plastic Surgeon

shoulder and in the remaining four, both the delto-acromial regions provided the cover for an area of about six inches in width. This flap was used in the repair of a varied group of conditions.

Table I

(1) Mentosternal contracture —	
(a) Single flap	... 9 cases
(b) Bilateral flap	... 4 cases
(2) Repair of pharyngostomy	... 1 case
(3) Repair of carcinoma cheek defects	... 4 cases
(4) Haemangioma cheek	... 1 case
(5) Nose reconstruction	... 1 case

The Design of the Flap and Technical details:—A rectangular area is outlined on the outer side of the shoulder. Two parallel incisions are made in the delto-acromial region and joined at the lower part which extends upto the insertion of the deltoid. The skin with the subcutaneous tissue is dissected from below upwards. The amount of fat in this region is not as great as other regions so that the flap is thin enough to cover a skin contracture and yet thick enough to permit contour reconstructions in the face. The flap is raised to just beyond the acromial region and in actual fact has a wide base along the anterior border of the Trapezius. The flap is easily raised except over the upper part of the deltoid where the skin tends to be adherent to the deeper tissue. The width of the flap varies between 3-4 inches and is approximately 9 inches in length. The flap is not delayed and is swung through a right angle, when it is required in the neck, and about 160° when it has to be moved into the face (Fig. 1 b).

The delto-acromial flap does not obey the usual cannons of length to breadth ratio, and has much in common with the median

forehead flap. The reason for this is the extreme vascularity so well seen at the base during its elevation. The main vascular leashes come from the posterior triangle of the neck and emerge in to the base of the flap. Care must be taken during dissection at this point to prevent damage to the blood supply.

On raising the flap, it is inset in to the defect. This can be made to reach up to the opposite side in the neck and any part of the face on the same side.

If the whole neck needs to be covered, two flaps from both shoulders can be employed but an interval of 3-6 weeks should elapse. The donor area is grafted with a free split graft.

A dog ear at the base becomes obvious when the flap is set in. This is easily rectified at the time of returning the unused portion to the shoulder. The average time between the inset and the return of the flap is 3-4 weeks.

Post-operative care. It is necessary to see that no kinks occur in the post-operative period. Minor adjustments in position either by flexing the neck or slightly extending it straighten any kinks which may endanger the viability of the flap. The immobilization required is simple in the case of a flap to the face, no immobilization is needed for neck reconstruction.

ILLUSTRATIVE CASES

(1) *Hæmangioma of the cheek involving the face and lower eyelid.*—The eyelid was reconstructed after excision with a post-auricular Wolfe graft and the lesion in the face was repaired by a delto-acromial flap (Fig. 1. a, b, c).

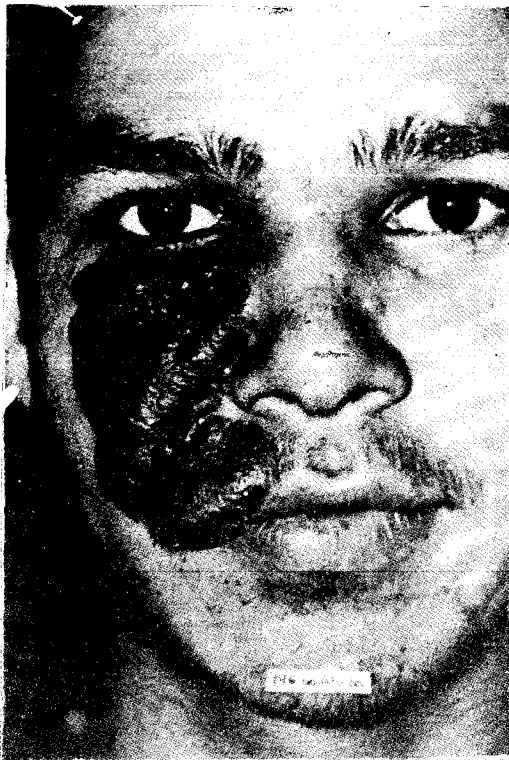

Fig. 1 (a) Haemangioma of the cheek.

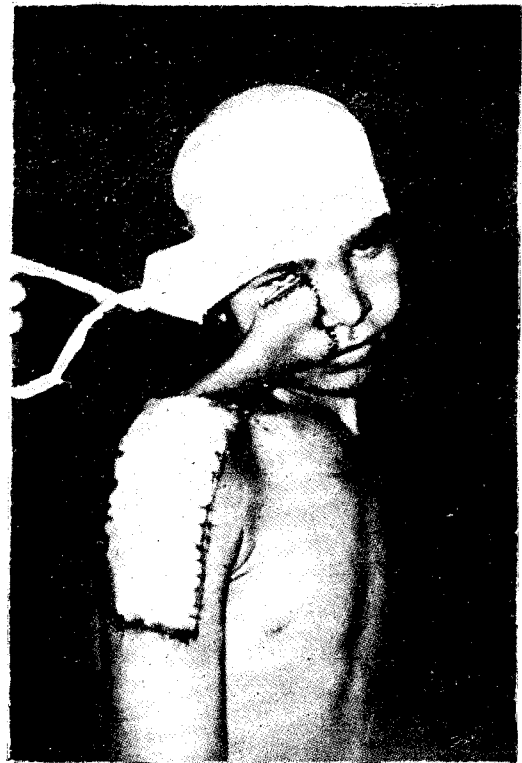


Fig. 1 (b) Delto-acromial flap in position with the donor area grafted with a split graft. Note the simple method of immobilization, using a bandage round the head with a loop which should go round under the armpit.

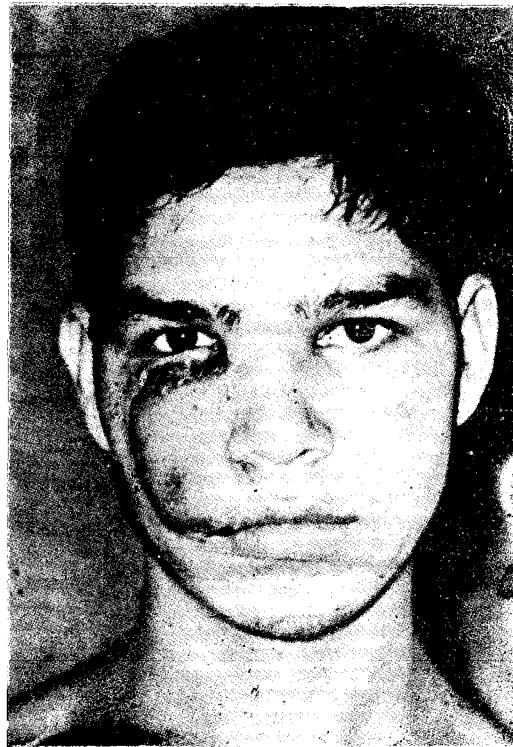

Fig. 1 (c) Post-operative result.

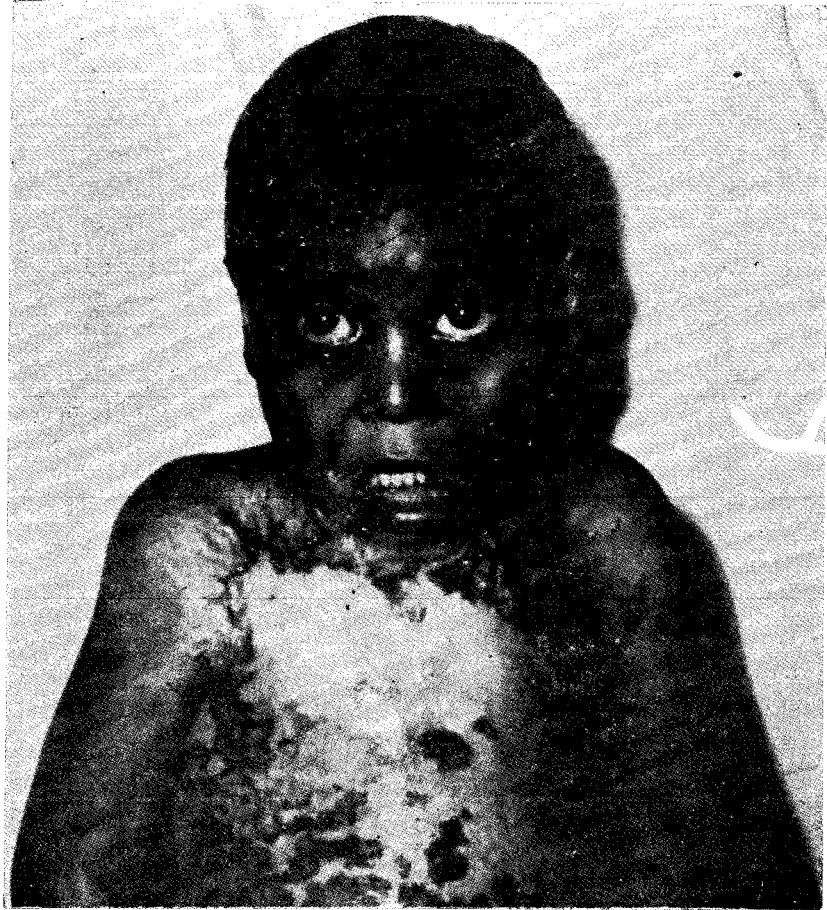

Fig. 2 (a) Severe mentosternal contracture in a young boy.

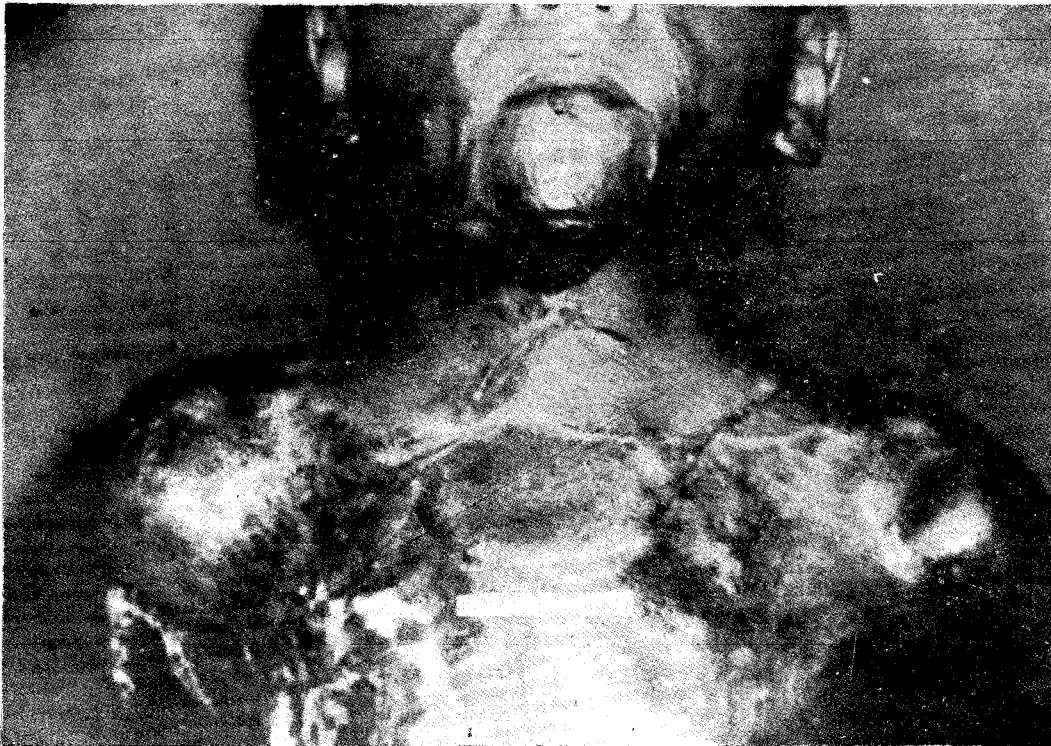

Fig. 2 (b)
Post-operative
result following
the use of 2
flaps to the
neck.

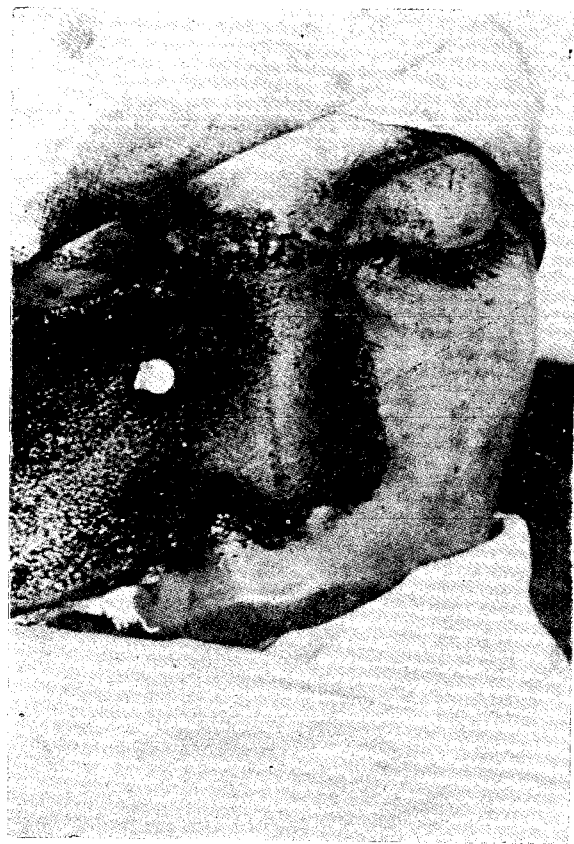
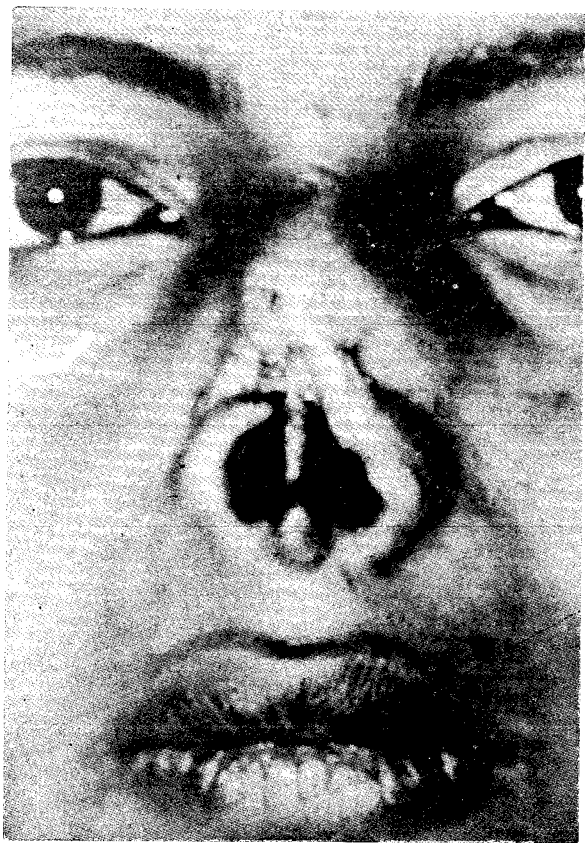
Fig. 3 (a). (b) The repair of a cut nose.

(2) *Repair of a pharyngostomy.* A case of malignancy of the pharynx and larynx in which a pharyngo-laryngectomy was done. The pharyngostomy opening was closed using a local flap for lining and a delto-acromial flap for cover.

(3) *Mentosternal contractures.* Single flaps have been used in few cases with gratifying results. When the neck contracture needed cover from the chin to the suprasternal notch, two flaps were used (Fig. 2a, b).

(4) *A case illustrating the results of a free graft to the neck resulting in a poor colour match and contracture.* It was decided to cover the area with an abdominal flap. The colour match obtained was darker than the rest of the face. The remaining area was covered with a delto-acromial flap. The abdominal flap was used before we started using the delto-acromial flap.

(5) *Malignancy of the cheek.* Following excision of a squamous cell carcinoma of the cheek, the delto-acromial flap provided both cover and lining in all our cases. The flap has on one occasion been folded on itself to provide the repair

(6) *This flap was used unsuccessfully in marking a nose.* In an ambitious attempt to obtain a bridge-line a piece of silicone was used between the lining which was obtained from local tissue and the delto-acromial flap to make the nose (Fig. 3 a, b). The colour

was good for 48 hours at the end of which the area beyond the level of the silicone insert was lost and the flap had to be returned.

We feel sure, however, that a whole nose could be made from this flap without putting a strut for the bridge line as this could easily be inserted at a later date.

CONCLUSION

The delto-acromial flap is an extremely versatile and useful flap in reconstructing lesion in the face and neck.

The quality of the end results is both aesthetically and functionally gratifying. The method of reconstruction is simple, requires no special method of immobilization and fixation and is applicable both to surface and contour. The reconstructions are completed during an average of five weeks hospitalization. The defect created in the shoulder does not interfere with movements and is accepted by all patients as a small price to pay for the excellence of the reconstruction.

REFERENCES

- Kazanjan, V.H. and Converse, J.M. : The Surgical treatment of facial injuries. The William and Wilkins Co., Baltimore, 1949.
- Kirschbaum, S. : Plastic & Reconstr. Surg. 21 : 131, 1958.