

Cleft Palate Management—A Review—Part II

R. N. Sharma, M.S., F.R.C.S.

Prof. of Plastic Surgery, K. G. Medical College, Lucknow.

III. Routine Post Operative Orthodontic Treatment

The Deformities

THE object of the orthodontic treatment was to correct the dental arch and occlusion. The growth of the arch depends upon exogenous and endogenous factors. To this early surgical trauma may result in retarded maxillary growth or even retroposition Hoffens Villagran. Relative mandibular psuedopognathism and a crossbite of canine, premolar or even molar regions may result. There is crowding of permanent teeth because of lack of space. Graber also in 1950 reiterated the fact that early surgery interferes with the blood supply thus directly aggravating the deformity. Oskar Herfert in 1963 experimentally proved that the ligation of the posterior palatine artery definitely disturbs the growth pattern of the maxilla, but simply raising of the mucoperiosteal flap does not do so. However in 1960 Foster suggested that the factors responsible for the deformity are the agenitic variations in the size of the Jaws, extent of the original deformity, and lastly agenesis intrinsically associated with the cleft palate deformity. In the same year Greer Walker stated that 1/3rd are due to bad surgery and other 1/3rd are the prognathetic hazards of heritage, and the remaining 1/3rd are due to intrinsic

failure of maxillary growth. If these are the factors for maxillary deformities then why not close the palate early.

During the discussions with his dental colleagues Kilner impressed upon them that the deformities of occlusion could always be corrected by orthodontic treatment instituted from the time of eruption of the permanent teeth. And from the school going age minor secondary procedures could be carried out depending upon the analysis of results of speech therapy. This routine post surgical orthodontic treatment is most suitable between the ages of 8-10 years.

Author's Results

From the number of patients whose dental deformities and teeth regulations that our orthodontic colleagues have done so far, our results have not been bad so as to condemn the procedure of simple Wardill Kilner technique of repair that we followed irrespective of age for more than twelve years. They never advocated removal of the premaxilla and according to them howsoever small the premaxilla may be, it always helps in wearing and the retention of the plate (Fig. 9). In a solitary grown up child we did an osteotomy, in another a wedge resection and in the third one a very rudimentary premaxilla was excised.

The Aims

The orthodontic treatment aims at

Methods of Correction

expansion and three dimensional growth of of the entire maxilla. This may be symmetrical in all directions or asymmetrical. In asymmetrical cases the treatment is very difficult. Additional operative interference be required to compensate for the maxillary

preferred to correctly align the upper incisors which are often rotated, tilted, retruded or crowded and are not at one level. The course of the treatment is prolonged over a period of time. This needs multiple sittings and in many centres it was felt that the dental surgeons could not spare suffi-

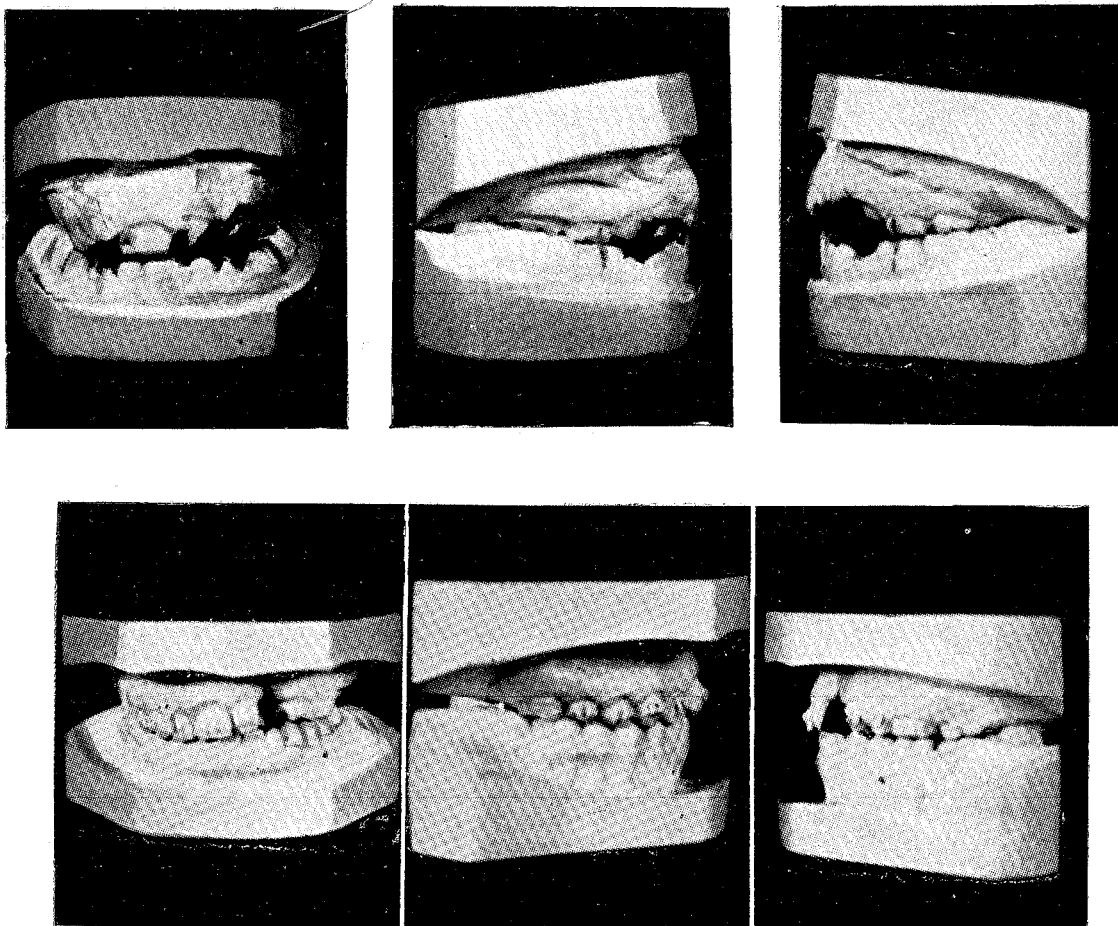


Fig. 9 B Showing post-operative dental models after orthodontic correction.

Drawbacks

hypoplasia by bone grafting. Brite reconstruction may also be needed by operative treatment where the orthodontic treatment fails. Two types of appliances are used for the orthodontic treatment, and they are removable or fixed (Fig. 10). The later is

cient time to do a thorough job. The scarring as a result of operation were further making the job difficult. Since the bony segments were unstable the patients had to wear retention plates all their lives unless bone grafting was done at this stage.

Possibility of Correction at early age

Attention was therefore drawn to the possibility of doing the orthodontic correction during the period of mixed dentition. Expansion can be brought about with the springs or else the springs are fixed to the cap splints. Burian and Herfert advocated the repair of the soft palate first based on

fixed the need of this treatment in various stages. For instance Dr. Hausser has described that presurgical orthodontic treatment is needed to create favourable conditions for surgery and primary bone grafting. Post surgical orthodontic correction is required to achieve orthodontic normalcy of position and occlusion. The choice of

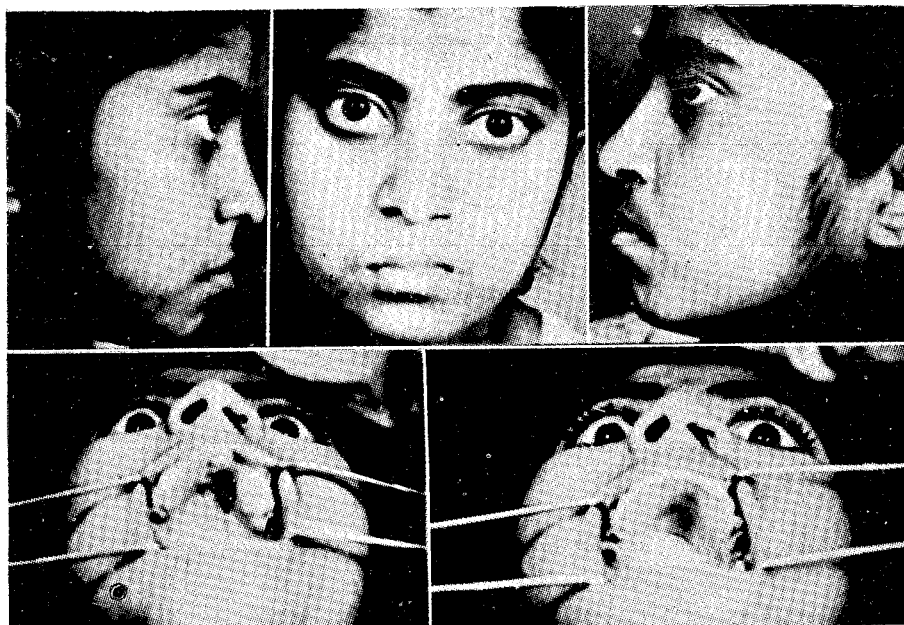


Fig. 9 C The photographs of the same patient at 12 years of age.

Schweckendick procedure in the complete type of clefts. This had the effect of reducing the gap in the hard palate. That is why the modern tendency is to first repair the lip and the soft palate and delay the hard palate repair upto 3 to 4 years of age. Children could cover the hard palate defect with retention plates but unless such plates are well fitting they may have bad effect on speech.

IV. Advances and the Need of Presurgical Orthodontic Treatment.

The advances in this work have classi-

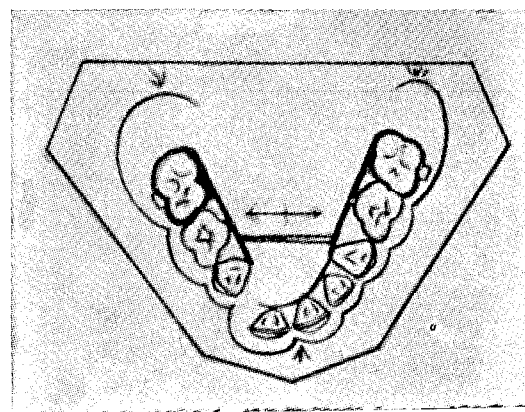


Fig. 10 Fixed type of appliance

Staging

various techniques employed is entirely individualised.

The object and treatment:

Presurgical orthodontic treatment has two objectives. For the repositioning of the badly protruding premaxilla elastic band traction is used or else along with the elastic bands dental plate is utilised which is fixed by occipital anchorage (Fig. 11). The other purpose is to obtain expansion for which McNeil advocates a dental expansion plate that has been modified by our orthodontists to bring about expansion of the maxilla and to help in surgical closure whenever primary bone grafting is done with the repair of

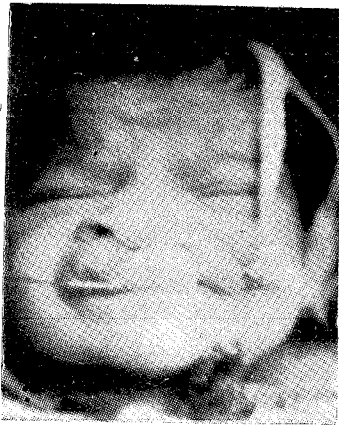

Fig. 11 Showing fixation of modified McNeil plate. the lip. Haupt and Stellmach are of the view that the treatment with the expansion plate should continue even after operation. Where forced expansion is indicated the expansion screw is soldered to the metal cap splints. The objects of all this continued treatment are to narrow the margins, diminish the gap, prevent the tongue from lying in the cleft and thus permit downward growth of the lateral segments

rather than flaring. It also expands the maxilla by moving the malpositioned and rotated alveolar segments buccally.

The Advances

In keeping with these factors greater stress is being laid on the presurgical ortho-

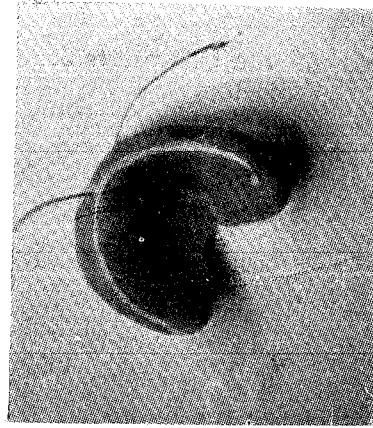


Fig. 12 Modified McNeil plate as used by our orthodontist.

dontic treatment at an early age. It is heartening to know that the infants with special plates (Fig. 12) in their mouth soon learn to suckle the mother's breast or the rubber teat of the milk bottle thus making the problem of feeding easier. The only objection to all this presurgical treatment as we have discussed earlier also, is the continued use of the retention appliances.

V. Orthodontic and/or Orthopaedic Treatment

The Bony Deficiency

This orthodontic treatment now seems to be either being cut short or done away with the orthopaedic correction. Schuchardt has laid great stress on the deficient bony component thus advocating bone grafting procedures in order to avoid the dental deformities. Longacre in 1966 has again stressed the hypoplasia and defi-

ciency of bone that need additional bone grafting.

Type of Grafts

From as early as 1954 bone grafting has been practised as a primary procedure by German Surgeons. Backdahal and Nordin (1961), and Schuchardt (1962) advo-

commended pre and post operative orthodontic correction in one form or another. But now Schuchardt's school is emphatic that even in the uni or bilateral cases if an autogenous rib graft which is split at its two ends and snugly fitted in the alveolar gap, there is no need for pre and post sur-

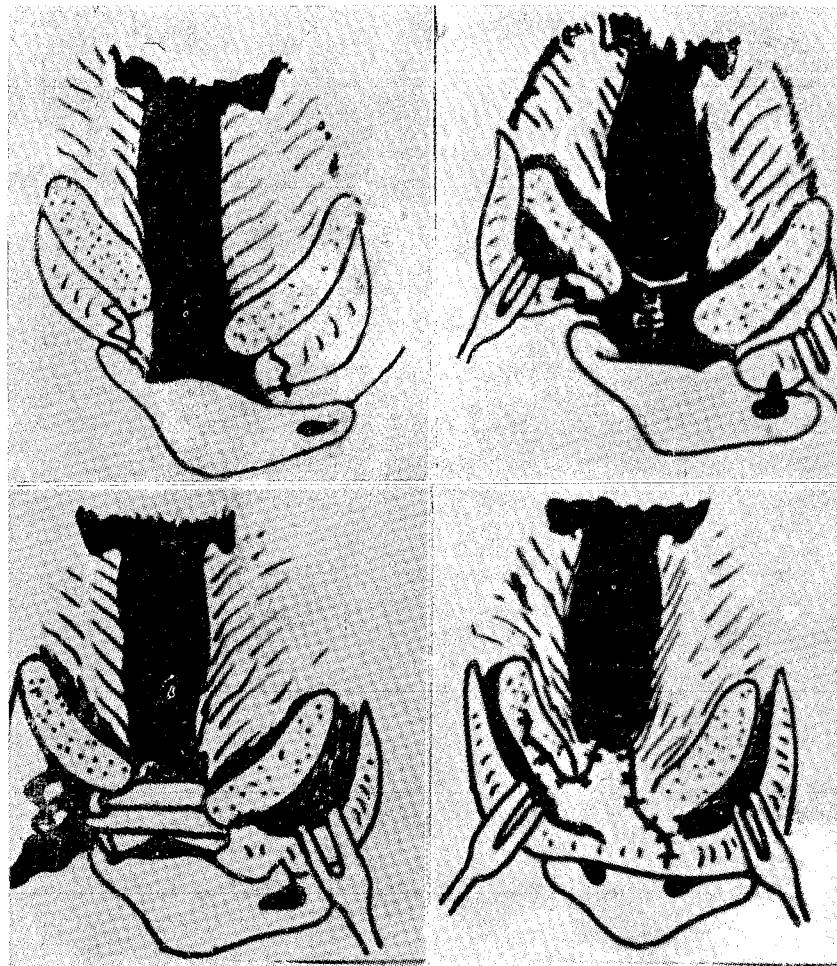


Fig. 13 Primary Rib graft according to Schuchardt's technique.

cated bone grafting. Schuchardt uses an autogenous rib, Schmid inserts a cancellous bone along with a piece of cartilage taken from the iliac crest and Reheman also advocates bone grafting between the ages of 6 months to a year. They all re-

commend pre and post operative orthodontic treatment at all. They argue that the musculature of the lip moulds the premaxilla into its correct position. The bone elsewhere in the body is not static and the stresses and strains of the bite and occlusion themselves are capable of

correcting the occlusive deformities. If this could be proved to be true then it will be a great advance indeed (Fig. 13).

The Doubts in Early Bone Grafting.

Johanson and Ohlson from Gothenburg have given up their cancellous bone grafting from the tibia of the patient as a primary procedure. They now firmly believe that in cases with marked occlusal deformities primary bone graft is wrong. Further those permanent teeth that get damaged will never migrate. And it is so easy to damage them in the primary bone grafting procedures at a tender age. If an X ray is taken and if the root canal of a tooth communicates with the sac that tooth will not migrate according to them. But they are convinced of the utility of the grafting as a secondary procedure upon completion of the orthodontic treatment.

buccal sulcus. A flap of mucoperiosteum is released and advanced to cover the pocket so formed for the bone graft that is filled with oxycel gauze. Later he convincingly demonstrated that the gap in the alveolus and the pocket filled with oxycel gauze is completely replaced and bridged by new bone formation, thus establishing a firm bony union of the arch.

Our Changed out look on Management

Over the last 2 years according to our changed technique, such patients who present to us within the first two years of life for repair, we deliberately form pockets utilising either Veau flap with or without combination of Campbell's procedure or the use of interpalatal flaps (Fig. 14). These pockets in one series are left unfilled, in the others we have put in homogenous rib graft while in the third group we insert

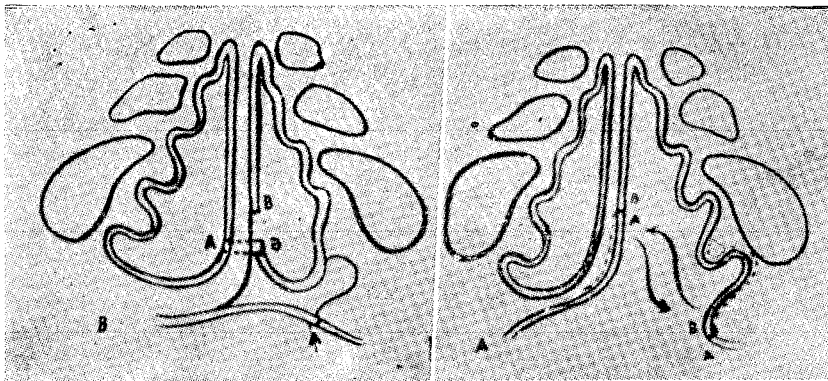


Fig 14 A method of forming pocket for bone graft.

The New Bone without Bone Graft

Skoog found that in certain instances when the mucoperiosteum is mobilised new bone formation occurs. At the time of primary repair of the lip and the anterior palate he mobilised the tissues from the

Below 2 Years :

gelfoam because the oxycel gauze is not available. None of these patients have received pre-surgical orthodontic treatment because our dental colleague feel short of hands to adopt this as routine procedure.

The repair of palate in these children is completed within 2 years by Wardill Kilner's procedure. Some or all of them will need routine post-operative orthodontic correction. And it is in these series we would like to do autogenous bone grafts whenever the orthodontic treatment is complete in them. This will not only do away with the need of support to the unstable bony segment by continuously using retention plate but it may also help in improving the profile in the relative prognathetic patient.

Above 2 years

Such children who come to us beyond the ages of 2 years or all those in whom lip has been repaired early and they come to us for repairs of the palate beyond that age

period, we repair the soft palate only (Fig. 15), utilising the same technique. But now we recommend Widmaier type of repair thus saving the posterior palatine artery. Above the age of 4 years in this group we advocate a routine pharyngoplasty with the primary repair of the soft palate. Whenever the lip component is left unoperated, we have the choice of doing the lip and the alveolar component first with autogenous bone graft. In these patients the hard palate defect is covered with a retention plate and when the orthodontic work is completed by the age 4—5 years, the repair of hard palate is then undertaken by any suitable procedure.

Sub mucus and Palatal Clefts

In this age group we are left with the

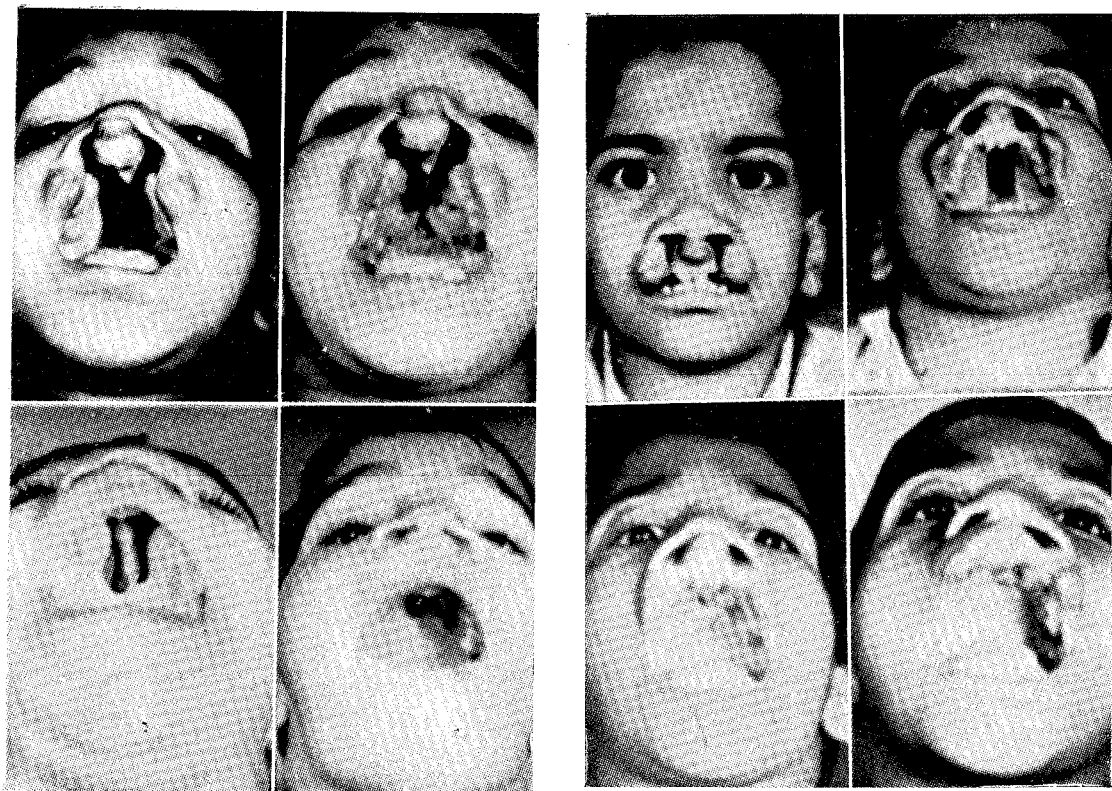


Fig. 15 A & B Showing repairs according to our changed technique. See text for explanation.

submucous clefts of the palate or only cleft of the palate. We recommend for them either a flap pharyngoplasty in order to reduce the space or an interposition of an island flap to obtain a definite push back. Here we advocate the use of black silk or nylon for repair of palatal layer, whereas in infants we still use chromic catgut.

V. Closure of Secondary Defects

Larger defects in the soft palate can be made up by the combination of pharyngeal flap and retromolar buccal flap as advocated by Skoog. (Fig. 16). For the residual defects situated anteriorly buccolabial flaps can be used in the defect of the alveolus

providing the tube pedicle of the skin either from the arm or the acromiopectoral region (Fig. 17) as advocated by Schweckendick. Johanson has advocated a long superiorly based pharyngeal flap through a lateral pharyngotomy incision. Such a flap when delivered out in the oral cavity is long enough to reach upto the region of the incisors even.

The literature is full with the controversies over the issue of timing the bone grafting procedures. Those interested in the detailed discussion on the subject of the treatment of patients, with cleft lip, alveolus and palate are requested to consult this

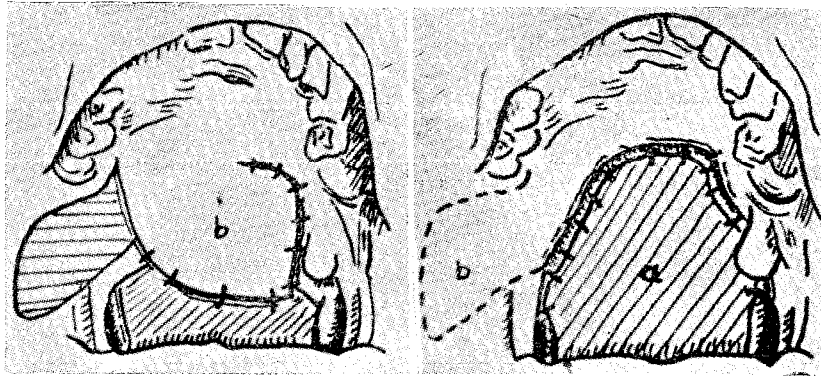


Fig. 16 A,B Showing Skoog's method of repair of large secondary defects

along with bone grafting procedures. A hinge flap is a simple procedure where the mucoperiosteal layer can be opened like the leaf of a book. Its edges are buried under the margins of the defect on the opposite side so that the mucoperosteum now forms a single layer floor of the nostril and the raw surface on the palatal side is allowed to heal by granulation tissue. The same can be made a two layer closure by taking a flap for cover from the tongue. Larger and complete defects can be covered by Gillies operation thus

publication which was the result of second Hamburg International Symposium held in July 1964 and later edited and published by Karl Schuchardt. It also deals with the indications techniques, contraindications of obturator prosthesis for the palatal clefts, and the E.N.T. aspects of corrective operations of the palate. This is out of scope of the present paper.

In conclusion we would like to stress that the results of cleft palate surgery have been steadily improving but the cleft lip an

palate has to be still regarded as a severe malformation. The management does not finish with the closure of the gap in the palate but the problem of the arch has to be tackled in many ways. The ability of the individual surgeon lies in assessing each case

procedures at the cost of the objectives laid down by Kilner.

My sincere thanks are due to our dental colleagues Drs. R. S. Nanda and D. S. Agarwal who have kindly lent their advice and

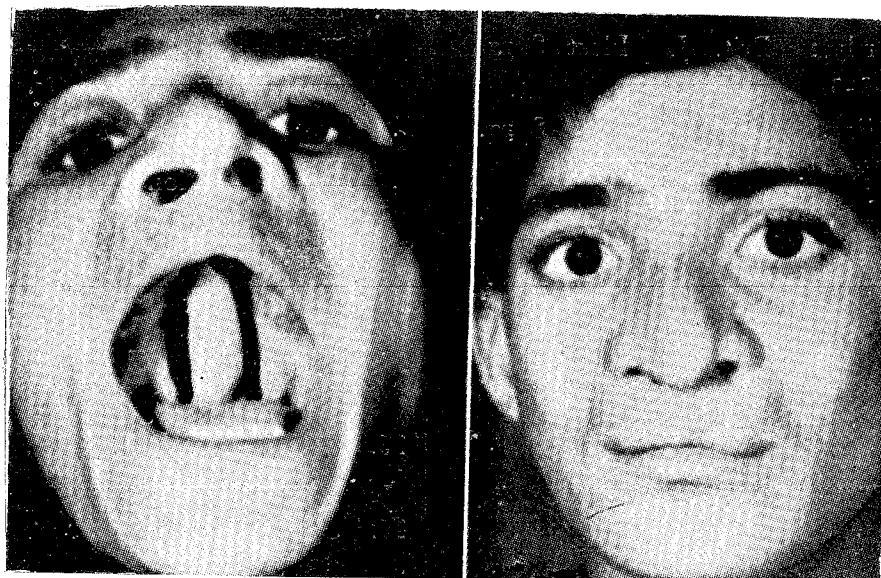


Fig. 17 Gillies Operation of Providing Pedicled Skin for very Large Defects

preoperatively for a correct approach with reasoning. Kilner always impressed that the ultimate object is that the patient should speak well, look well and eat well. And there is no justification in the present era to cut short or combine the operative

material for publication. To my colleague Dr. Ramesh Chandra and to my assistants Drs. M. H. Khan and S. N. Tandon I am grateful for their help. My typist O. P. Srivastava has done this job painstakingly and I am thankful to him also.

REFERENCES

1. Backdahl, M., Nordin, K.E. : Acta Chir. Scand. 122:130, 1961.
2. Braithwaite, F. : Cleft palate repair. Modern Trends in Plastic Surgery. 1:30, 1964.
3. Calnan, J. : Brit. J. Plast. Surg. 13:340, 1960-61.
4. Calnan, J. : Brit. J. Plast. Surg. 14:39, 1961.
5. Calnan, J. : Brit. J. Plast. Surg. 14:89, 1957-58.
6. Farina, M. : Brit. J. Plast. Surg. 14:89, 1957-58.

7. Foster Greene.: Brit. J. Plast. Surg. 12, 1959-60.
8. Greer Walker, D.: Transection of International Society of Plastic Surgery Page 4, 1960.
9. Graber, T.M.: J. Pediat, 37:400, 1950.
10. Herfert: Brit. J. Plast. Surg. 16:32, 1963.
11. Holdsworth : Brit. J. Plast. Surg. 16:144, 1963.
12. Kahn, Winstein: Brit. J. Plast. Surg. 13:13, 1960-61.
13. Lewin, M. L. : Plast. Reconstr. Surg. April, 1964.
14. McNeil, C. K. : Oral and facial deformity, 1954.
—Congenital oral deformity. Brit. Dent. J. 101:191, 1956.
15. Morley, M. E. : Cleft Palate, 1951.
16. Morley, M: Cleft Palate and Speech. 5th Ed. Edinburg. Livingstone (1962).
17. Nicholas, G., Glorgiade, N. G.,: Plastic and Reconst. Surg. 39:162, 1967.
18. Owsley, J. Q., Chierici, G Miller, E.P.: Plast. Reconst. Surg. 39:562, 1967.
19. Rehrman, A. : Modern Trends in Plastic Surgery 1:50, 1964.
20. Reidy, J.P. : Brit. J. Plast. Surg. 12:208, 1959-60.
21. Reidy, J. P.: Brit. J. Plast. Surg. 13:340 1960-61.
22. Reidy, J. P. : Brit. J. Plast. Surg. 15:261, 1962.
23. Schmid, E.: Die Wiederherstellung des Kauorgans bei spalttragern Dtsch. Zoharzt. Z. 16 : 271, 1961.
24. Schuchardt, K.: Die primare Knocheu-transplantation being Ver schluf von lippen-Kiefer-Gaumenspalten Dtsch Zohn-Mund U. Kieferheiltkunde. 37 185, 1962.
25. Schuchardt. K.: Second Hamburg International Symposium July 64.
26. Sharma R. N. : Acta Chir. Plast. 8:3, 1966.
27. Sten. J., Stenstron: Plast. Reconst. Surg 32:353, 1963.
28. Wallace, A.B. : Brit. J. Plast. Surg. 16:37, 1963.
29. Wilde, J. : Brit. J. Plast. Surg. 13:28 1960-61.