

Gillies Memorial Oration 1974

Murari Mohan Mukherji

Surgery owes an enormous debt to Late Sir Harold Gillies, who by his own bold approach and indifference to the views of orthodoxy, won a world reputation for his sometimes seemingly miraculous achievements in Plastic Surgery.

"I have said in public on many occasions", writes Sir Heneage Ogilvie that during my life I have only known three Surgeons who were undoubtedly first class. They were Geoffrey Jefferson, Harold Gillies and Rusell Brock. Apart from Arbuthnot, who was before my time, they were the only men in Europe and America who have taken a branch of Surgery and by their own effort, by their leadership, their research and craftsmanship, have left it far higher than they found it. To say that of Gillies is an understatement, he invented Plastic Surgery. There was no Plastic Surgeon before he came. Everything since then, no matter whose name may be attached to it was started by Gillies perfected by him and handed over by him to lesser men, who have often claimed it as their own (Letter March, 18, 1963).

The Plastic Surgeons of India were lucky to have Sir Harold Gillies in India in 1957 and 1959. In 1957 Gillies inaugurated the Plastic Surgery section of the Association of Surgeons of India at Nagpur. Sir Harold did a considerable number of operations in Bombay, Calcutta, Patna, Nagpur and

Delhi etc. He delivered a series of lectures. In a word he was again a pioneer in introducing Plastic Surgery in this subcontinent where in early years of civilization Hindu Surgeons discovered the art of Plastic Surgery.

Broadcasting on All India Radio Gillies reminded the Indians "that historically India is the oldest country in the world that has done Plastic Surgery but it has dropped back a good deal. It was a privilege, he said, to come to help this great India in Surgery which is our love in particular."

Like Sir Harold, pioneer modern Plastic Surgeons of India had to toil hard to establish their position and status of Plastic Surgery in this Country. They had to write articles in different journals including journals for lay public. They had to deliver lectures in Medical Associations and other General bodies, they had to help the general Surgeons and thus the status of Plastic Surgery was established in different parts of India. This is the background upon which I have the good fortune of delivering the Gillies Memorial Oration to day. To-day's talk will cover the subject of Lymphedemas and their treatment.

In 1938 Gillies and Fraser reported a Lymphedema case with a new approach to the problem. They implanted a bridge of skin and subcutaneous tissue with its contained

lymphatics from the arm to completely bypass an inguinal obstruction and this allowed the affected leg to drain into the intact axillary system on the same side. On one or two occasions the free lower margin of the omentum was brought out through the inguinal region to be implanted into the subcutaneous tissue of the thigh for its lymphatic drainage. Taking the above account into consideration Rainsford Mowlem raised a pedicle flap from midaxilla to umbilicus and implanted its lower end into the thigh. The upper end was then severed and was implanted in the axillary drainage area i.e. above the umbilicus.

Mowlem found good results in early

lymphedemas. In late stages of lymphedema the pedicle bridge flap as named by Mowlem had to be combined with excision of excess fibrofatty tissue of the leg with skingraft or skinflap. Both the previous Surgeons experimented on these operations when the knowledge about the existence and distribution of lymphatics were derived from the department of Anatomy.

Hudac and McMaster in 1933 demonstrated the lymphatics by injecting sky blue dye with a 30 gauge hypodermic needle

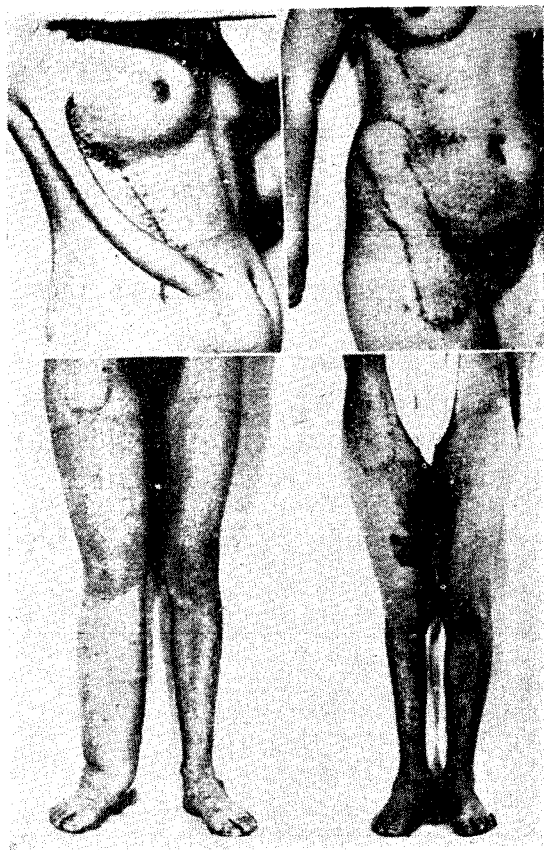
According to Pratt, the lymphedematous part had a distinct increase in its venous component to aid venous drainage. This has been confirmed by venographic studies



Gillies inaugurating Plastic Surgery Section at Nagpur

in our unit. Most of the second, third, and fourth stages of lymphedema show dilation, with tortuosity leading finally to failure of the venous system. This further increases the edema to the already affected part.

Kinmonth, by injecting radio-opaque drugs into the lymphatics, paved the way for



Mowlem's Operation for Lymphedema

investigations into a number of conditions in which lymphatic vessels are involved. He demonstrated normal lymphatics in 50 persons, but in about 2 per cent there was hypoplasia of the normal lymphatics. In some there is only a single lymphatic vessel going up to the inguinal region.

According to Rao, filarial infection may manifest in two ways, filarial toxin, and secondary infection. Repeated secondary infection by streptococcus may produce lymphangitis and cause destruction of lymphatics and thus blocking of the lymphatic flow. Filarial larvae in the lymphatic gland produces inflammation & granulation tissue. Repetition of such inflammation may cause blockage of the lymphatics with all the phenomena of lymphedema.

Rao added that few of the infected persons, living in endemic areas manifesting signs of lymphatic obstruction may have an individual susceptibility.

Our own investigations suggest that those persons who have hypoplasia of the lymphatics are more susceptible to the development of lymphedema.

Pathology of Lymphedema

Edema means excessive amount of fluid in the tissue spaces and results from excessive formation or diminished drainage. In lymphedema, there is a blockage of the lymphatics with a reduction in the drainage of tissue fluid. The edema fluid is richer in protein content (1 to 5 per cent). This type of edema is completely or partially nonpitting, owing to the laying down of new connective tissue.

When lymph stasis is sufficiently prolonged, the stagnant protein-rich tissue fluid causes local tissue reactions in the fascia, fat, and skin of the leg, thigh, or entire limb. A network of dense fibrous tissue is laid down in interlacing fashion in the subcutaneous fat. The fat lobules are first hypertrophic and edematous, but later on they become com-

pressed and atrophic between the multiplying and proliferating fibrous bands. The skin is at first thin, stretched, and shiny. Later, it becomes thickened as a result of the proliferation of fibrous tissues in the dermis.

Sclerosis and obliteration of the lymphatic capillary plexus in the dermis leads to thickening and hyperkeratosis of the epidermis, which is then subject to vesiculation, weeping, and ulceration. In the distal portion of the limb where the effect of stagnation is more pronounced, the lymphedema is more advanced than in the proximal portion.

Having had treated a number of Filarial Elephantiasis of legs by excision and skin-grafting with deplorable results, it was decided to study this group of patient in detail.

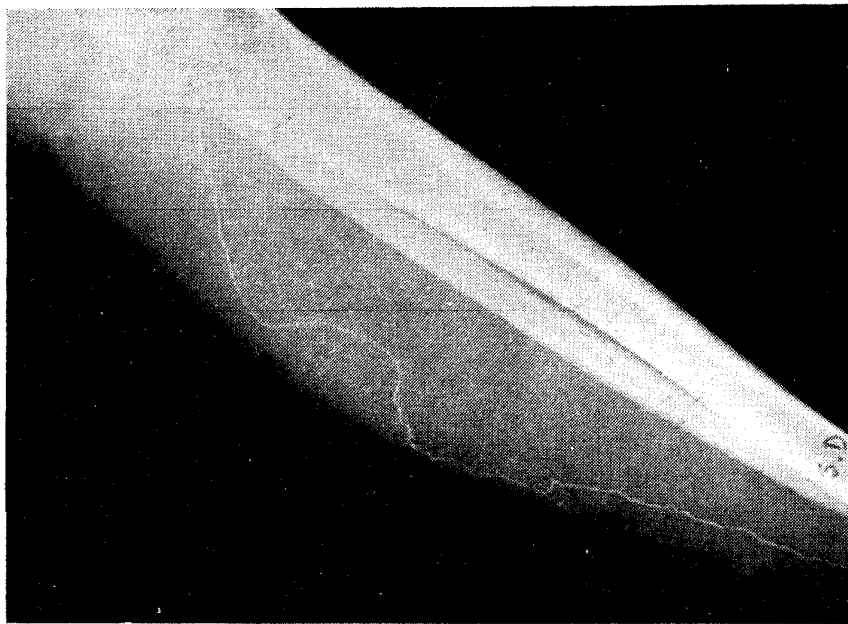A detailed study was made on 100 patients with lymphedema of legs (Filarial) and six patients with lymphedema of arms after

radical mastectomy and irradiation.

Results of Study of Lymphedema of Legs :

A detailed study was made on 100 patients with lymphedema of legs. Clinical features studied included age and sex distribution, social status, and duration of illness. Laboratory and special investigations included (1) estimation of serum proteins and protein content of the edema fluid, (2) lymphographic studies, (3) venographic studies, (4) radiopaque dye clearance rate in lymphedemas (no definite conclusions revealed) and (5) histological examination of the affected tissues.

The lymphedematous tissues showed loose edematous finely fibrillar tissues with widespread dispersion of the nerves and muscular tissue of the skin. In the early stages of the disease, dilated lymphatics could be detected amongst the dense fibrous tissues.



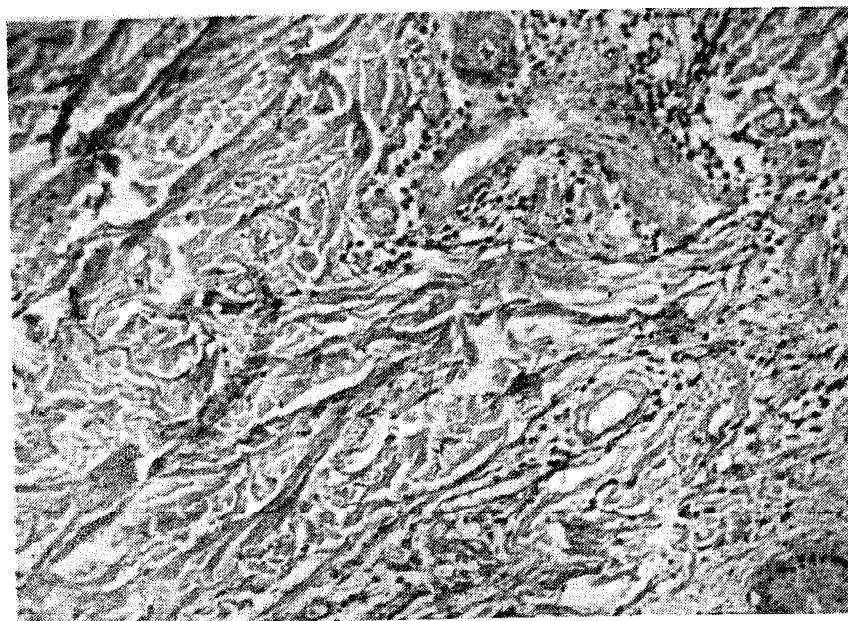
Showing hypoplasia of Lymphatics

TABLE I

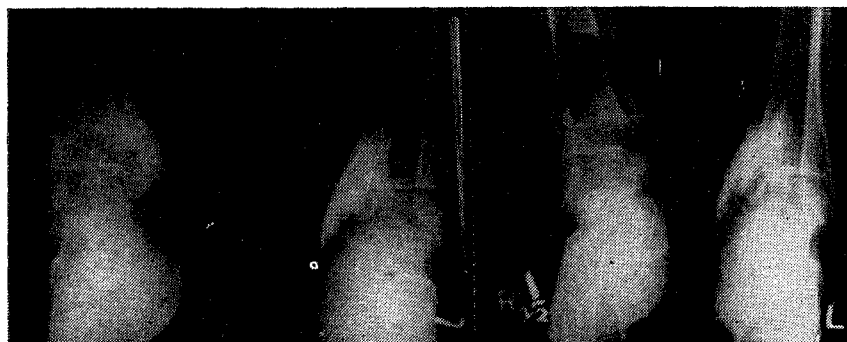Age	Male	Female	Total
0—10	1	1	2
11—20	14	18	32
21—30	12	12	24
31—40	14	4	18
41—50	12	6	18
51—60	2	4	6
Above 60	nil		
	<hr/> 55	<hr/> 45	<hr/> 100

The average serum protein estimation in more than 50 patients with lymphedema was 6.5 gm per 100 ml. of blood with an albumin globulin ratio of 4.25:2.5. The average total protein in the lymphedema fluid estimated in the same number of patients was 4.00 gm. per 100 ml. and the albumin globulin ratio was 2.5:1.5.

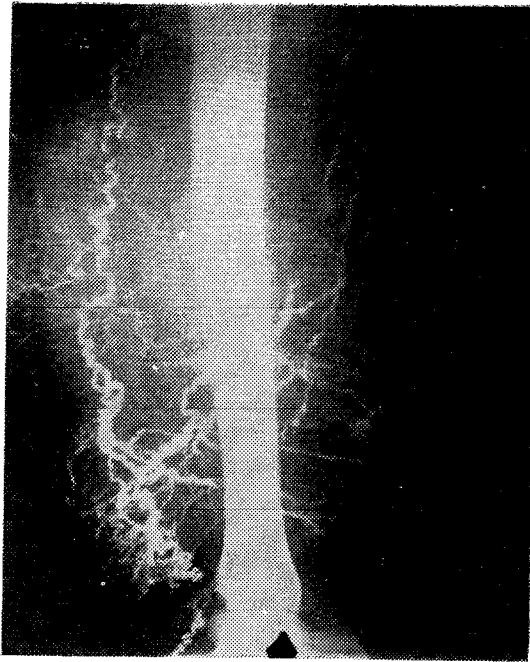
Lymphographic studies produced different results at different stages of the disease



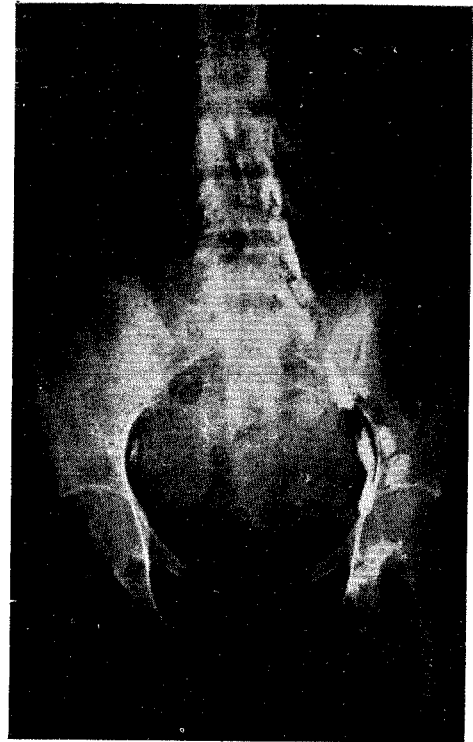
Showing Histology of Lymphedema Tissues



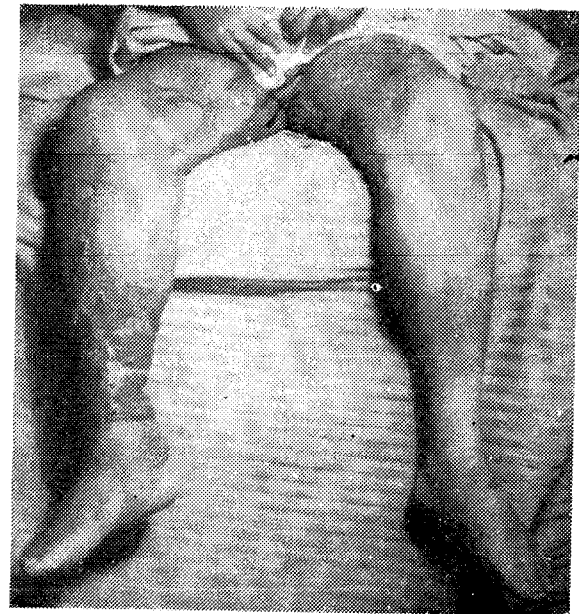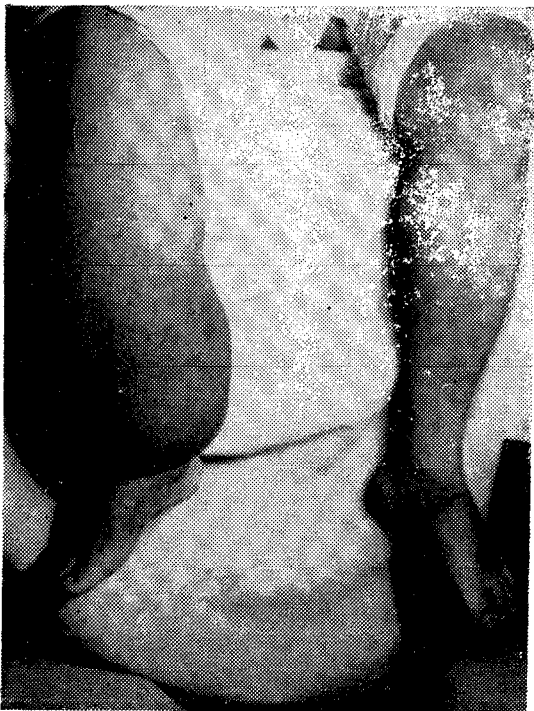Radio-opaque dye clearance



Showing dilated and corkscrew type of Lymphatics



Showing normal Lymph node chain on opposite side



Lymphedema cured by cross-leg flap

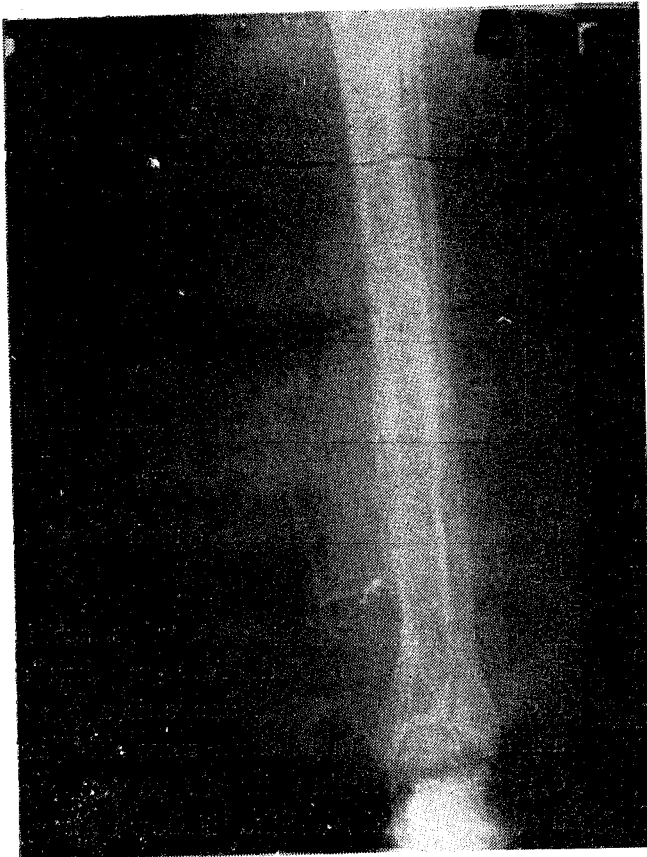even in the same patient. In the early stages, i.e. stages 1 and 2, the lymphatics were dilated and increased in number with more branchings. In stage 3, the lymphatic vessels were more dilated, with a corkscrew appearance. It was difficult to visualize any lymphatics in stage 4 disease. Both stage 2 and stage 3 cases showed dermal flowback.

Venographic studies by intra-osseous venography shows dilatation and varicosity of the veins in the early stages of lymphedema. Later, the veins become even more dilated, varicose, and tortuous, with secondary incompetence resulting from loss of function of the valves. The venous edema

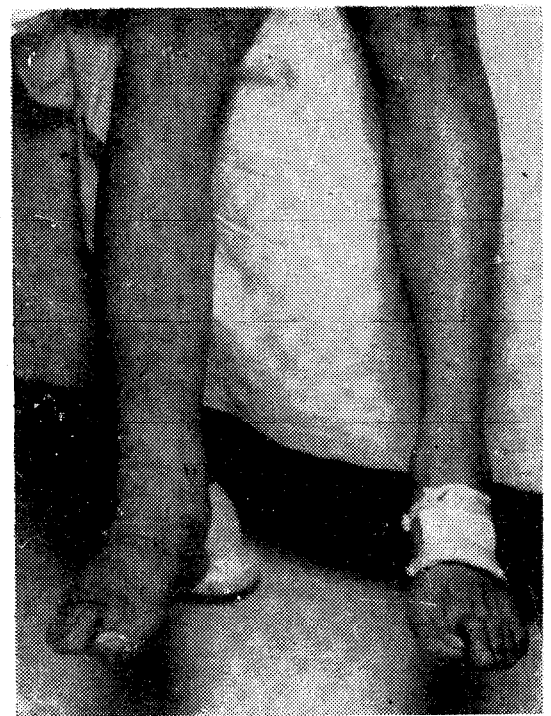then starts to aggravate the already persistent lymphedema.

A radio-opaque dye (35 per cent Pyelosil) was injected into the subcutaneous tissues of the lymphedematous and normal leg and x-ray films were taken at half hour intervals. The dye clearance test gave no significant help because there was not much difference in the clearance rates in the affected and nonaffected leg.

Secondary lymphedema may be due to obstruction or destruction of the lymphatics. Evidence seems to point to the obstructive nature of the condition. The dilated cork-



Showing dilated veins in a hugely enlarged leg



Showing Stabilization after operation for 1st stage (15 yrs.)

screw-shaped lymph vessel, the dermal flow back, and the discontinuity of the vessel higher up in the limb all prove that lymphatics in the inguinal region or in the retroperitoneal region are affected. The inability of the lymphatics to drain the tissue fluid from the limb is compensated by increased venous drainage and continuous tissue spaces draining the fluid to higher and higher levels.

These two factors are also substantiated by the observation that there is venous hypertrophy and later incompetence in the different stages of lymphedemas. Lastly, there is seldom any lymphedema above the level of the knee in all these patients with filarial elephantiasis. If one tries to correlate the stages of lymphedema with the drainage of lymph, the following observations will be helpful.

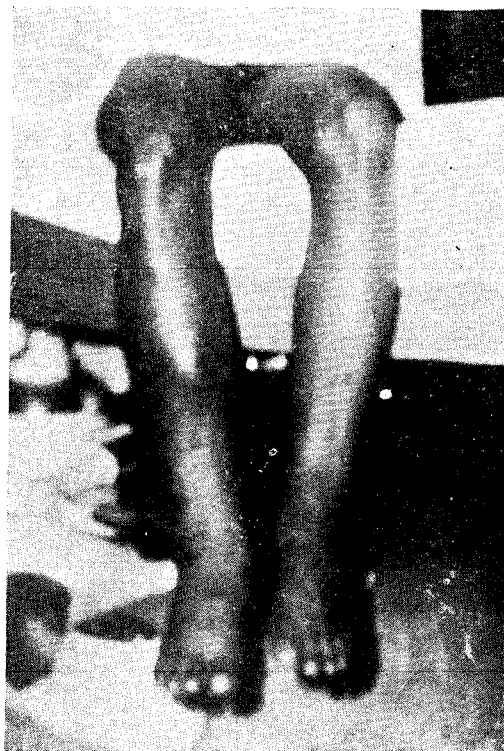First Stage Lymphedema (Acton and Rao). During this stage, the soft edema of the feet disappears after a night's rest. Nature succeeds in draining the excess lymph which has collected during the day when the patient is upright, by affording better drainage of the venous system and of the contiguous tissue space during the recumbent position.

Treatment : Multiple venous ligations are done and this is combined with a Trendelenberg operation on the venous system of the inferior extremity. The followup of a few patients treated this way has shown the efficacy of this form of management. They have had no aggravation of lymphedema for 10 to 20 years.

Second Stage Lymphedema (Acton and Rao).

The soft edema of the feet does not

disappear after a night's rest. This means that the venous system and the contiguous tissue space drainage is not capable of completely removing all the lymph that has collected during the day's work in the erect posture, even after a whole night's rest in the recumbent posture. Some vehicle is needed



Cure of Lymphedema of 17 yrs.

to help in draining off the lymph from the leg and the foot.

Treatment : Polythene tubes are implanted at the level of the foot and they are brought up in the subcutaneous tissues to the axillary drainage area of the same side or the opposite side. Eight pairs of such tubes are used in each affected limb. Follow-up results have again proved the efficacy of such an operation.

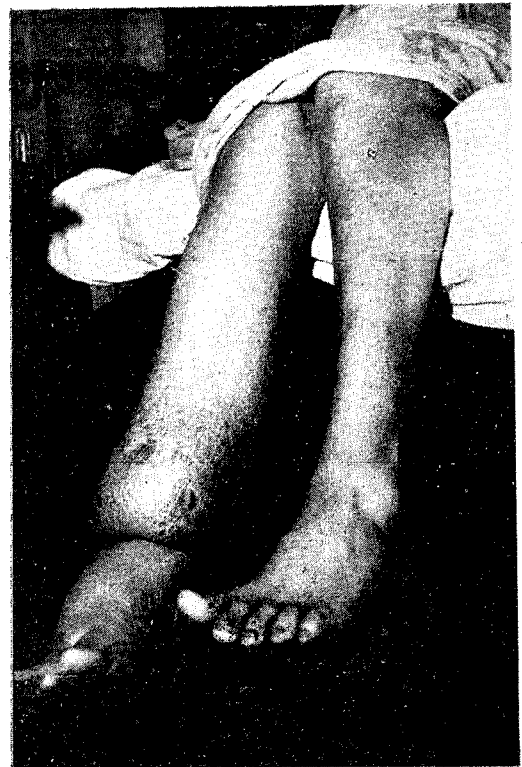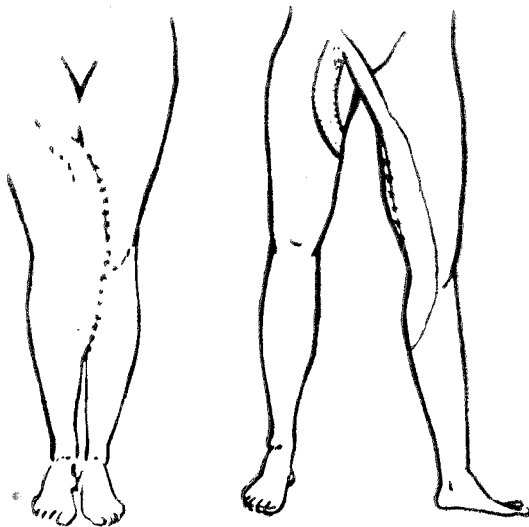
The tubes have been kept in place for more than 15 years and the edema remains controlled. Although the edema is not totally cured, there is no further aggravation of the symptoms and the legs are fairly well shaped. Lymphatic fluid has been found inside the tubes even when removed 1 to 2 years after implantation. Moreover, patients complain of pain and swelling in the axillary area for any infection of the foot.

Third Stage Lymphedema (Acton and Rao).

This is the stage when solid edema has formed and has become permanent. Not only has the normal mechanism for the evacuation of lymphatic fluid failed, but now the venous system, which has remained hypertrophied

for a long time, starts signs of inefficiency. So venous edema is added on to the lymphatic edema.

Treatment : The problem can be solved only by long lymphatic bearing skin flaps. Gillies devised a lymphatic-bearing skin flap by taking an oblique skin flap from above the umbilical region and fixing the end of the flap to the inguinal region. However, this type of flap failed to drain sufficient amount of the edema. A new method of making a cross-leg flap and designing the same flap to drain the lymph through the healthy inguinal region has been devised. The operation is time-consuming but the results have been good and the skin flaps drain the lymphedematous tissues fairly efficiently.



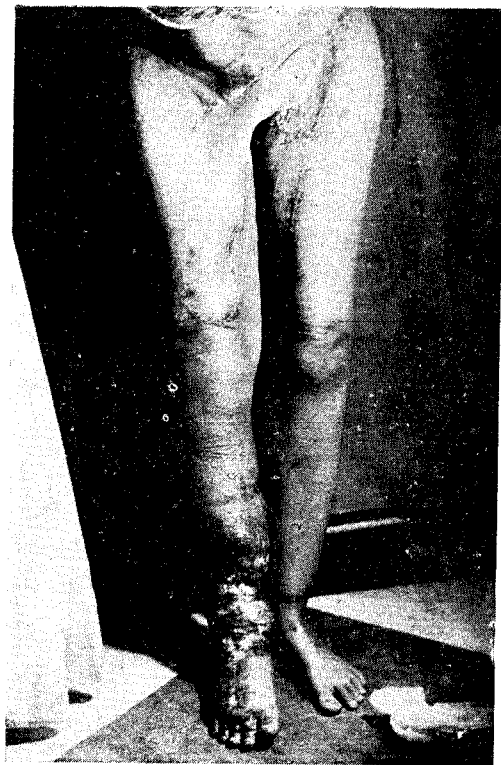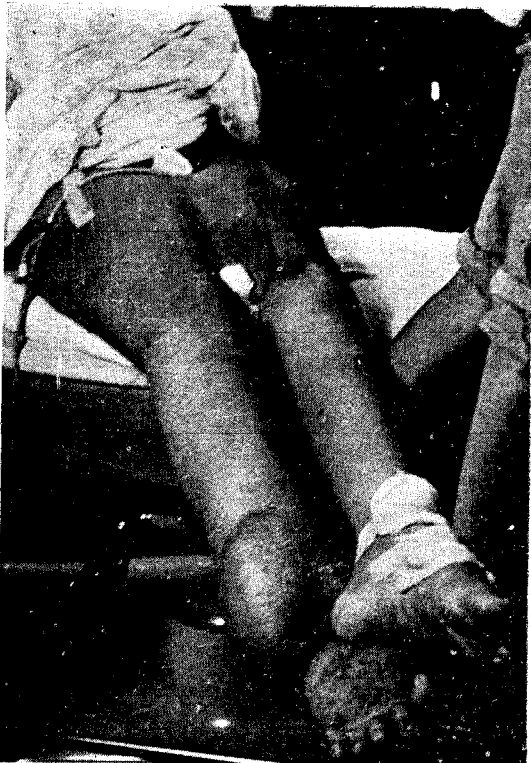Shows the diagrammatic plan and operation stages for cross leg flap and Lymphatic pedicle from the normal leg

Construction of Lymphatic-Bearing Skin Flap:

Even when only one leg is affected with lymphedema lymphography is advised for both legs to show the pattern of lymphatics on the unaffected leg. If the lymphatic pattern is normal, in the unaffected leg a cross-leg flap is designed and this runs from the middle of the leg upward, right to the inguinal region. A flap from the normal leg is attached to the lymphedematous leg, and a similar flap from the lymphedematous leg is attached to the normal leg. In about 3 to 4 weeks when the flaps get firmly united, the lymphedema disappears rapidly. The enormously fat leg becomes soft and the excess skin hangs down in folds. Now a curved flap is designed across the inguinal region so that

this portion of the flap can be attached to the perineum in male and to the suprapubic region in the female. A small area on the normal leg needs skin-grafting after which the legs can be separated normally. The patient can squat and there is no difficulty with normal functions. When the lymphatic bridge flap is properly fixed, it drains lymph from the elephantoid leg to the normal leg. The excess skin is removed from the diseased leg and the leg and foot are shaped properly.

A 15 years follow up of the patients has abundantly proved the efficacy of this treatment. Although the lymphedematous leg does not become absolutely normal, it shows considerable improvement. The disease is controlled and the patient remains happy.



Showing the diagrammatic plans and operation stages of cross-leg flap and Lymphatic pedicle from the normal leg.

Fourth stage lymphedema (Acton and Rao).

Fourth stage Lymphedema can also be relieved by the lymphatic bridge flap.

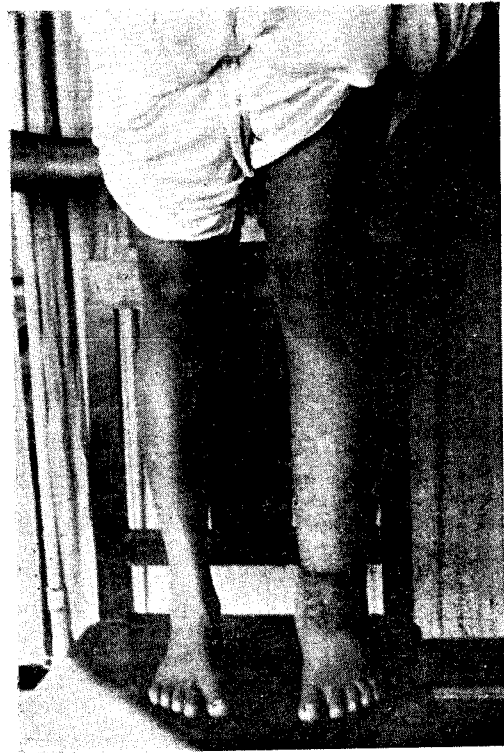But in the fourth stage lymphedema the skin may have undergone secondary changes like Warts, excrescens, and ulceration. So in such patients, skin thus involved has to be excised and grafted.

Lymphedema of both legs can be relieved only by fixing two lymphatic-bearing skin flaps from the forearms and upper arms of both upper extremities. These flaps create a bypass between the inferior and superior lymphatic drainage areas, and help to deliver the lymph from the inferior extremities to the axillary area

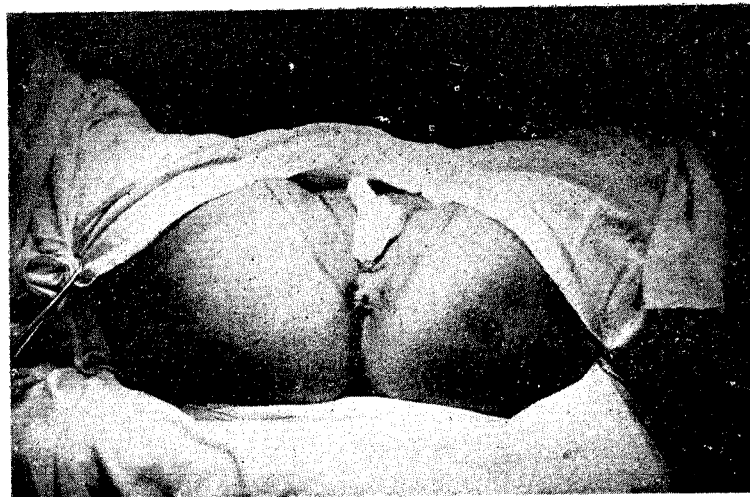Lymphedema of the superior extremities were all due to one cause e.g. radical excision of breast for carcinoma followed by deep x-ray therapy. They have been studied thoroughly including lymphography.

In one case, the patient could not be operated on because of a cardiac condition, so polythene tubes were implanted from the level of wrist to the opposite axillary drainage area. But the rest were treated by lymphatic bridge flap to the opposite axillary drainagesystem.

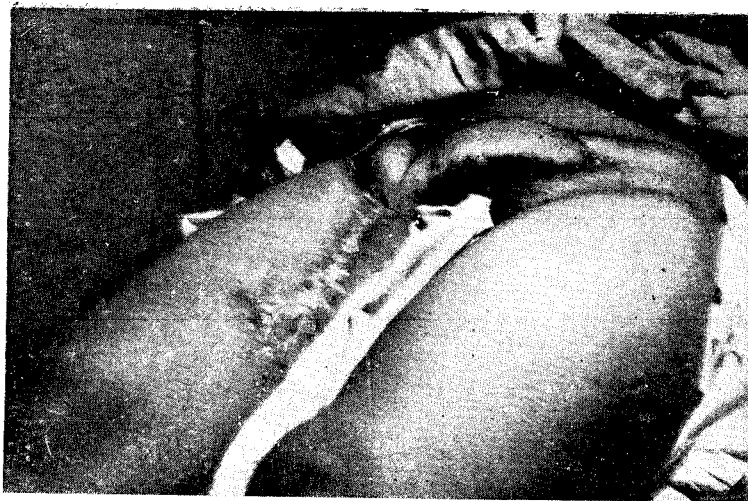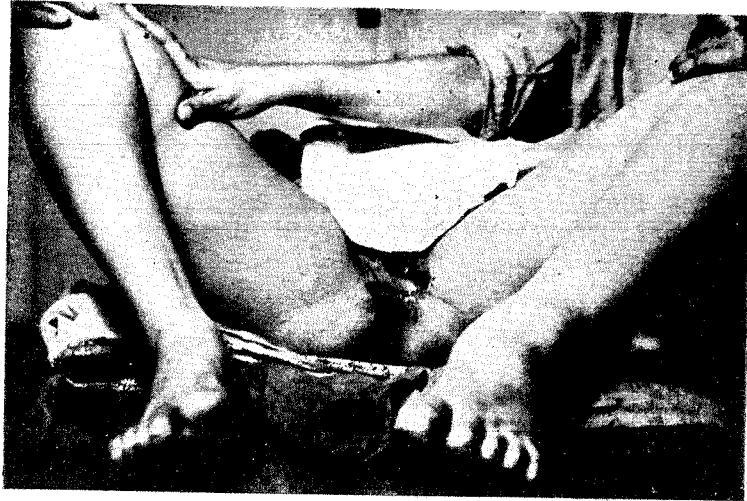
The best result has been in the last patient and part of her hanging breast was utilised for making a lymphatic bridge flap. This lady could not move her superior extremity for the last 15 years.

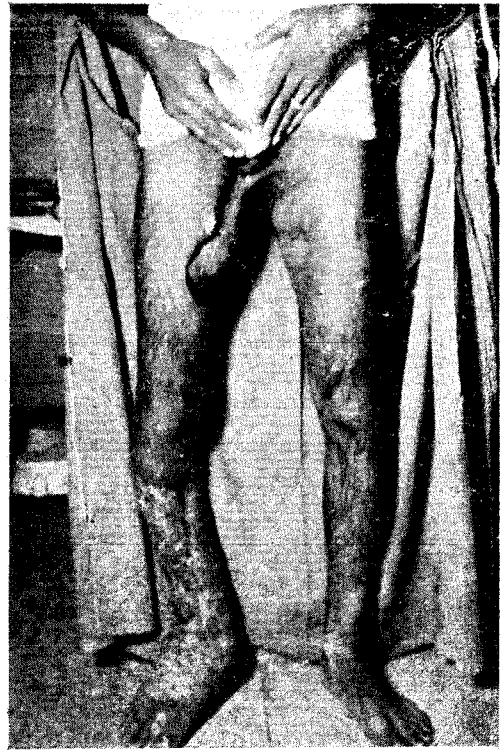
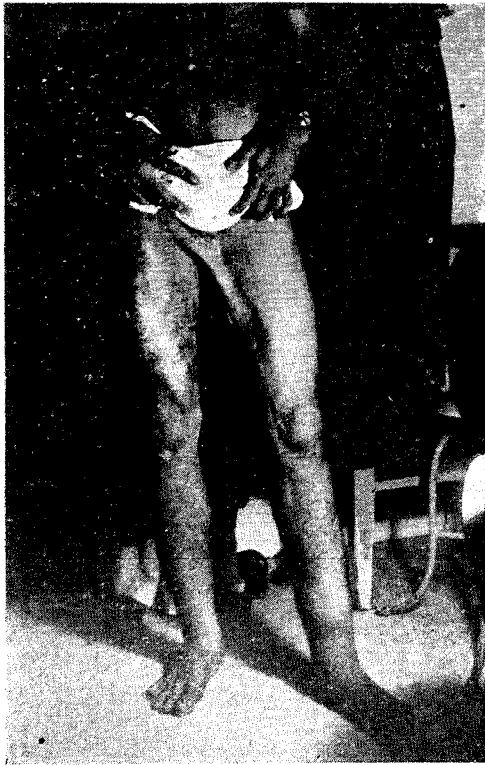
Shows the small Lymphatic pedicle of cross perineal flaps reinforced by a Suprapubic Lymphatic pedicle

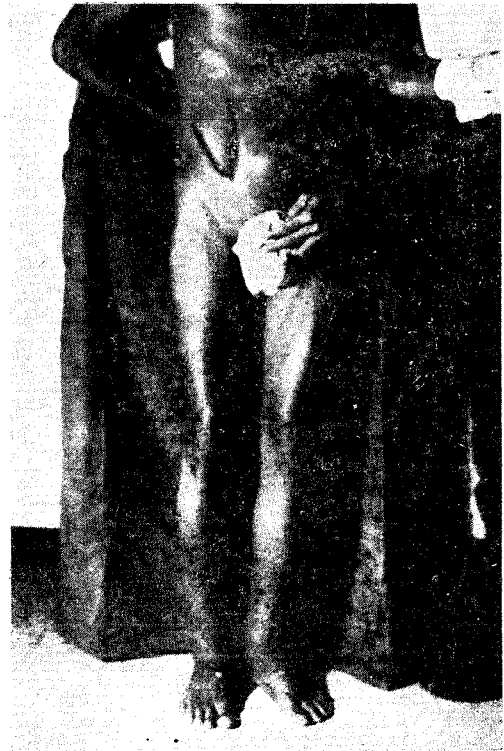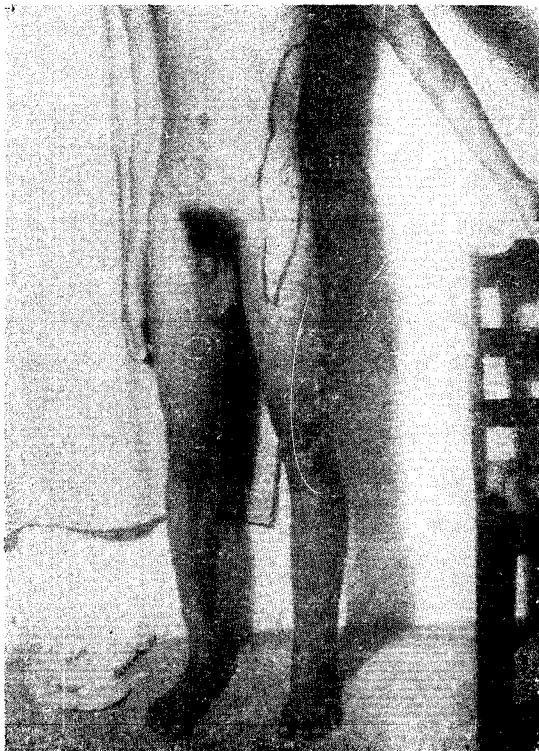


Shows the small Lymphatic pedicles of cross perineal flaps and reinforced by a Suprapubic Lymphatic pedicle

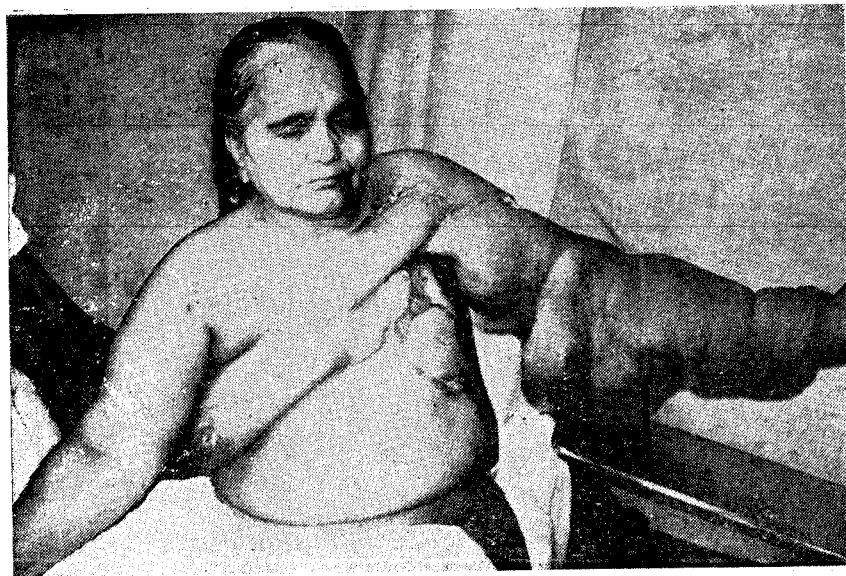


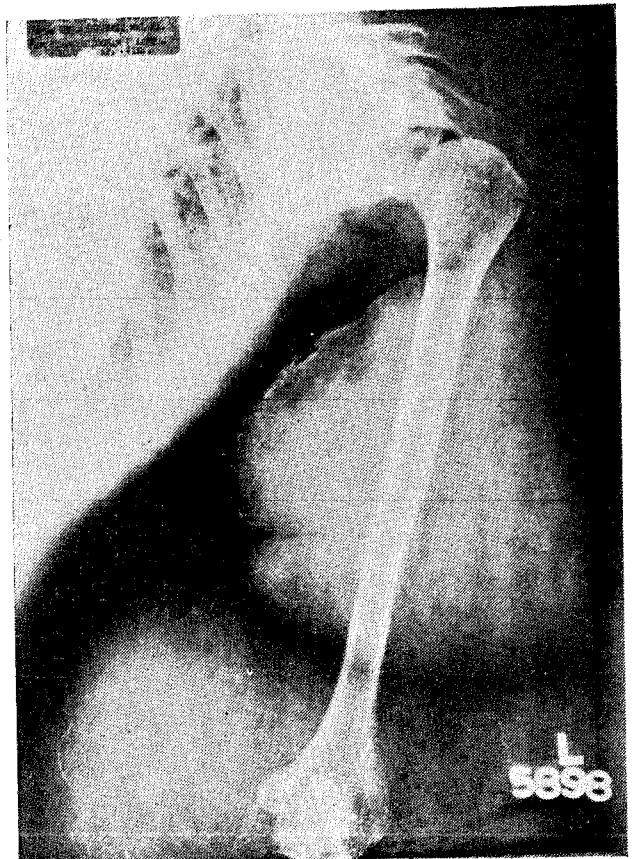
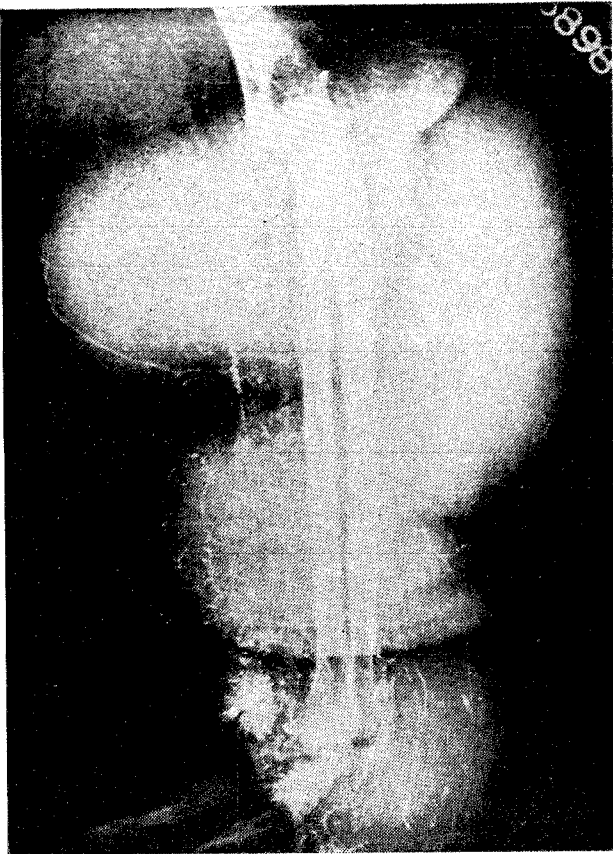


Shows that small cross thigh pedicles also help in draining Lymph in Lymphedema patients



Shows the solution of Lymphedema of both legs. Lymphatic bearing flaps of forearm are bypassing the obstruction





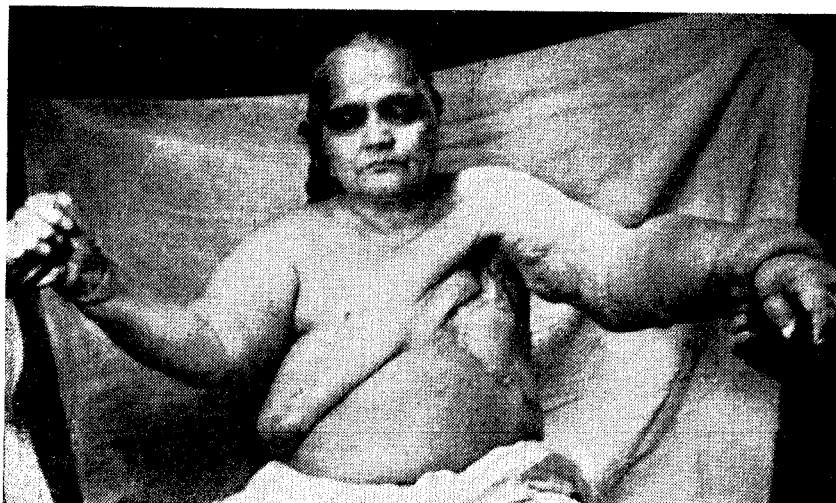
This lady's wrist was fixed to the inguinal drainage area to reduce the size and make it manageable for operation. But one month's fixation did not show any effect proving that the lymph can not drain against the normal direction of flow. But as soon as the lymphatic bridge flap was attached even to the upper part of the arm, the hugely distended limb drained a considerable amount of fluid.

She had two operations for excision of the loose and hanging skin and for shaping

the extremity after the drainage operation succeeded.

In conclusion one would feel that lymphatic bridge flap is the one and only one solution for all lymphedemas. The excision of the lymphedematous tissues may have to be done after drainage of the lymph by the bridge flaps has been established.

Thank you all for listening to my lecture and for inviting me to deliver this oration.



REFERENCES

1. Aristotle : Quoted by Perrott, J. W. : *Edin. Med. J.*, 6:50, 1954.
2. De, M.N., and Chatterjee, K.D. : *Text Book of Bacteriology*. Calcutta, Statesman Press, 1935.
3. Drinker, C. K., Cecil, K., Homans, J., and Field, M.E.: *Ann. Surg.*, 100:812, 1934.
4. Gillies, H., and Fraser, F.R. : *Brit. Med. J.*, 1:96, 1935.

5. Gillies Surgeon Extraordinary by Reginald Pound Pub. Michael Joseph, London. 1964.
6. Hudac, S.S., and
McMaster, P.D. : J. Exper. Med., 57:751, 1933.
7. Kinmonth, J.B. : Lymphedema and its treatment (editorial). Brit. J. Plast. Surg.,
7:198, 1954.
8. Manson-Bahr,
P.H. : Manson's Tropical Diseases. London, Cassell & Co., Ltd , 1954.
9. McIndoe, A.H. : Proc. Roy. Soc. Med. (Lond.), 28:1111, 1935.
10. Mehta, P.V. : Ind. J. Surg , 12:89, 1950.
11. Mowlem, R. : The treatment of lymphedema. Brit. J. Plast. Surg , 1:48, 1948.
12. Pratt, G.H. : J.A.M.A., 147:1211, 1951.
13. Gillies, H. &
Millard, D. R. : Principles and Art of Plastic Surgery Little, Brown and Company
Boston. 1957.
14. Rao. S.S. : Ind. Med. J., 56:294, 1921.
15. Sistrunk, W. E. : Surg. Gynec. Obstet., 26:388, 1918.