

## Hair Transplantation For Male Pattern Baldness

*Ramesh Chandra\**

Premature baldness in males causes considerable concern. Baldness (Alopecia) is defined as any loss of hair, whether congenital or acquired, caused by; genetic factors, trauma, chemical agents, hormones, neurological, psychiatric, nutritional, metabolic, occupational and dermatological disorders. Reliable measures of prevention do not exist though there has been a quest for them from historical times.

The relative paucity of scalp hair in men is compensated by better growth of hair on the chest and body which are a masculine characteristic. Premature baldness is often considered a natural tribute to maturity and prosperity. The sufferer however feels socially handicapped.

### **The Hair Population :**

The average number of hair in 1 sq. in. of the scalp is about one thousand. The surface area of the scalp being 100 to 120 sq. in. which brings the total number of hair to about 1 or 1.2 lacs. About 90% of these are in the Anagen Phase (growing phase). The rate of growth is about 0.35 mm/day i.e. about 1" in 3 months. When baldness sets in, the number of hair in the telogen phase (resting phase) decreases, resulting in greater loss of hair day by day.

### **The Composition of the Hair**

The healthy human hair is composed of 50-54% carbon, 6% hydrogen, 17-18% Nitrogen and 1-8% sulphur and the balance consists largely of oxygen. When the hair is burnt, 0.5 to 2% of the ash is obtained which contains sodium, potassium, calcium, magnesium, phosphorus, silicon, chlorine, copper, and iron.

### **The surgical Management of Baldness**

Patients willing to offer themselves for hair transplantation are mostly over confident about the success of the procedure. They believe that surgeons' have some magic with them. Thanks to the lay-press which helps, in preparing these patients so well. They however do not realise that their loss is in thousands while the surgical procedures would atmost provide a few hundred hair only.

While discussing hair transplantation it is essential not to withhold information from the patient (Ayres). He should be made aware that considerable patience will be required as the new growth of hair is very slow and that it will be several months before the full growth is attained. The original crop of transplanted hair perish in about a months time. Regrowth then occurs

---

\*A.M.S., M.S. Reader in Plastic Surgery, Medical College, Lucknow.

at the rate of 0.3 mm to 0.4 mm a day and this stays on.

The punch graft technique of hair transplantation was first described by Orentreich (1971). A 4 mm size cylindrical punch grafts are obtained from the donor areas of the scalp usually lower parietal and occipital regions. The donor defect is closed by a stitch. Holes of 3.5 mm size are made on the proposed frontal hair line with the skin punch graft device at a distance of about 3.5 to 4 mm.

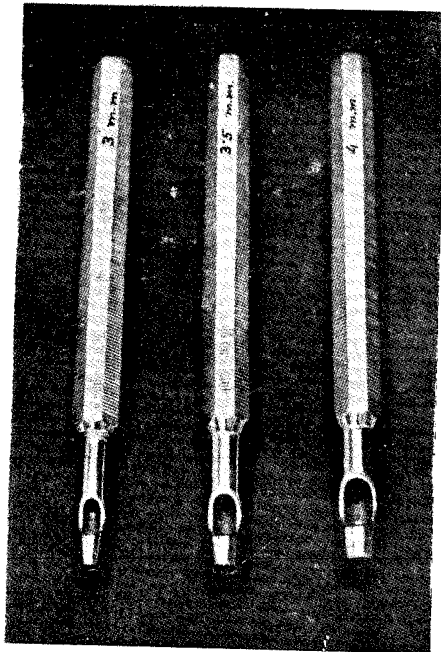


Fig. 1.—Showing 3 punches of 3, 3.5 and 4 mm diameter

The cylindrical hair transplants are plugged into these defects. Light pressure is applied to control bleeding. At a time 50-60 or more such transplants can be easily done under general or local anaesthesia.

The punch grafts may be coupled with strip grafts (Vallis). Rotation flaps from

hair bearing areas first described by Lamont, Limburger can be tried in selected cases with advantage. Not much is yet known about the unpublished technique of Medical hair transplants receiving fair trials in the U.S.A., except wide publicity given by the Times Magazine. Criteria of suitability for punch grafts or strip graft technique are as follows.

#### Criteria for Accepting A Patient

1. Men with premature baldness (in the younger age group between 20 and 40) are helped most.

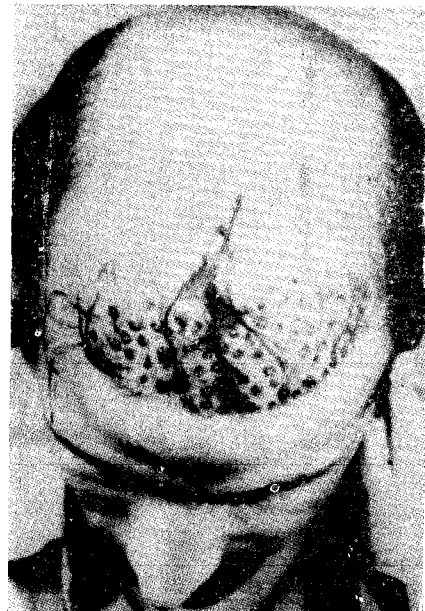


Fig. 2.—Showing the appearance of the punch grafts 3 weeks after transplantation

2. Patients with moderate recession get the best results.
3. Highly motivated patients, who understand the limitations and the discomforts of the operations, are good candi-

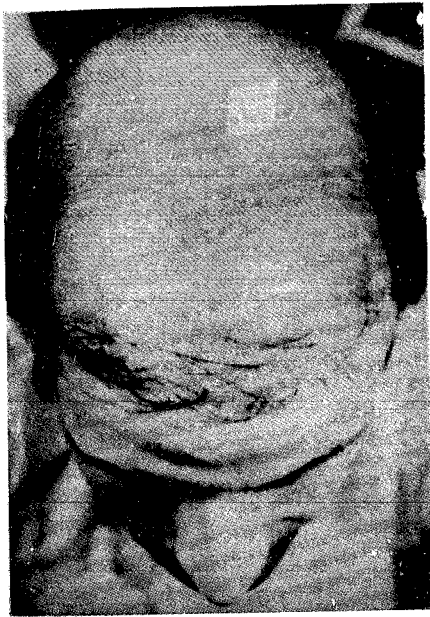

Fig. 3—Showing the hair growth in the frontal region 3 months after operation

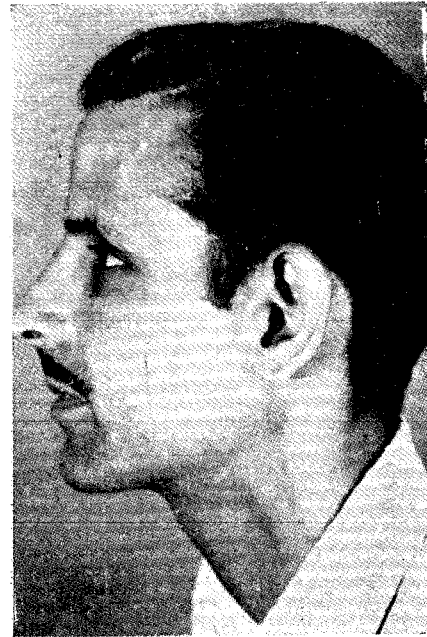

Fig. 4—Showing the appearance of the patient 2 years after operation

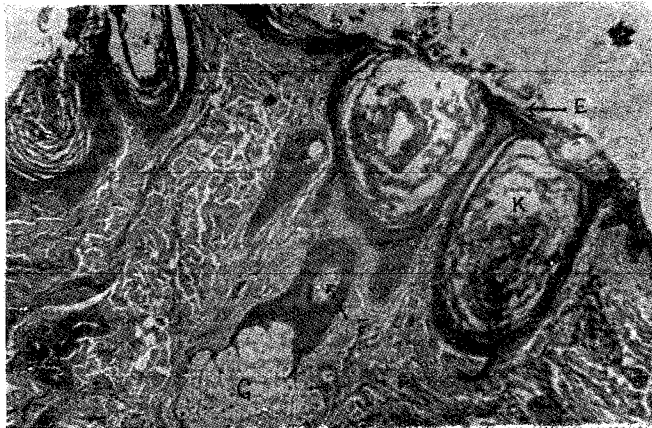
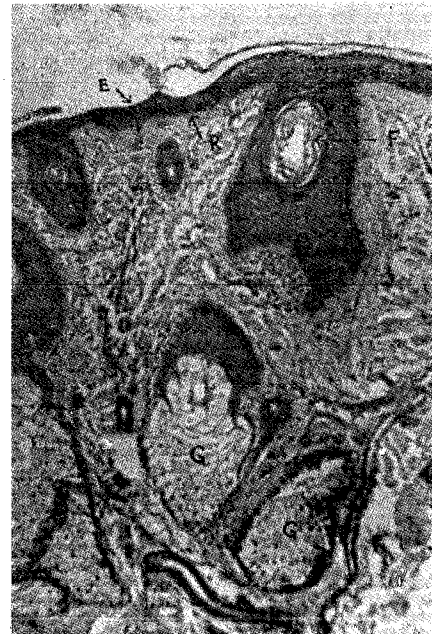
Fig. 5 & 6—Showing histological changes in the bald area on the forehead.



dates especially those who simply want a little more hair than they have and are not looking for miracles.

4. Patients should have dense hair growth of good quality in the donor areas. Density of hair depends as much on the amount of hair growth as on the number of individual hair follicles.

#### **Criteria for refusing a patient**

1. Patients with diseased scalps.
2. Patients with fine, silky, blonde hair are poor candidates.
3. Severely bald patients, with insufficient hair in the donor sites.
4. Patients over 60 years of age wanting the hair transplant procedure should be sent to a wig maker or should be asked to seek an interview with a Psychiatrist.
5. Patients with any form of severe systemic disease such as coronary insufficiency or high blood pressure should be refused.
6. Patients with only minimal loss of hair. They should be told to come back when there is an actual recession of hair line or baldness.
7. Young patients with a normal hair pattern seeking lower frontal hairlines. The current vogue of the "shaggy dog look" is not an indication for surgery. This type of patient should be refused.

8. The creation of scars in the donor and recipient areas, although minimal, is a definite deterrent to some patients.

#### **Observations**

Mr. S. M. H. Zaidi\*, 30 years, male, an employee of the local Shia College, Lucknow offered himself as a candidate for hair transplantation at the Post-graduate Department of Plastic Surgery, Medical College Lucknow. He is the first individual reported in INDIA to have successful hair transplantation done for baldness. The punch graft technique (Fig. 1) of hair transplantation was tried on him (Fig. 2). His appearance 3 months after the operation is shown in Fig 3. His appearance two years after surgery (Fig 4) is shown. Histological studies of the bald area (Figs. 5, 6) revealed thinning of the epidermis, loss of rete pegs, atrophied hair follicles with keratotic plugs, and proliferated sebaceous glands which probably would explain the extra shine that one sees in bald patients.

#### **Acknowledgements**

The author gratefully acknowledges the timely guidance and help given by Prof. R. N. Sharma, M.S., F.R.C.S., Head of the Post-graduate Department of Plastic Surgery, Medical College, Lucknow.

#### **REFERENCES**

1. Ayres, S., : Conservative Surgical Management of male pattern baldness : An evaluation of current techniques. Arch. Derm., 90 : 493-499, 1964.
2. Lamont, E. S. : A plastic surgery transformation West. J. Surg., 65 : 164, 1957.

3. Limburger, S : The surgical treatment of hair loss. *Medizinische*, 35 : 1559, 1959.
4. Orentreich, N : Autografts in alopecia and other selected dermatological conditions. *Ann. N. Y. Acad. Sci.*, 83, 463-479, 1959.
5. Orentreich, N : Pathogenesis of alopecia- *J. Cosmetic chemists*, 11 : 479-499, 1960.
6. Orentreich, N., : Local injections of Steroids and hair regrowth in alopecia, *Arch. Stum, H.M., & Derm.*, 28 : 894-902, 1960.  
Weidman, A. L.
7. Orentreich, N. : Hair Problems, *J. Amer. Med. Wom. Assoc.*, 21 : 481-486, 1966.
8. Orentreich, N : Hair transplantation : The punch graft technique, *Surg. Clin. North Amer.*, 51 : 511-518, 1971.
9. Stough; D. B., : Surgical improvement of cicatricial alopecia of diverse etiology.,  
Berger, R. A , & *Arch. Derm* , 97 : 331-334, 1968.  
Orentreich, N.
10. Vallis, C.P. : Surgical treatment of the receding hair line. *Plast. Reconstr. Surg.*, 37 : 247, 1964.
11. Vallis, C.P. : Surgical treatment of the receding hair line, *Plast. Reconstr. Surg.*, 40 : 138 : 1967.
12. Vallis, C.P. : Surgical treatment of the receding hair line. *Plast. Reconstr. Surg* , 44 : 271, 1969.
13. Vallis, C.P. : The strip graft method in hair transplantation, *J. Amer. Med. Women's Assoc.*, 24 : 890, 1969.
14. Vallis, C.P. : Hair transplantation for male pattern Baldness, *Surg. Clin. North Amer.*, 51 : 519-531, 1971.