

Use of Local Flaps in the Management of Recurrent Recto-Vaginal Fistula (With Imperforate Anus)

Malti Gupta* & Chandalia, B.S.**

RECURRENT rectovaginal fistulae are always difficult to manage and may ultimately require major operative procedures to achieve satisfactory healing of the repaired fistulae. We report here a simple, safe and short procedure used by us in a case of recurrent rectovaginal fistula (with imperforate anus).

A one and a half year old female child was admitted with us in January '75 with the history of congenital absence of the anal opening and passage of faeces through the vaginal opening since birth. The parents did not seek medical advice till the child was about 12 month old. Then the child was operated upon; an anal opening was made using the perineal approach and the rectovaginal fistula was repaired.

Sometime later the child started passing stools through vaginal opening again.

At the time of admission with us we observed that the child was passing most of the faeces through the vaginal opening and very little through the anal opening.

The anal opening was situated at a distance of approximately 1.5 cm from the vaginal opening and was very small in

diameter, even the *digiti minimi* could not be introduced. The intervening soft tissues appeared hypoplastic (fig. 1).

Solid putty masses were palpable, per abdomen, in the colonic region.

The child was underweight, under-nourished and under-developed.

The main problems requiring solution were analysed and grouped as follows :

- A. Recurrent Rectovaginal Fistula;
- B. Stenosed Anal Opening and
- C. Hypoplastic Perineal Soft Tissues.

In our opinion these could be solved by bringing in healthy vascular tissues to the site of fistula which was likely to be surrounded by lot of fibrous tissue in view of previous operation and probable inflammation in the past; any attempt at local procedures without a colonic bypass was unlikely to succeed.

We thought that chances of recurrence of fistula could be minimised if healthy tissue could be interposed between the site of repair and the anal wall.

The stenosed anal opening too demanded attention, requiring enlargement.

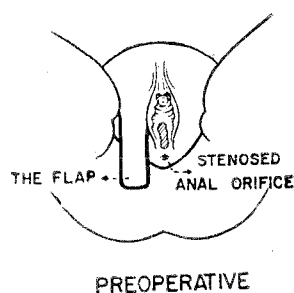
*Lecturer, Plastic Surgery, S. M. S. Medical College and Hospital, Jaipur.

**Reader, Gen. Surgery, S. M. S. Medical College and Hospital, Jaipur.

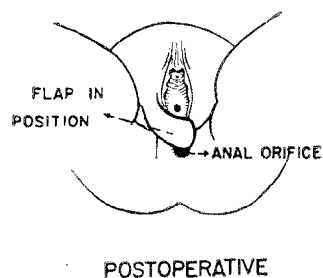
Regular dilatations had already failed in this case.

The interposition of such tissue would also increase the distance between the anal and the vaginal openings and add substance to the hypoplastic perineal tissues.

The best answer appeared to be a local transposition flap taken from paralabial region.



Under general anaesthesia, with the patient in lithotomy position, the posterior vaginal wall was mobilised from the anterior anorectal wall, the fistulous track was dissected and excised along with the surrounding fibrous tissue, and the posterior vaginal wall was repaired by direct approximation.



A superiorly based right paralabial flap was raised and transposed into the anterior anorectal wall so as to actually form a part of the anal canal (fig. 1 and 2).

The donor site was closed by direct approximation.

Post-operative period was uneventful. Sutures were removed on 10th post-operative day.

The patient has made a good progress. There has been no recurrence of fistula in the 18th month follow-up and no problem with defaecation. The anal opening is not patulous, sphincter control is normal.

Summary

We recommend local flaps in the management of recurrent rectovaginal fistula for following reasons :

- (i) The flap brings healthy vascular tissues to the site of fistula where lot of fibrosis is present following previous operations, thus healing of tissues is promoted.
- (ii) It reinforces the site of repair by being interposed posterior to the posterior vaginal wall.
- (iii) It enlarges the anal opening in cases with anal stenosis unresponsive to routine treatment.
- (iv) It brings additional skin between the anal and vaginal openings, thus maintaining them at normal distance in those cases where the openings are situated close together with very little, hypoplastic tissue in between.
- (v) The flap, unlike split skin graft, grows with the growth of the body,

so that chances of future stenosis and recurrence are nil. This is important particularly in children.

- (vi) The procedure is comparatively simple and safe, more so in the under nourished child, and makes major surgical procedures unnecessary.
- (v) The duration of hospital stay is

markedly curtailed and so is the economic burden of prolonged hospitalisation.

Acknowledgement

Authors are thankful to the Superintendent, S. M. S. Hospital, Jaipur for kindly granting permission to publish this article.