

## CONGENITAL DOUBLE LIP

Gupta, I. J.\* & Bhatnagar, S. K.\*\*

Congenital double lip occurs most frequently in the upper lip. Though the deformity presents at birth but it becomes evident after the eruption of permanent teeth.

### Embryology

In the foetus the mucosa of the lip is divided into two transverse zones ; an outer zone, which is smooth and similar to skin, the pars glabra, and an inner zone, which is villous and similar to the oral mucosa, the pars villous. Neustaetter (1895) and Warbrick, McIntyre and Fergusson (1952) believed that the furrows dividing the double lip represents an exaggerated boundary line between these two zones and the buccal portion a hypertrophy of the pars villosa.

### Case

We are reporting 3 cases of congenital double lip. All attended the out patient department of Plastic Surgery, K.G.'s. Medical College, Lucknow. The buccal folds were excised by a transverse elliptical excision

and the mucosa were undermined and stitched together. The histopathology in all the three cases reveal hypertrophy of the mucous glands.

### Discussion

Ascher (1920) described the condition so called double lip in a patient associated with blepharochalsis. Then Dorrance (1922) and Calnon (1952) reported nearly 15 cases. Guerrero-Santos and Altamirano (1967) reported 13 cases and believes that the deformity is not as uncommon as stated. They also advocated the Z-plasty for the excision of the buccal folds for the better results. But we think the transverse elliptical excision also give good results with less operative time and the operation can be performed under local anaesthesia.

### Summary

Report of 3 cases of congenital double lip with transverse elliptical excision of the buccal fold.

### Bibliography

1. Ascher, K. W. : Blepharochalsis mit straua and Doppellippe. *Klin. Monatsbl. Augenheilkd*, 95 : 86, 1029.
2. Calnon, J. : Congenital double lip : Record of a case with a note on the Embryology. *Br. J. Plastic Surg.* 5 : 197, 1952.
3. Dorrance, G. M. : Double lip. *Am. Surg.* 76 : 776, 1922.
4. Guerrero-Santos, J and Altamirano, J. T. : The use of Z-plasty for the correction of double lip deformity. *Plastic Reconstructive Surgery.* 39 : 478, 1967.
5. Neustaetter, O : Ueber den Lippensaun Beim Menscher, Seinan Bau, Seine Enwicklung Und Seine Bedeutung, *Hena Z, Naturwissen Sch.* 29 : 345, 1895.
6. Warbrick, J. G., McIntyre, J. R. and Fergusson, A. G. : Remarks on the aetiology of Congenital bilateral fistulae of the lower lip, *Br. J. Plastic Surg.*, 4 : 254, 1952.

---

\*Registrar

\*\*Lecturer

Postgraduate Department of Plastic Surgery, K.G.'s. Medical College, Lucknow-226003.



Fig. 1

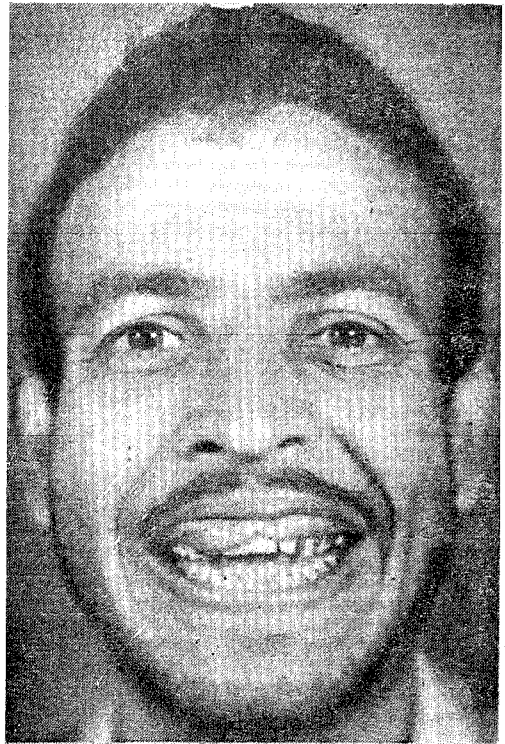


Fig. 2