

## UNCOMMON MANIFESTATIONS OF FILARIASIS

V. Bhattacharya,\* M.S., M.Ch. (Plastic)      J. K. Sinha\*\* M.S., (Plastic) F.R.C.S. and  
F. M. Tripathi\*\*\* M.S., M.Ch. (Plastic)

Lymphoedema and elephantiasis of the lower limb, scrotum and penis constitute some of the usual surgical manifestation of filariasis which is of frequent occurrence in the tropics. These constitute major disability requiring surgical correction (Bulkley, 1962). Sometime scrotal enlargement may attain huge proportions and present major problem in reconstruction after excision. *Lymphoedema* and massive enlargement of breast, vulva, thigh and sole are affected to a much lesser degree. The following case histories are presented to illustrate these unusual manifestations.

### Case 1

A 50 year old man presented with lymphoedema of the right lower limb extending into thigh after having undergone total excision of the scrotum with implantation of both the testes in the thigh about 7 years ago (Fig. 1). Subsequent to this operation he remained symptom free. About 2½ years back he had a fresh attack of fever, rigor, inguinal lymphadenitis followed by oedema of the affected leg. Since then he has had several such attacks with progressive worsening of the oedema of the right lower limb (Fig. 2). This patient appeared to be more concerned regarding oedema which had now appeared in the skin of the thigh around the implanted testes of the right limb.

Local examination revealed well formed pouch in both the thighs. On the right side the whole of the lower limb was swollen,

other limb being normal. The oedema was nonpitting. Ulcerations and exematous changes were found over the skin. The site of implantation revealed stretching, oedema and thickening of the skin and subcutaneous tissue on the affected side. *Peu-de-orange* was present. Interestingly these changes were much pronounced surrounding the site of implantation of the testes. The patient was reluctant to undergo any further surgery.

### Case 2

A 40 years old female presented with history of recurrent attacks of fever, rigor and lymphadenitis with progressive enlargement of the breasts, vulva and one of her legs. The breasts used to become tender and painful in each episode.

On examination both the breasts appeared to be hypertrophied and pendulous (Fig. 3). Skin involvement was minimal, areola was stretched. Both breasts were finely nodular and no lump could be felt. She complained of pain and drooping of both the shoulders.

Examination of the vulva revealed moderate enlargement of both *labia majoras* accompanied with small multiple warty growths (Fig. 4). *Labia minora* was unaffected. There was pitting oedema over the left leg.

Breast reduction by Strombeck's technique and partial vulvectomy was carried out. For the leg, conservative management was advised.

Since her surgery, patient has remained symptom free.

\*Lecturer

\*\*Professor Head

\*\*\*Reader

**Case 3**

A 45 years male presented with the history of recurrent attacks of fever with rigor for 6 years. After 4 months of the initial attack he noticed mild swelling of his left lower limb which used to get reduced by elevation. Subsequently with each attack the swelling started progressively increasing. Later on scrotum followed by penis was affected in the same process.

The swelling of the left lower limb was more prominent below the knee and showed usual skin changes of advanced lymphoedema. Interestingly, the left sole was markedly affected. The dimension of it was larger in length, breadth and width. The normal arches of the foot were apparently absent and the foot looked flat. The skin was thick and there were warty growths at the distal half except at the pressure points (Fig. 5).

The scrotum and penis was also involved with left inguinal lymphadenopathy.

**Discussion**

Primary and secondary lymphoedema involving the breast, vulva, thigh and sole is infrequent. Since there is no known medical remedy by which elephantiasis can be reversed (Khanna, 1970), so surgery remains the main modality that can offer relief. Complete excision of the diseased tissue is the surgical treatment of elephantiasis as described by others (Gelbke, 1954 ; Farina et al., 1958 ; Kirschner, 1958, quoted by Prpic, I, 1966). This procedure certainly offers the quickest solution to the problem. Other types of surgery directed to restoration of lymphatic drainage lead to a higher percentage of failure, according to statistics in the literature (Bulkley, 1962).

For the scrotal elephantiasis it is best to fashion the scrotum and cover the testes with

the remainder of the skin of the scrotal neck (Müller and Jordan, 1933 ; quoted by Prpic, I, 1966) as the skin of the posterior aspect of the scrotum usually remains relatively normal. If necessary a rotation flap from the skin of the thigh may be used (Berger, 1957 ; quoted by Prpic, I, 1966). In the past one of the methods consisted of fixing the two testicles together and covering the denuded testicles with free skin graft (Baxter et al., 1949 ; Balakrishnan, 1956). This method was criticised by Prpic (1966) because a changed thermic regulation is apt to interfere with the function of the testicles. Apart from using the skin of the scrotal neck most of these reconstructive methods, mentioned above have been criticised by one author or the other due to their inability to substitute the function of dartos muscle and maintain optimum temperature for proper spermatogenesis. Still they are advantageous as compared to thigh implantation because they satisfy the cosmetic, psychological and emotional aspects of the problem. Therefore, putting the testes under the skin of the thigh as was done in case 1, is unnecessary (Owens, 1942 ; Bruner, 1950 ; May, 1950). By doing this we also avoid the associated complication as happened in this case.

For the treatment of other organs the principle of treatment remained the same. The second case had functional as well as psychological problem due to enlarged breasts and vulva. Reduction mamaplasty by Strombeck's technique and partial vulvectomy was done. The patient responded very well. She is being followed-up regularly.

Although the lower limb is one of the frequent site of involvement, the sole is usually spared. This is perhaps due to difficulty in accumulation of fluid because the fibrous

septa anchors the skin to the underlying planter aponeurosis and divides the tissue into small loculi which were filled with a rather fluid fat under tension. Moreover, during walking the fluid is being continuously forced out by the muscular contractions. Our third case and few more cases showed marked involvement of the sole with warty changes over the skin. This problem is difficult to handle and there is no standard surgical treatment.

#### Summary :

We present in this paper some of the unusual manifestations of filariasis. Surgery remains the sole modality of treatment along with conservative measures.

The skin of the scrotal neck and, if necessary, the skin flap from the thigh, are the best means to reconstruct the scrotum and cover the testes.

#### References

1. Balakrishnan, G. : Scrotal avulsion : A new technique of reconstruction by split skin graft. *Brit. J. Plast. Surg.* 9 : 38, 1956.
2. Baxter, H., Hoffman, M., Kiwit, E., and Stern, K. : Complete avulsion of the skin of the penis and scrotum : surgical, endocrinological and psychological treatment. *Plast. Reconstr. Surg.*, 4 : 508, 1949.
3. Bruner, J. M. : Traumatic avulsion of the skin of the external male genitalia. *Plast. Reconstr. Surg.* 6 : 334, 1950.
4. Bulkley, G. J. : Scrotal and Penile lymphedema. *J. Urol.*, 87 : 422, 1962.
5. Gelbke, H. : *Zbl. Chir.*, 79: 935, 1954.—(1957) *Trans. Int. Soc. Plast. Surg.*, First Congress, 1955, Baltimore : Williams and Wilkins.
6. Khanna, N. N. : Surgical treatment of elephantiasis of male genitalia. *Plast. Reconstr. Surg.* 46 : 481, 1970.
7. Lorne-Brown, W., and John, E. Woods : Lymphedema of the penis. *Plast. Reconstr. Surg.*, 59: 68, 1977.
8. May, H. : Reconstruction of scrotum and skin of the penis. *Plast. Reconstr. Surg.*, 134, 1950.
9. Owens, N. : Reconstruction for traumatic denudation of the penis and scrotum. *Surgery*, 12 : 88, 1942.
10. Prpic, I : Severe elephantiasis of penis and scrotum. *Brit. J. Plast. Surg.*, 19 : 173, 1966.

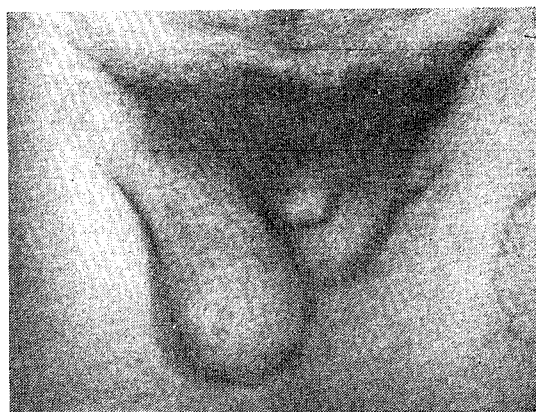


Fig. 1. Skin around the implanted testis on the right side showed stretching, thickening, oedema and peau-de-orange.

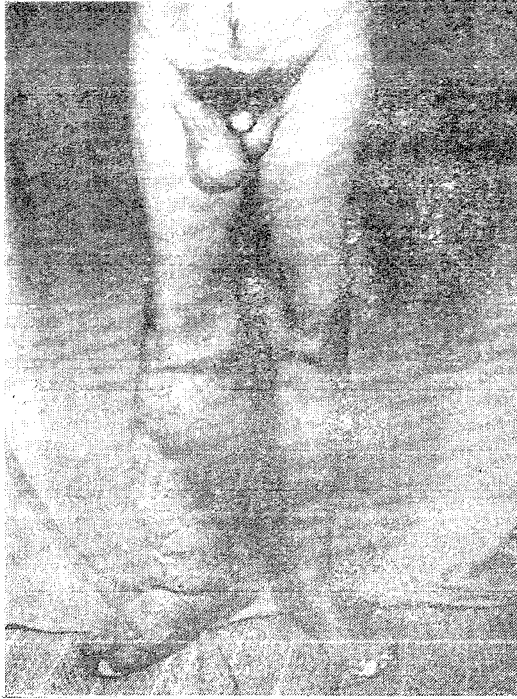

Fig. 2. Showing lymphoedema of the right lower limb.

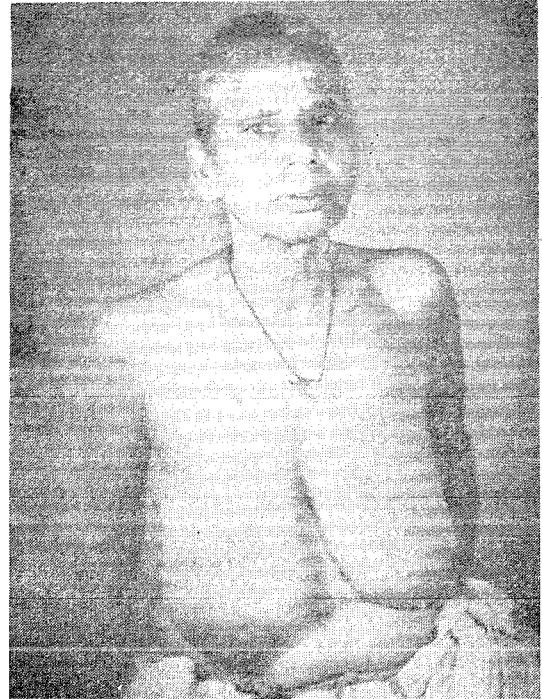

Fig. 3. Bilateral enlargement of the breasts.

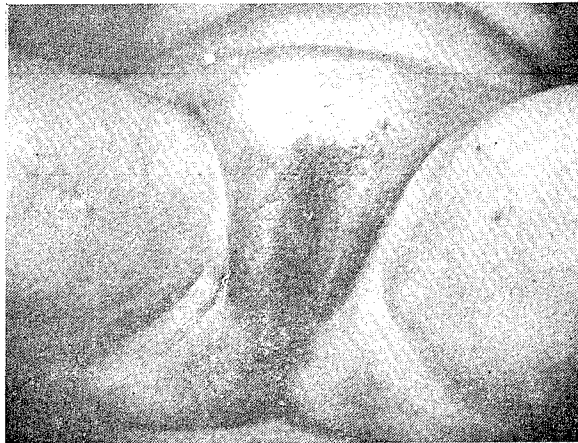


Fig. 4. Filarial involvement of the *labia majores*.

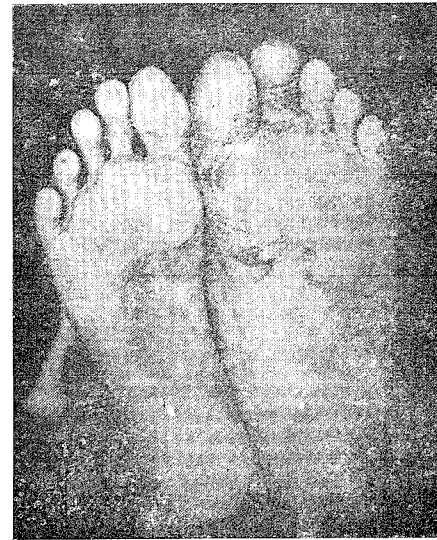


Fig. 5. Marked hypertrophy of the left sole associated with skin changes.