

MICROSURGERY—INTRODUCTION AND BASIC TECHNIQUE

Dr. Govila. A., MS. M. Ch ,

Evolution

Like any other art surgery and the surgeon is in the process of evolution. Ever improving understanding of the wound healing repair and regeneration dictated more respect to the tissue by way of increasingly delicate tissue handling by surgeons of past ages. Presence of rough surgeons in the pre-war period gave birth to plastic surgeons and the wars secured a defined role for the plastic surgeons.

Evolution continued among plastic surgeons. Need was expressed to visualise the areas where no man has ever gone before and to operate on those structures which are not sufficiently visible by the naked eye, at least not good enough to operate. Means of magnification were then sought and means of repair by way of fine suture and fine instruments were then evolved. Process of perfection and dexterity continued.

The art of operating through optical magnification is called microsurgery. The arbitrary limit between vascular surgery and microvascular surgery is probably three millimeters. as the outer diameter of the vessel. An operating microscope is an ordinary compound microscope with greater working distance (about 10 inches) between object and the lens system and lesser magnification.

History

The history before 1960 is not very clear little controversial. The history of microm-

agnification, microinstrumentation and micro-technique went hand in hand. Zacharia Jensen invented compound microscope in 1590. For many centuries it was used by microbiologist, histologist and pathologist. Its use started late after its invention by surgeons, such as E. N. T. and Ophthalmologists. In 1921 Carlolof-Nylen¹ in Sweden as an E. N. T. surgeon used it on a case of chronic otitis media and few cases of pseudo-fistula symptoms. The first surgeons to perform and write about it were Jacobson². and Saurex who in 1960 performed a successful anastomosis in 8mm size vessel. The initial difficulty was felt about the suture material and micor-instrumentation ane so about the micro-technique of anastomosis. Therefore methods were evolved of non-suture anastomosis such as ANDrosove's³ Mechanical stapler (1956), use of chemical adhesive agents (Bernhard,⁴ carton,⁵ Jacobson,⁶ man-nax),⁷ use of electro-coagulation technique (Siegel et^{8,9,10}. all) 1960, Nakayama¹¹. ring pin stapling technique 1962 and Laser beams^{12,13}. in 1965-67 but none of them seems to stand the test of time. In 1963 Kleinert^{14,15} and Kasden performed successful revascularisation of partially severed non viable digit. First successful replantation was performed by Malt¹⁶(1964). A hand was then replanted in 1964 by Horn.^{17,18} In experimental animal Bunke and Schulz¹⁹ in 1965 perfo rmed replantation and in the same year Kri-zek²⁰ performed composite tissue transfer. In 1972 Mclean and Buncke²¹ transferred

*Regional Plastic and Reconstructive Surgery unit Shotely Bridge Hospital Consett. U. K.

composite tissue in clinical situation using omentum. 1973 was the year when work was reported from all over the world by various plastic surgeons such as Daniel and Taylor, Oibrian from Australia, Harii and Ohomri from Japan.

How to Begin :

The question, how to begin, becomes more pertinent with under facilitated countries. Preclinical practice for about a year is essential before embarking on a clinical case. A beginner need not have elaborate experimental or surgical facilities. All that is needed is a pair of 2x or 3.6x magnification loupes, two jewellers forceps and one Iris scissors. Initial practice could be started by practising stitching cut on a thin stretched rubber such as a balloon or a surgical glove stretched on an empty culture dish. The next step is to acquire human or nonhuman tissue having small size vessels, such as amputated parts from operating theatre or fresh cadaveric chicken (Govila A²² 1980/ Fig. I.); or even human placenta (Mcgragor²³ J. 1980), and to dissect vessels of 1-2mm size vessels, transect them and practice anastomosis. The patency of anastomosis in such a situation is checked by irrigating the vessel by a coloured ink from the other end. A small amount of leak is normal. Alternatively the vessel could be longitudinally and examined from inside for quality of stitches. In cadaveric chicken the ideal vessel to practice on is the common carotid artery easily found in the base of the neck at the thoracic inlet. This area provides vessels of 5 to 3mm size for practice/ (Fig. 2). This vessel is identical in size with that of common digital artery in the human hand. This could be performed in any room under ordinary light conditions. If facilities for laboratory work could be procured such

as licence and funds then rats' or rabbits' femoral vessels are even better substitute.

However it must be emphasised that anastomosis under such laboratory conditions are totally different from anastomosing in a clinical situation. The difficulties of clinical situation such as identification, dissection and mobilisation of the vessel without producing perforations by damaging unseen minor arteriols or venules from the posterior surface of the vessels, working in a cavity, difficulties of differential focus because of poor depth of field with increased magnification, and obstruction of operating field by tissues more proximally placed in the cavity, and working through various fixation devices such as Hoffman's frame when working on the lower limb, importance of clinical judgment and delay of time in thrombotic obstruction of circulation through anastomosis, difficulties of constant irrigation and mopping away fluids appearing in the field and obstructing it, and many times working through partially damaged vessels, plus the factor of shear physical exhaustion after prolonged periods of operating time producing inevitably tremors and irritability and perhaps also the responsibility of keeping the interest alive among the members of the team who can not see what is going on and gradually succumb to less active participation and monotony are soon realised. Although execution is technically demanding the correct decision and painstaking pre-operative planning share equally in dictating the final results.

Equipment

1. Magnification system.
2. Micro instruments.
3. Micro sutures.



Fig. 1. Anastomosis in progress shown through microscope, in a 1 mm size vessel. Note first stitch on the posterior wall. For the clarity of the pictures a small segment of the posterior wall is left intact.

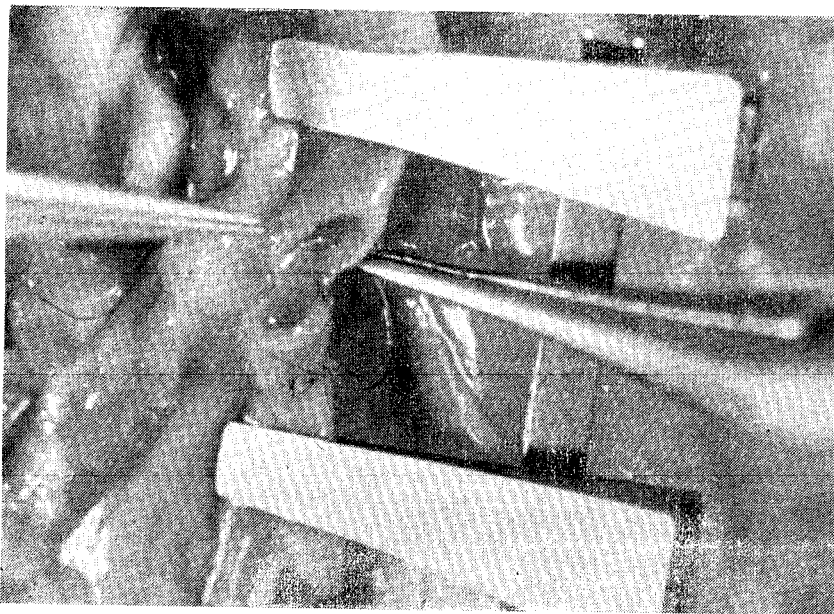


Fig. 2. Showing site for second stitch (could be on any side). Note one completed anastomosis.

1. *Magnification System :*

Endless sophisticated devices are now available in most of the countries. It is essential to have 2x or 3.6 loup magnification for initial dissection. Keelers from Great Britain make small bulky and cheaper loup

which have adjustable interpupillary distances as compared to Zeiss which are small, light and are more expensive. Magnifying prismatic telescopic loup up to 8x magnification are now available, but their clinical applications seem to be limited at present. Perfectly

satisfactory work could be done by any cheaper type of microscope such as one from Poland giving magnification up to 20 times, but in complicated situations all the available facilities such as in a Carl Zeiss opmi 7 P/H seems mandatory. This gives control of most of the systems by foot, and a horizontal movement of lens system. A chair specially designed for microsurgery is also helpful if available. In under privileged countries a table mounted microscope or a portable microscope with an ordinary stool could do the same job as the more sophisticated methods used in a developed country. Some of the addresses of the suppliers are given.

Loups

- | | |
|--|---|
| 1. Design for Vision Inc.
40 East 21st Street,
New York.
NY 10010. | 2. Keeler,
456, Parkway,
Brooklyn,
U.S A |
| 3. Neitz Binocular Loups,
Metro Trading Co. Ltd.
Inugaki Building,
24-5, Asakusabashi, 1 Chome,
Taito-Ku
Tokyo, Japan | |

Operating Microscope

- | | |
|--|---|
| 1. Carl Zeiss,
444, Fifth Avenue,
New York
NY 10018 | 2. Edward Weck &
Co. Ltd.
49-33, 31st Place,
Long Island City,
New York
NY 11101 |
|--|---|

Microinstruments

Same results could be achieved by a set as small as one needle holder, one pair of scissors, one straight and one curved forceps and one pair of microclamps, as by a set having more instruments such as vessel dilator, clamp approximator, clamp applying forceps,

bipolar microcoagulator, microsuction, absorbed applicator stick and assorted coloured background material. There are endless manufacturers supplying these instruments. All these instruments need personal care and attention when stored.

In designing and selection of these instruments the following points should be considered. (1) A pen grip is ideal, (2) Length of the instrument should be such that it rests perfectly on the first web space without falling short or projecting too long. (3) No locking or unlocking devices are incorporated. (4) A mat finish to avoid light reflection and eye strain. (5) A light and strong metal which could stand the effect of time.

Microsuction devices do not work satisfactorily. A bipolar microcoagulator is a help and shortens the operating time. A microclamp exerts 30 to 50 gms of closing pressure on the vessel wall.

Some addresses of the manufactures are as follows :—

- | | |
|---|---|
| 1. Sparta Instrument
Corporation, 305,
Fairfield Ave. Fair-
field, N. J. 07006
U. S. A. | 2. Storz Instrument
Company, 3365,
Tree Court Indus-
trial Bldg. St.
Louis MO 63122
U. S. A. |
|---|---|

Microsuture :

Ethicon Laboratories provide 8 to 11/0 nylon suture. 10/0 is ideal for vessel anastomosis.

Anaesthesia :

Experienced Anaesthetist is required to provide long anaesthesia up to ten hours in complicated cases. A free flap in routine takes about five hours.

Technique :

(1) Microvascular (2) Microneural (3) Microlymphatic (4) Microtubular

Microvascular

An anastomosis could be end to side or side or end to end. End to side is preferred at most centres as it has the following advantages : —

1. Size disparity is easily matched.
2. Vessel spasm has less effect on the caliber of anastomosis and even with little spasm the anastomosis patent.

Different surgeons follow different techniques. I perform anastomosis as follows :— Two cut ends of vessel are placed close together in the most comfortable, straight, tension free position, and in such a way that the vessel axis is in 7 to 10 o'clock position in the operating field, by placing them in the approximating microclamps and by passing a holding stitch between perivascular tissues and the surrounding fat in the desired position using 4 magnifying loupes. At this stage the loupes are taken off and the operating microscope is brought in the field. Course positioning of the microscope is done using the same gloves taking care about the height of the stool or the chair, and the position of the hands. Entire arm from the elbow to the wrist should rest in a plain horizontal position without too much pressure or too little contact with the table. Most of the movements are on the wrist and fingers, little on the elbow and minimal at the shoulder. Comfortable position of the neck is important, too much forward, backward or position of the head needing constant active effort is soon tiresome. Now the gloves are discarded and a fresh pair is put on. Sterilised plastic caps are mounted on the adjusting screws of the microscope and final adjustment is performed.

The field of operation is irrigated by ordinary 10cc syringe with a thin needle by no-

rmal saline to remove blood or any other fluid which obstruct the proper vision. Vessel handling is kept to a minimum. I do not strip a cuff of adventitia as I do not think it makes any substantial difference. Any loose tags of adventitia which are popping in to the lumen of the vessel could be a nidus for thrombosis, and so I remove them.

I do not put any guide stitches as described by some workers. I put the starting stitch at the centre of the posterior wall (Fig. 3 to 9) Then a stitch is put on either side of it and this sequence of stitching is carried on until the entire posterior wall is stitched and then stitching is completed on the anterior wall from one end to the other. The width and the spacing of the stitch is roughly the same as the thickness of the vessel wall. Arteries being thicker walled need less stitches than veins which are thin walled. Usually 1mm size vessel needs about 9 stitches and 2mm size vessel needs 14 stitches. Distal clamp is removed first then the proximal. Small leaks for a few minutes is normal, and leak in the form of a jet needs another stitch in that position, which could be put without reapplication of microclamp. Mechanical dilatation of the vessel is sometimes the cause for the spasm and should be avoided. If a vein graft goes in the spasm as it most often does it is best solved by closing it at one end and then ballooning it by normal saline from the other end by a syringe with pressures as high as possible manually. This perhaps damages the media so badly that it loses its properties to contract. This should be performed when the graft has not been anastomosed. No chemical method to overcome the vessel spasm has been satisfactory. End to side anastomosis is performed in a similar fashion. A hole which is bigger is preferred than one which is smaller.

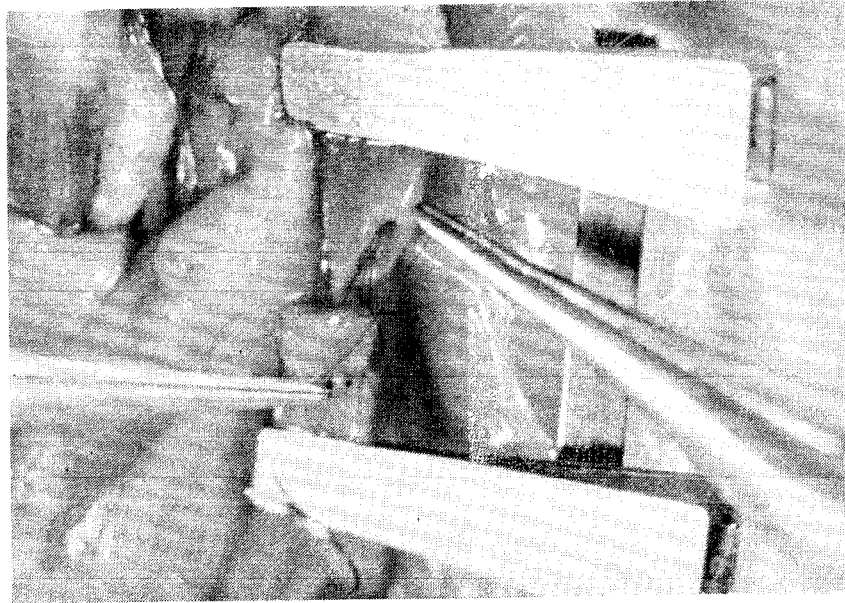


Fig. 3. Showing a loup of thread around the needle holder and making of a knott.

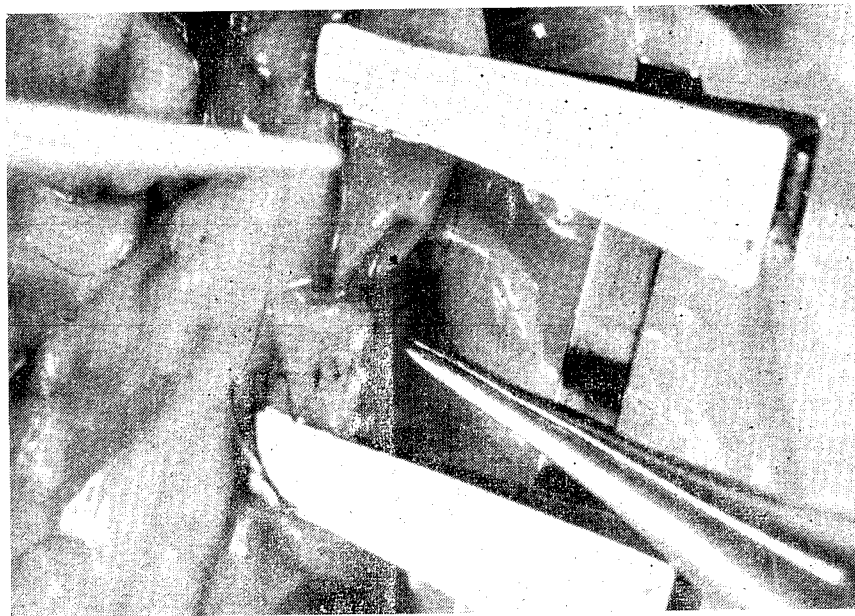


Fig. 4. Showing use of double throws in the first loup, subsiquent lous are single throws.




Fig. 5. Showing bite in the anterior wall.

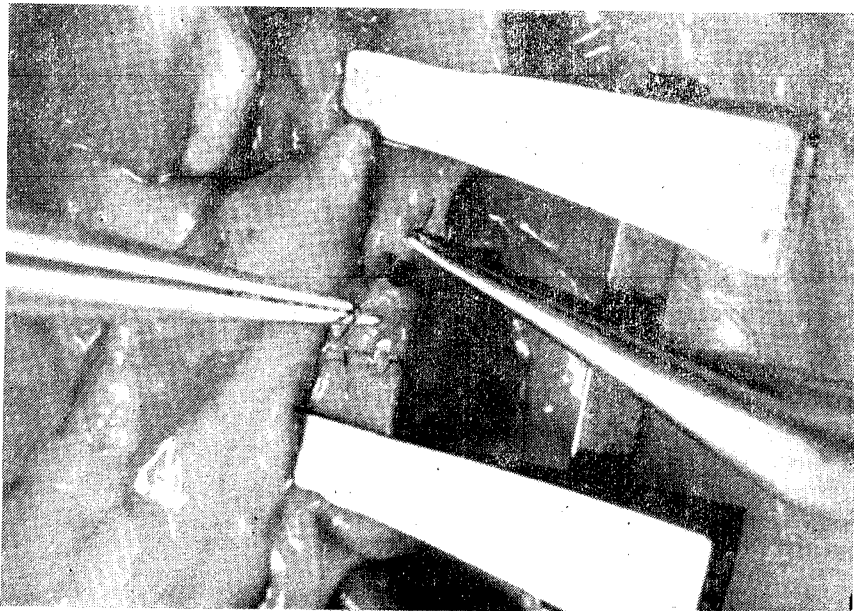


Fig. 6. Showing bite completed in the anterior wall.

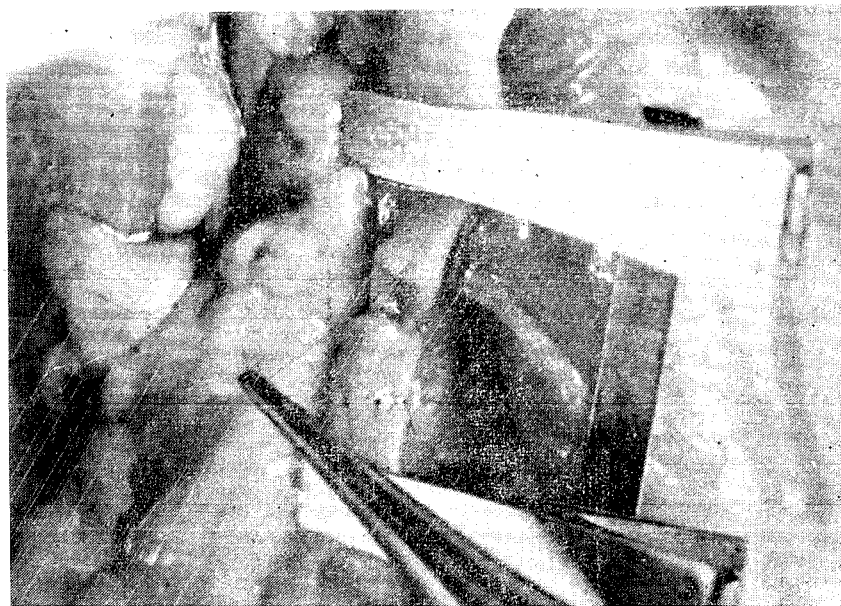


Fig. 7. Showing making of the knott in progress.

Continuous sutures are to be condemned in any situation by a beginner. It becomes essential to stitch the posterior wall first in this situation as vessels can not be turned ones the anterior wall is anastomosed.

Microneural :—

Various techniques are used, such as (1) Epineural Repair (2) Perineural Repair. (3) Epi Perineural Repair. (4) Fascicular Repair. (5) Fascicular Group Repair and (6) Nerve Wrapping.

The heart of the problem is the proper matching. The knowledge of microanatomy of the nerve is of very little practical help. The more nerve dissected into fascicles more the chances are lost of proper alignment.

When a nerve is viewed through microscope it seems to have one outer sheath termed as epineurium, which wraps longitudinally placed cords called fascicles. These cords are in groups of various sizes. The same material which forms the epineurium seems to fill the

rest of the space between fascicles holding them in place.

Comparable results of different techniques by one surgeon has not been reported. Micro repair improves the result by 30% as compared to repair without magnification.

The most practical way of repair seems to be epiperineural. The needle is passed in the epineurium including the perineurium of the underlying fascicle, similar bite is taken on the other matching end of the nerve and the knot is tightened. Initial stitches could be by 8/0 nylon which has a greater strength to hold the ends together.

In a secondary repair excision of fibrous end is the most important part.

Microlymphatic

Lymphaticovenous anastomosis in obstructive secondary lymphoedema is technically possible. Long term results of the patency are encouraging. Identification and the mobilisation of the lymphatic vassd is difficult,

Injection of 2.5% patent blue in the foot colours the lymphatic vessels up to the groin. Through the vertical incision in the groin dissection under 4 X magnification is carried around and between femoral vessels. Widest available trunk is used. Similar size vein in the vicinity in the dissected clamps is applied only to the vein, and is cut. Lymphatic vessel is also cut the anastomosis is performed end to end. Suture is passed in the vein wall first and then through the lymphatics. Number of stitches depends on the size of the vessel. When the clamp is initially removed a back-flow is seen in the lymphatic vessel from the vein for 2 to 3mms. This disappears on the massage of the limb. Patency rates of 74% and 90% (Yamada) has been demonstrated.

Microtubular

Microsurgical technique has been applied in the reconstruction of the fallopian tubes,

vas deferens, traumatic penile amputation and intestinal transfers.

Fallopian Tubes

8/0 to 10/0 nylon is used, several interrupted stitches are passed through the full thickness of the vessel wall. Rotation of the clamps by 180° facilitates stitching of the posterior wall.

Vas Deferens

It is repaired in two layers. First layer repairs the lumen only and the second layer repairs the outer wall. This technique can be used for the fallopian tubes. Lumen to lumen continuity is better maintained by this technique.

Penile replantation and the intestinal transfer utilises basic techniques of microsurgery for the anastomosis of the vessel of the grafted segment. The rest of the method uses general principals of surgery.

References

1. Nylen, C-O The microscope in aural surgery, its first use and later development. *Acta Otolaryngology Supplement* 116, 226-240, (1954).
2. Jacobson, J. H., and Saurez E. L., Microsurgery in anastomosis of small vessels. *Surgical Forum*, 11, 243-245 (1960)
3. Androsov, P. I., New method of surgical treatment of blood vessel lesions *A. M. A. Arch. Surgery*, 73 : 902, (1956)
4. Bernhard, W. F., Cummin, A. S., Utilizing a new flexible adhesive. *Surg. Forum*. 13 : 281, (1962)
5. Carton, C. A., Kesster, L. A., Seidenberg, B., and Hurwitt, E. S. Experimental studies in the surgery of small blood vessels. IV Non suture anasomosis of arteries and veins, using flanged ring prosthesis and plastic adhesive. *Surg. Forum*. 11 : 238. (1960)
6. Jacobson, J. H., Moody, R. A., Kusserow, B. K., Reich, T., and Wang, M. C. H. The tissue response to a plastic adhesive used in combination with microsurgical technique in reconstruction of small arteries. *Surgery* 60 : 379, (1966)

7. Mannax, W. G., Blach, J. H., Longbeam, L. K., and Lillehei, R. Plastic adhesive as an adjunct in suture anastomosis of small blood vessels. *Surgery* 54 : 663, (1963)
8. Sigel, B., and Acevedo, F. J. Vein anastomosis by electrocoaptive union. *Surgery Forum*. 13 : 233 (1962).
9. Sigel, B., and Acevedo, F. J. Electrocoaptive union of Blood vessels. A preliminary experimental study. *J. Surg. Res.* 3 : 90, (1960).
10. Sigel, B., and Dunn, M. R. The mechanism of blood vessel closure by high frequency electro coagulation. *Surg. Gynecol. Obstet.* 121 : 823, (1965).
11. Nakayama, K., Tamiya, T., Yamamoto, K. and Akimoto, S. A simple new apparatus for small vessel anastomosis. (Free autograft of the sigmoid included) *Surgery* 52 : 818, (1962).
12. Strully, K. J., and Yahr, W. Z. Laser theory and biomedical application in R. M. P. Donaghy and M. G. Yasegil (eds), *Micro-vascular surgery* Stuttgart : Thieme, 1967, Thieme, 1967, pp 130-134.
13. Strully, K. J. and Yahr, W. Z., The effect of laser on blood vessel wall : A method of nonocclusive vascular anastomosis. In R. M. P. Donaghy and M. G. Yasargil (eds.). *Microvascular Surgery*. Stuttgart : Thieme, 1967, pp. 135-138.
14. Kleinert, H. E., and Kasdan, M. L. Salvage of devascularized upper extremities including studies on small vessel anastomosis. *Clin. Orthop.* 29 : 29, 1963.
15. Kleinert, H. E., and Kasdan, M. L., and Romero, L. L. Small blood vessel anastomosis for salvage of severely injured upper extremity. *J. Bone Joint Surg.* 45 : 788, (1963).
16. Matt, R. A., and McKhann, C. Replantation of severed arm. *Journal of American Medical Association*, 189, 716-722, (1964).
17. Horn, J. S. Successful reattachment of a completely severed forearm, a commentary. *Lancet*, C, 1152-1154, (1964).
18. Horn, J. S. The reattachment of severed extremities. In *Recent Advances in Orthopaedics*, ed. Apley, A. G. pp47 London : Churchill. (1969).
19. Buncke H. J., and Schulz, W. P. Total ear replantation in the rabbit utilizing microminiature vascular anastomosis. *Br. J. P. Surg.* 10, 15, (1966).
20. Krizek, T. J. Tani, T., Des Prez, J. D., and Kiell, C. L. Experimental transplantation of composite graft by microsurgical anastomosis. *Plast. Recon. Surg.* 36 : 538, (1965).
21. McLeam, D. H., and Buncke, H. J. Autotransplant of omentum to a large scalp defect, with microsurgical revascularization. *Plast. Recon. Surg.* 49 : 268, 1972.

22. Govila. A., A simple model to learn and practice microsurgery—A cadaveric chicken, Under publication in Br. J. Pl. Surg.
23. Mcgragor. J., A model to practice microsurgery—The Human placenta, presented in the summer meeting of Br. Association of Plastic Surgeons in 1980.

Recommended Books for Further Reading.

- I. O'Brien, B. McC. Microvascular Reconstructive Surgery. Edinburgh : Churchill livingstone, (1977).
- II. Daniel, R. K. and Terzis, J. K. (Eds) Reconstructive Microsurgery. Boston : Little, Brown, (1977).