

# TREATMENT OF POST BURN CONTRACTURE NECK BY LONG LATERAL THORACO-ABDOMINAL TUBE PEDICLE GRAFT WITH WRIST AS CARRIER

(Review of literature with a case report)

\*P. L. Bafna, M.S.

\*\*J. K. Yadav, M.S.

\*\*\*N. K. Jain, M.S.

The treatment of extensive post burn contracture of neck consist of excising the scar tissue, opening the neck and covering the raw surface either by split thickness or whole thickness skin graft. The split thickness grafts are invariably taken from the thigh. The whole thickness skin grafts can be provided by direct transposition from the back or the chest either with or without delaying. The jump flap technique (Bridge graft) has also been utilized where the skin of chest and abdomen is not involved in the burn scar. The whole thickness skin can also be provided by raising the tube and transferring them to the neck either by waltzing or with the help of carrier. In case of neck wrist has often been used as a carrier.

## Case Report

A 35 years old man was admitted in M.G. Hospital, Jodhpur with extensive burns involving face, ears, scalp, neck, chest and abdomen. With adequate management he could be revived but later developed extensive contracture neck to the extent that the chin was adherent to the sternum. The tube pedicle technique was applied with wrist as carrier in stages to correct the contracture.

Management of the case was done with long lateral thoraco abdominal tube with wrist as carrier and transferred to neck in 4 stages.

## Stage I

A 18 inches long tube was made extending from the left axilla to the symphysis pubis with the left forearm as a carrier. The raw area was covered by a thiersch graft (Photograph-I).

## Stage II

After 3 weeks the lower end by the tube which was near to the pubis was cut and brought above right shoulder and was stiched there.

## Stage III

Axillary end of tube is detached from the base and brought to the raw area of the neck which was created after the excision of the scar. This end was stitched to the raw area extending from the left side of the neck to the centre of the neck. The carrier left arm is released (Photograph II).

## Stage IV

The lower end is released from the chest and the chin was reconstructed.

## Stage V

After 3 weeks the remaining of tube was spread after excision of the scar of neck and thus whole of neck was reconstructed.

The end result was satisfactory. The texture and strength of the skin was appreciable good and could withstand surgical trauma if needed (Photograph III).

---

\*Reader in Surgery, Dr. S. N. Medical College, Jodhpur.

\*\*Lecturer in Surgery, Dr. S. N. Medical College, Jodhpur.

\*\*\*Civil Assistant Surgeon, Sojat Hospital, Rajasthan

### Discussion

Cronin (1961, 1964) recommended split thickness graft as most modern method of treatment for severe post burn contracture. The method is simple and least time consuming and needs constant use of splints to keep the neck in extended position for 6 months.

Our rustic patients donot realize the importance of wearing splints for six months continuously and often come back with recurrence of contractures. Other disadvantages are that the skin is not durable and cannot withstand trauma. We have also tried this method and at times had disappointing results.

The contractures of neck are invariably associated with burns of chest and the back and to raise local flaps donot provide healthy skin. Moreover it is not possible to get sufficient base for such a long flap.

Converse (1948, 1951), Edwards (1948), Longrace (1964) have preferred jump flap technique either from thorax or abdomen. They consider it to be simple and can be applied confidently in any district hospital. The main disadvantage with this technique is that healthy skin for jump graft may not be available. The donor site may give an ugly site. The flap may be difficult to raise from chest in females due to the presence of breasts. Besides this the central part of flap may undergo gangrenous changes as two bases are inadequate in nourishing it.

The lateral abdomino-thoracic tube pedicle has several advantages. The skin of chest and abdomen on the lateral side is usually not burnt because at the time of burn upper extremities protect this area. Moreover, the donor area remains hidden under the upper extremities and does not give a poor cosmetic appearance. The gangrenous changes

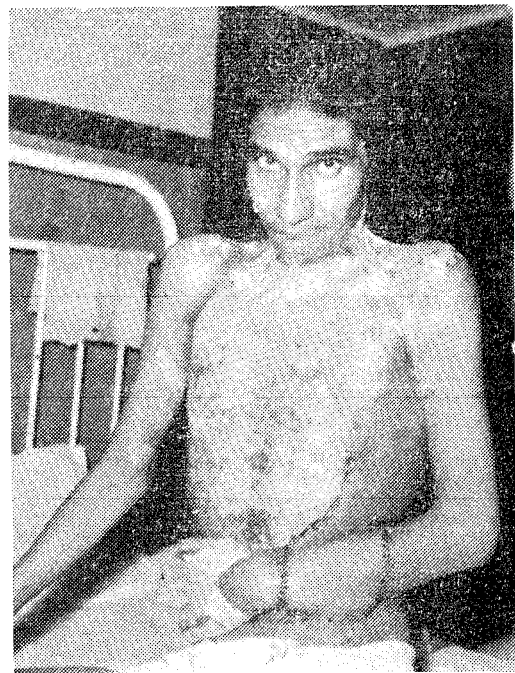
in tube pedicle graft usually do not occur when forearm is being used as the carrier.

The procedure needs no splinting and can be performed at district level with minimal facilities. At times pubic hair can be used for growing beard as in the reported case.

The procedure might be of special interest in middle east countries and Muslims of India where they are keen to grow a beard, pubic hair can be utilized for the same and the chin could also be reconstructed.

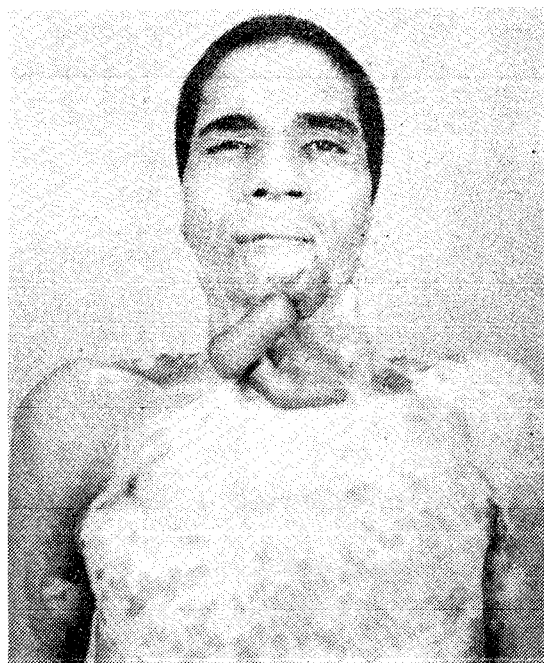
### Summary

Lateral abdomino thoracic tube pedicle can be a procedure of choice in certain cases with good results under certain conditions. However the operation has to be done in several stages.



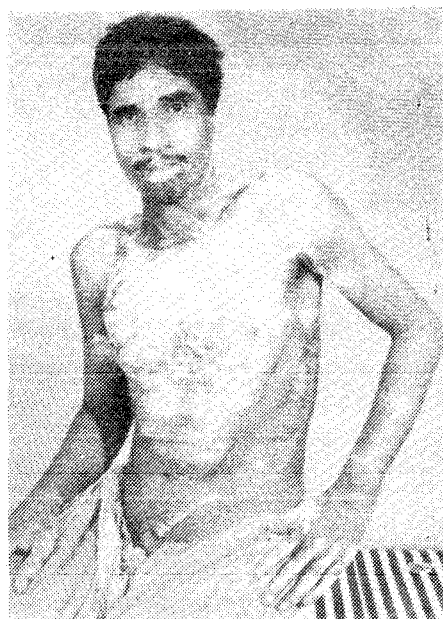
*Photograph 1 :*

Showing the extensiveness of post burn neck contracture. The bridge graft has also been raised in the left Lumber region and taken on the left wrist.



*Photograph II :*

The axillary and of the tube has been fixed to the neck and pubic end has been utilised to reconstruct the chin.



*Photograph III :*

The end result after the reconstruction of chin and neck.

#### REFERENCES

- Cronin, T. D. ; The use of a molded splint to prevent contracture after split skin grafting on the neck. *Plastic and Reconstructive Surgery*, 27,; 7-18, 1961.
- Cronin, T. D. ; Deformities of cervical region. In ; *Reconstructive Plastic Surgery*, ed. Converse, J. M. Vol. 3, ; 1175 Philadelphia Saunders, 1964.
- Converse, J. M. ; *Reconstructive Plastic Surgery*, Vol. 4, ; 1181, Philadelphia Saunders.
- Eswards, S. ; Evaluation of openjump flap for lower extremity soft tissue repair. *Annals of Surgery* 128, 1131-1135, 1948.
- Longrace, J. J. ; Deformities of the forehead scalp and cranium. In *Reconstructive Plastic Surgery*. ed. Converse, J. M. Vol. 2, ; 564 (Philadelphia Saunders), 1964.