

CUTIS VERTICIS GYRATA — A CASE REPORT

*Sushil Kumar, M.S., Mch. Neuro Surgery **R. C. Kaza, M.S., ***R Chandra, M D.

Cutis verticis gyrata is a condition of scalp characterised by formation of furrows and folds resembling convolutions of brain. Unna (1907) coined the term cutis verticis gyrata for this condition. It is an uncommon clinical condition though not rare and its association with Hodgkin's disease and treatment by a simple craniotomy flap is described.

Case Report

R. N., a 40-year-old male patient was admitted to neurosurgical service with history of headache of one and a half year duration and blurring of vision for four months duration. Pain used to be continuous and localised to right temporo-parietal region and right side of face. It used to be severe in intensity and relieved by pethidine. There was no history of trauma, fever or scalp infection. He was a known sufferer of Hodgkin's disease and had received radiotherapy for it 4 years back.

On direct questioning he gave history of awareness of folds and furrows over the scalp of 4 years duration.

General physical examination revealed multiple furrows and folds over the scalp

running sagittally about 2-3 mm deep and 4-10 cm in length. Rest of the general examination was unremarkable. Fundus was normal and there was no neurological deficit.

Investigations

Haemoglobin was 8.4 g%, TLC 14850/cmm with P 82, L 12, E 4 and M 2%. ESR was 100 mm/1st hr. Urinalysis, serum electrolytes, blood urea and sugar were normal. Serum Test for syphilis was negative. Electroencephalogram was normal. X-ray chest and skull were normal. Right carotid angiogram did not reveal intracranial metastasis.

In view of intractable pain and drug dependence on pethidine, cingulotomy was suggested to the patient alongwith plastic procedure for the cutis verticis gyrata. Consent for the latter was refused unless it fell within the purview of the first operation.

Bilateral cingulotomy was done through a right frontal rectangular skin flap. Post-operatively the patient reported cessation of pain, was relieved of drug dependence and within the limits of craniotomy flap, the folds and furrows characteristic of cutis verticis gyrata disappeared (Fig. 1). Histopathology

* Neuro Surgeon

** Registrar

*** Research Assistant (Pathology)

Department of Neuro Surgery and Pathology, Safdarjang Hospital and University College of Medical Sciences, New Delhi.

of the affected skin showed prominent invagination of the epidermis. There was moderate hyperkeratosis and mild acanthosis (Fig. 2). Sweat glands, sebaceous glands and hair follicles were moderately increased in number. The corium showed increased amount of collagen and patchy distribution of pink amorphous acellular material which stained blue with alcian blue at PH 2.5.

Discussion

Cutis verticis gyrata may be a morphological manifestation of an underlying disease hence its presence should aware the clinician of an underlying pathology. Polan and Butterworth (1953) found preponderance of male sex involvement. Fischer (1922) classified the disease according to etiology as follows ;

- I. **Primary or Idiopathic** : With and without mental deficiency.
- II. **Secondary**
 1. Collagen tissue and sebaceous gland hyperplasia ; acromegaly.
 2. Inflammatory process : Folliculitis, eczema, psoriasis, impetigo, trauma and infection and syphilis.
 3. Neoplasia ; nevoid tumours, neurofibromes and leukaemia.

Polan and Butterworth (1953) also presented similar classification and found 47% cases as idiopathic. We believe that our case was secondary to Hodgkins disease, of which the patient was a known sufferer and has had treatment for it.

The development of folds and furrows in the scalp can be explained on the basis of

anatomy of the skin of scalp. The presence of septae connecting the skin and deeper layer of superficial fascia of the scalp is an anatomically demonstrated fact (Gray 1959). If there is hypertrophy of underlying collagen tissue, the skin between the septae can be thrown into rugae giving rise to typical appearance of folds and furrows, since the septae prevent lateral expansion.

The definitive treatment of this condition is by way of partial excision of skin provided the skin surface appears normal. Reflection of flap itself can be curative since, the septae binding the skin down are cut as shown by our case.

We were not given the consent for total correction, however, reflection of a craniotomy flap in that area resulted in undermining and relaxation of the skin due to cutting of the septae and alteration of relationship between skin and deeper structures. This is the reason of disappearance of folds and furrows in the craniotomy area. The procedure did not necessitate the relaxation incision through the galea aponeurotica placed under the folds along their course as recommended by Tani et al. (1977).

Anterior Cingulotomy for the relief of intractable pain and addiction is a well established procedures which was carried out in this patient.

Summary :

A case of cutis verticis gyrata in association with Hodgkins disease treated by simple rectangular craniotomy flap without placing incision through the galea aponeurotica under the folds along their course is described.

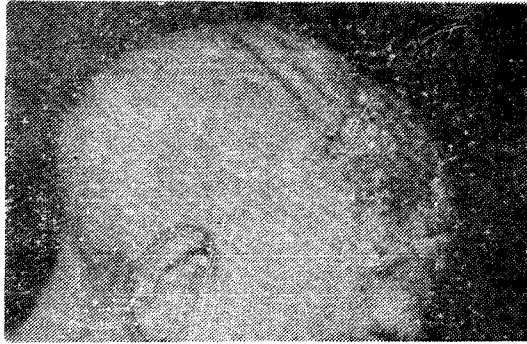


Fig. 1. Showing the disappearance of folds and furrows within the limits of craniotomy flap.

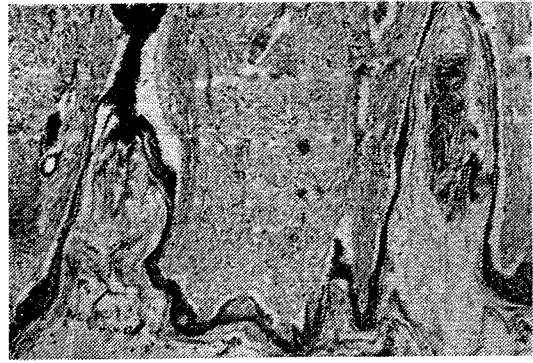


Fig. 2. Photomicrograph showing hyperkeratosis with prominent invagination of the epidermis. The corium shows increased amount of connective tissue and presence of few sweat glands.

REFERENCES

1. Unna, P. G. ; *Cutis verticis gyrata*. *Montash. F. Prakt Dermat.*, 45 : 227, 1907.
2. Polan, S. and Butterworth, T. ; *Cutis verticis gyrata*, A review with report of seven cases. *Amer. J. Ment. Def.*, 57 ; 613, 1953.
3. Fischer, H. ; *Zur Frage der Faltenbildung der Kopfhaut, insbesondere der cutis verticis gyrata*. *Arch. f. Dermat. U. Syph.*, 141 ; 251, 1922.
4. Gray, H. ; *Anatomy of the human body*, 27th ed., Lea and Febiger, Philadelphia, 1959.
5. Tani, T., Miyamoto, Y. and Kurozumi, N. ; *Surgical treatment of cutis verticis gyrata ; a report of 2 cases*, *Br. J. Plast. Surg.* 30 ; 235, 1977.