

MICROSURGICAL TISSUE TRANSFER (M.S.T.T.) FREE FLAPS

*A. Govila, M.S., M.D., Ch. M.

The widely used term "Free Flaps" is a poor selection of terminology and is a reflection of the ignorance of the earlier workers about the possibility of later extensive developments in this field. The term does not convey the desired meaning, further it can confuse the term free grafts which is still used in some of the old conventional units for Thiersch Skin grafts. Both these procedures are in a way free but are very different from each other.

The term "Microsurgical Tissue Transfer" would have been the best substitute. To give it comparatively equal fluence in daily speaking language the short term MSTT might work better. This new terminology will be used through out in this article.

Definition

The following definition covers all the varieties of free flaps. An amount of tissue having its nutritional system preserved within it which is when detached from its anatomical site and is reattached to a different site by reestablishing nutritional continuity through microsurgical anastomosis.

In this definition the term tissue could be replaced by skin, muscle, bone, or composite tissue depending upon the type of tissue employed in the transfer.

History

Attempts on experimental animals were made by many workers during the period

between 1963 to 1972. Important contributions were made by Goldyn, Lamb, and White 1963, Krizek et al, 1965, Strauch and Murray 1967, Fujino, Harashina and Mikata 1972, O'Brien and Shanmugan 1971.

The first successful attempts in the humans was made in 1972 Harii, Ohmrii. and Ohmrii. Subsequently many workers produced increasingly successful results including O'Brien et al. 1974, Ikuta et al. 1975 and Sharzern et al 1975.

Advantages

The MSTT has following advantages.

1. It is one stage technique.
2. Better vascularity is provided to the tissue transferred.
3. There is no postural discomfort of conventional immobilization.
4. Less amount of fibrosis and distortion produces cosmetically better and acceptable result.
5. The larger defect could be covered.
6. The deeper defect could be covered.
7. The transferred tissue can withstand more stress and trauma.
8. A variety of tissue in various proportions could be provided according to the requirements of the defect in one sitting.
9. Better sensation could be provided if the nerve anastomosis is also employed.

Disadvantages

The MSTT has following disadvantages.

1. It is lengthy, exhausting and demanding operation.
2. There is necessity at times to transfer more than required amount of tissue in order to preserve the blood supply.
3. A need for great team work with one team co-ordinator.
4. Tremer free young surgeon almost indispensable—No smoking No alcohol.
5. There is a necessity of spare operating team which can work in shifts in an event of physical exhaustion, which is often seen is very natural.
6. Constant practice, great skill, devotion and patience is necessary.
7. There may be necessity of vein grafts which makes the procedure longer.
8. There is necessity of fair amount of funds for the entire armamentarium
9. It require more operating space to accomodate varied instrumentation, magnifying devices and the members of the team.
10. Some means of interest is desirable to those members of the team who can not look through the microscope and thus can not participate in the progress of the operation. A light background music is also helpful.

Indications

They can be discussed under following headings.

Congenital :

Extensive Haemangioma of face which has persisted through adulthood. Congenital anomalies of the extremities e.g. Digital Aplasia, Udescended Testis.

Inflammatory :

Multiple long standing small venous ulcers limited to one area, but extensive in nature, when other method have repeatedly failed.

Traumatic :

Scalp avulsions, scrotal and penile avulsions, avulsion injuries of the hand and leg, injuries with severe tissue losses anywhere in the body, limited areas of burn contractures.

Malignant :

Hemimandibulectomy following carcinoma mandible, Carcinoma cheek, Carcinoma on lateral nasal wall and below the eye. Carcinoma scalp, Carcinoma breast (Total Breast Reconstruction). Carcinoma Vulva (Vaginal Reconstruction), Carcinoma Chest wall (Chest wall reconstruction) Malignant melanoma sole.

Miscellaneous :

Hemifacial atrophy, Facial palsy muscle transfer, Bed sores.

Procedures :

These are best classified according to the type of tissue used in the transfer. There are basically two types of tissue transferred, One is in single isolated form and the other is in the form of mixture of tissues.

Single Type MSTT :

1. MSST (Microsurgical Skin Transfer)
2. MSMT (Microsurgical Muscle Transfer)
3. MSBT (Microsurgical Bone Transfer)
4. MSNT (Microsurgical Nerve Transfer)
5. MSPT (Microsurgical Perosteal Transfer)

Mixed Type MSTT :

(Composite Tissue Transfer)

This could be in the form of an organ or may be in various combination of tissues. Accordingly they could be divided into two groups. A. MSOT (Microsurgical organ transfer and B.M.S Com T (Microsurgical Composite Tissue Transfer.

A. MSOT (Microsurgical Organ Transfer) ;

1. MSIT (Microsurgical Intestine Transfer)
2. MSOMT (Microsurgical Omental Transfer)
3. MSTT (Microsurgical Testis Transfer)
4. MSET (Microsurgical Extremity Transfer/Toe to hand transfer)
5. MSJT (Microsurgical Joint Transfer)

B.M.S. Com. T. (Microsurgical Composite Tissue Transfer)

1. MSSMT (Microsurgical Skin and Muscle Transfer)
2. MSSBT (Microsurgical Skin and the bone transfer)
3. MSSBMT (Microsurgical Skin, Bone and Muscle Transfer)

MSST (M/S Skin Transfer)

Deltopectoral Flap—Internal mammary perforators mainly second, supported by third and fourth.

Dorsalis pedis Flap—Dorsalis padis vessels.

Groin Flap—Superficial circumflex Iliac Vessels.

Forehead flap—Superficial Temporal Vessels.

Scalp Flap—Superficial Temporal Vessels

Post Auricular Flap—Post Auricular Vessels.

Arm Flap—Ulnar Recurrent Vessels.

Axillary Flap—Thoracodorsal and lateral Thoracic vessels.

Popliteal Flap—Branches of medial and lateral sural vessels

Saphenous Flap—Saphenous artery, vein and nerve.

MSMT (Microsurgical Muscle Transfer)

Brachioradialis—Radial Artery.

Gracilis—Superior unnamed vessels in the dominant area.

Extensor Digitorum Brevis—Dorsalis Pedis Artery.

MSSMT (M/S Myocutaneous Flaps, Skin and Muscle Transfer)

Pectoralis Flap—Lateral Thoracic Vessels

Intercostal Flap—Posterior Intercostal Vessels

Latissimus Dorsi Flap—Thoracodorsal vessels.

Tensor Fascia Lata Flap—Lateral Circumflex Femoral Vessels.

Gluteal Flap—Superior Gluteal Vessels.

Gracilis Flap—Dominant Muscle Artery.

MSBT (Microsurgical Bone Transfer)

Rib—Intercostal Vessels.

Tibia—Anterior Tibial Vessels.

Fibula—Nutrient Artery from Peroneal vessels.

MSSBT (Microsurgical Osteomyocutaneous Flap)

Composite Groin Flap—Deep Circumflex Iliac Vessels.

Composite Fibula Transfer—Nutrient Artery to Fibula.

Composite first metatarsal—Dorsalis Pedis artery for total Rhinoplasty.

Preoperative Considerations and Planning :

This will be discussed in general for all types of MSTT. (Except MSOT which need separate consideration for the subjects like replantation which will be discussed along with the subject. Following points are rehearsed and discussed before starting surgery.

1. The question should be asked in your mind very plainly, whether it is the best approach for the given problem (Do not do it for the sake of doing it).
2. The assessment of the type, quantity and quality of the tissue to be transferred.
3. The decision of the donor site which would be ideal.
4. Decision about donor and recipient vessels.
5. A planning about actual transfer considering the direction and the site and length of the vascular pedicle.
6. A consideration about the type of anastomosis, whether end to end or end to side.
7. A consideration about the direction of transferred muscle fibres or the direction of the hair if it is on cosmetic regions.
8. The assessment of the patency of the vessels to be used, angiography or dopplers probe.

9. Consideration about functional disability and cosmetic disfigurement of the donor area.
10. The possibility of needing a vein graft, which is not initially planned.
11. The possibility of second alternative in the event of unexpected vascular anatomical aberrations.
12. a provision of viable soft bed all around the vascular pedicle.

An example of typical steps of planning is now presented, (Follow fig. 1 to 5). A 40 year old lady presented with basal cell carcinoma over parotid region of about two inches by three inches with out much deeper involvement. If you decide not to mess around the face by some sort of flaps locally raised and you are quite competent in performing MSTT, perhaps it would be justified to go ahead. The requirement in this situation is a thin skin with very little subcutaneous tissue or muscle attached. The surface area required is about four inches by four inches. One of the choices to provide a thin flap could be dorsalis pedis flap. Further planning for this flap is as follows. Nearest vascular bundle here is facial artery and vein, which is marked up to the area of excision of tumour. A piece of linen is cut to the right size of the area of defect and a small tail of linen is left intact in correct direction over the area of vascular bundle. The superficial and deep surfaces of the linen are marked. Medial, lateral, upper and lower borders of the linen are marked.

Now this piece of linen is put on the dorsum of the foot in a way that the vascular bundle lies on the selected donor vessel in this case dorsalis pedis artery. About two cm. extra length of the pedicle is planned. The

size of the flap is exactly planned to the size of the defect.

Pre-operative Rehearsal

In some extensive microsurgical procedures such as composite iliac osteomyocutaneous flap based on deep circumflex iliac. It is very wise policy to rehearse the entire procedure step by step on bone models and cadaveric dissections. This is very important because then the direction of line of bone union, the method of bone fixation, exact shape of the bone, the amount of the muscle which will have to be taken irrespective to the requirement can all be appreciated before facing them on operating table.

Intra-operative Considerations in General

There are many technical difficulties faced during the operation in clinical situations as compared to practising in the experimental laboratory. The single most important difficulty and most commonly experienced trouble is the blockage of the nutrition to the flap. The block could be in the artery or in the vein. Commonly it is the venous thrombosis which is the seat of obstruction. The equally common cause of the block is the vascular spasm. This is more often seen if the vessels selected are partially damaged or having perivascular fibrosis, or when the technique is traumatic, such as too often irrigation and mopping, or too many times a needle puncture is made to pass the stitch, or when unknowingly a bite has been taken in the posterior vessel wall. There is no drug which could abolish vessel spasm, although many pharmacological claims could be found in the literature.

I deal with the problem in following manner. I fill the flap very tightly with heparinised blood before it is taken off from the

donor attachment. To perform this microsurgical clamps are applied to the artery and the vein and then about 20 cc of heparinised blood is forcefully injected through a wide bore needle puncturing distal to the clamp in the artery, so that entire vascular system gets engorged and is kept in that state as there is a venous clamping. The pedicle is only severed when the recipient site is ready to take the anastomosis.

The thrombosis is diagnosed by the color of the flap and by exploring the anastomosis. If the flap is white and empty it has no blood in it (Arterial obstruction). If it is blue and tense it has too much of blood in it (venous obstruction).

If thrombosis is diagnosed when the patient is on the operating table and is under the effect of anaesthesia, reexploration of the anastomosis, irrigation, revision of the anastomosis or even a vein graft can overcome the problem. But if the patient has been moved into the ward and is out of anaesthetic then the part of the flap having the pedicle alone needs exploration under local anaesthesia around pedicle. Meticulous haemostasis throughout the procedure specially around the vascular pedicle is nowhere so important in surgery as here.

One final intraoperative consideration is when to remove the clamps. Controversial opinion exist on this point. I prefer to leave the clamps until my both arterial and venous anastomosis are complete. I feel if venous clamp is removed first, and the arterial clamp is left intact (and is delayed because of any cause) then there is too little blood in the flap to be drained and this makes the flow sluggish and thrombus may form. On the other hand if the arterial clamp is removed

first the gush of blood will fill the flap and thus the venous side will have no chance of slow circulation.

Post Operative Management in General

Oedema in these flaps is more than conventional pedicle flaps and should not be the cause of concern unless it is accompanied by discoloration and blistering. Hourly observation for colour, temperature and capillary return is carried out for first 24 hours and this could be reduced to every 4 hour for next 2 days. Anticoagulants are rarely needed but if the thrombosis has been caused and been successfully removed, and if reanastomosis was needed, then it is wise to start some anticoagulants.

Having discussed the general pattern of the problems encountered now is the time to discuss individual flaps. It is beyond the scope of the article to include all the flaps, so the common flaps will be detailed. Only the marking of flaps, some salient points during the elevation of the flaps, and their merits and demerits need consideration.

Deltpectoral Flap

A line is marked just below and parallel to the clavicle starting from just below the sternoclavicular joint to acromion process. The arm is kept in adduction and then a line parallel to above line and four inches below is marked in such a way that it just touches the anterior crease of the axilla. These two lines are connected laterally over the top of the shoulder. The medial limit of the flap is not marked initially. About one cm. lateral to sternal margin feeding perforators of this flap are marked, mainly in the second intercostal space but also third and fourth supporting perforators.

Flap elevation is started from lateral to medial side. Deep fascia is taken with the flap. The careful dissection around perforators and tying them in the depth before dividing them is important. Because of the shortness of the pedicle, filling of flap with heparinised blood is not possible in this situation before dividing the pedicle.

Advantages of the flap are that it gives better colour match, it is a thin flap than other free flaps, except dorsalis pedis flap. The disadvantages of the flap are that it is not a good procedure in females as it gives prominent donor scar. Old female patients can perhaps tolerate this bluish.

Dorsalis Pedis Flap (Fig. 1 to 5)

Marking of the flap is started from the lateral border which is marked about an inch above the lateral margin of the foot. The medial border is marked by a line between medial margin of sole of foot and extensor hallucis longus. Distal limit of the flap is the top of the crease in the first web space. The proximal limit is marked on the ankle crease. The dorsalis artery is marked by palpation. Veins of the leg are made prominent by making the leg dependent for few minutes and then some of the proximally going veins are marked.

The flap is elevated under tourniquet. Incision is best started at the distal limit of the medial marking as it gets to the right and then carried proximally. A part of the paratenon anterior to the extensor hallucis longus should be taken with the flap. It is very important because this keeps you in the plane. Extensor digitorum brevis is to be taken with the flap. The medial incision is carried over the front of the ankle and is carried longitudinally over the dorsalis pedis

marking. Through this incision the vascular pedicle is isolated. The deep peroneal nerve if need be included with the flap it runs besides the artery.

The advantages of this flap are that it is the thinnest of the free flaps available, flap is hair less and there is minimal donor site disability. The disadvantages includes limitation of the size, poor healing over the tendon of extensor hallucis longus and poor color match for facial reconstruction.

Latissimus Dorsi Flap (Fig. 6 to 11)

It is the best flap yet devised in the field of microsurgery. Marking of the flap is started by marking all the lumbar and lower six thoracic spines. Posterior half of the iliac crest is then marked. Now the lateral border of the posterior axillary fold is marked, this is then connected to the lateral limit of the iliac crest. Upper limit is marked by connecting the 7th thoracic spine to the posterior axillary marking. It is rarely needed to raise the entire boundary thus marked. Within this marking the required amount of the flap is marked and raised.

Elevation of the flap is begun by isolating the vascular pedicle, through an incision parallel to and on the posterior axillary fold. The thoracodorsal artery runs on the under surface of the Latissimus dorsi muscle in the posterior axillary fold. Through the incision the finger is passed and the muscle is hooked and pulled medially to retract it. The dissection and search under the muscular tendon will reveal the artery. The rest of the flap is then raised.

A very long length of the pedicle in this flap is a great advantage. The vessel size is biggest of all the free flaps available which makes the transfer very safe. The success

rate is highest with this flap. Most of the flap donor area could be directly closed, some of it might need a skin graft. It is cosmetically perfectly acceptable as the area is on the back. There is hardly any functional loss as most of the times a good amount of muscle is left behind.

The disadvantages of the flap are that the positioning of the patient on the table and the steps of flap transfer are made cumbersome because of the site of the flap. The closure of the donor area can not be simultaneously performed (as is done in most other flaps), because of the position of the patient. This flap is usually very thick and hence only good for deeper defects.

Tensor Fascia Lata Flap

Anterior limit of the flap is anterior superior iliac spine. The posterior limit is about 4 inches beyond anterior iliac spine. The length of the flap could be upper two third of the thigh. Vascular pedicle is marked 6 cm. below and just behind anterior iliac spine. It is important to realise that the vascular pedicle do not enter at the end of the flap. It enters transversely from a branch from lateral femoral circumflex artery which in itself is a branch of the profunda femoris artery.

Elevation is started from below upwards on the anterior marking of the flap as it is easy here to get into the correct plane under the tensor fascia lata. When rest of the flap has been raised the muscle is detached from the iliac crest by sharp dissection.

The advantages of the flaps are that the vessel size is fairly good, dissection is fairly easy, and thick long bulky tissue is supplied.

The disadvantages of the flap are that the length of the vascular pedicle is small,

the pedicle is not towards the end of the flap and the donor area is quite conspicuous.

Saphenous Flap :

First of all the sartorius muscle is marked in lower third of the thigh. The saphenous artery runs parallel and under the lower end of sartorius muscle, above the knee joint. The saphenous vein and the nerve run over the muscle. The saphenous vein becomes prominent after making the leg dependent, and then it could be marked. The flap about six inches by six inches is then marked below the vascular pedicle on the medial side of the knee and upper part of the medial leg.

The advantages of the flap are that it is a thin flap, it has long vascular pedicle, and the nerve supply could be used.

The disadvantage of the flap are that the donor scar is on very obvious site, and on the mobile area of the body and thus has more chances of hypertrophy. If the nerve is also used then there is area of anaesthesia on the entire medial side of the leg.

Groin Flap (Fig. 12 to 15)

This is most tricky of all the flaps as the vascular anatomy is most inconsistent and the dissection is difficult.

The mid inguinal point and the anterior superior iliac spine is marked. A line parallel to the inguinal ligament and one inch below the above marking is drawn. This is the central axis of the flap. Along the central axis up to 10 cm wide flap could be raised. The lateral limit is about 3 inches beyond anterior superior iliac spine.

In elevation of the flap the vascular pedicle is isolated first. A longitudinal incision in the line of femoral pulsations is made and by careful dissection around, it will

reveal the branches coming out of femoral artery. Care is taken to preserve the superficial circumflex iliac vein which crosses the femoral artery anteriorly to open in the saphenous vein, just before it terminates in the femoral vein. The superficial circumflex artery usually arises from the antero lateral surface of the femoral artery but it can arise from any direction, even from the posterior surface. If it is not found in the usual site then it might be arising from above the inguinal ligament, which has to be cut to find the artery. It can arise as isolated vessel or as a branch of a parent trunk which divides into three superficial arteries. The usual diameter of the artery is one to two mm and that of a vein two to four mm. At time the artery comes out as two to three small branches of less than one mm. It is safe to discard this flap in such a situation. The artery and the vein supplying the flap do not run together many times and need careful separate dissection. The artery of whatever origin feeding the flap divides into superficial and deep branches at the medial end of the sartorius. The superficial branch pierces the deep fascia near medial border of the sartorius to run on the superficial plane laterally. Rest of the flap after isolation of the pedicle is raised from lateral to the medial side.

There is almost negligible donor site morbidity as the defect can be directly closed and the scar could be hidden under the bikini. This seems to be the only advantage of the flap.

Disadvantages of the flap includes inconsistent vascular anatomy, a fairly bulky flap in a fat patient and the vessel size is not good enough to make every case a success.

Subaxillary Flaps :

I am introducing this new term "Subaxillary Flaps" for those flaps which are raised below axilla. The area between lateral border of pectoralis major and the lateral border of the latissimus dorsi, below the axillary artery above the palpable rib margin could be defined as the subaxillary area. Flaps raised in this area could be called as subaxillary flaps.

The following vascular system lie in this territory and has been used clinically.

1. The thoracodorsal branches of subscapular vessels.
2. Lateral Thoracic vessels.
3. The accessory lateral thoracic vessels.
4. Some cutaneous branches from above mentioned vessels.

The following type of tissues (Flaps) has been raised on this subaxillary system.

Free skin flap.

Free hair bearing skin flap.

Free myocutaneous flap with Latissimus dorsi.

Free osteomyocutaneous flap with part of the rib.

When thoracodorsal vessels are used it is better to center the flaps on the lateral

border of latissimus dorsi. When lateral thoracic vessel are used it is better to center the flap on the lateral border of the pectoralis major. Thoracodorsal artery may be absent in few cases.

An incision is made on and parallel to axillary artery about three inches in length. The dissection and exploration of the branches of the axillary artery is performed as the first step. The subscapular artery will be found going deep on the lateral border of Latissimus dorsi muscle. The vessels will be found on the under surface and the upper end of medial border of pectoralis major muscle. The artery gives a branch to supply the muscle and then becomes entirely cutaneous. Having isolated the vascular pedicle rest of the flap is raised from distal to proximal area.

The flap has a good colour and texture match in head and neck reconstruction, a great advantage of these flaps. The donor scar is concealed. There are three arterio venous system in closer proximity to select from. There is provision of supplying hair bearing skin, muscle and rib. The direct closure is possible some times.

The flap has a disadvantage that it becomes bulky in females near the breast area.

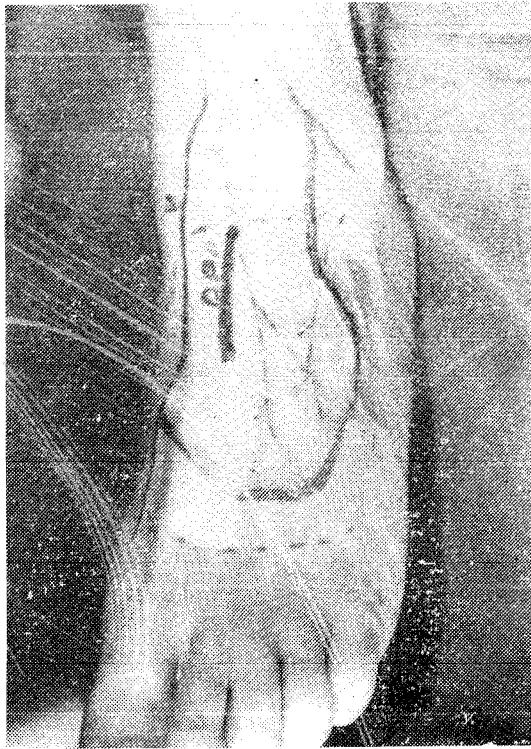


Fig. 1. Showing markings on veins of foot with in dorsalis pedis flap area after making foot dependent.

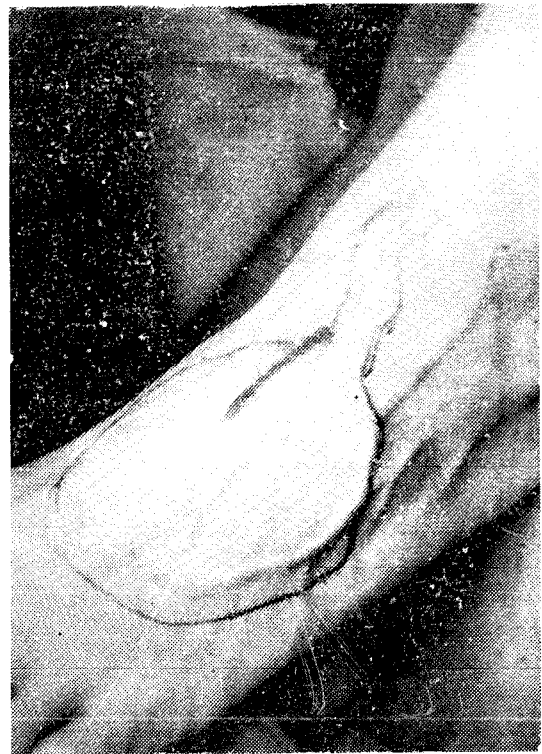

Fig. 2. The area of flap to be raised on the dorsum of foot is marked by marking around the linen impression of the defect on face. The tail of vascular bundle is put on the dorsalis pedis artery.

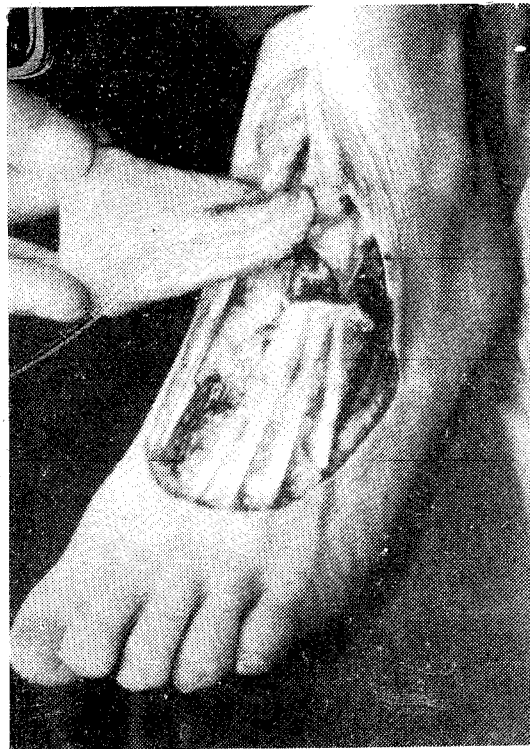

Fig. 3. Flap raised. It is still attached by vascular bundle.

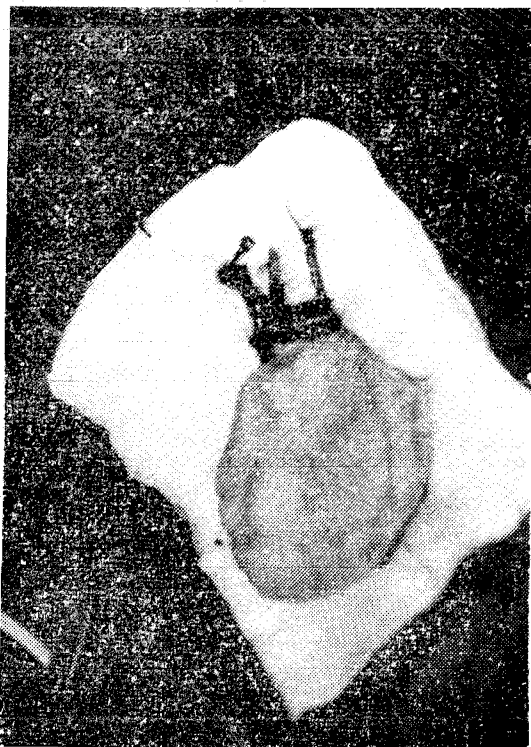


Fig. 4. Free Dorsalis pedis flap on the gauze piece.

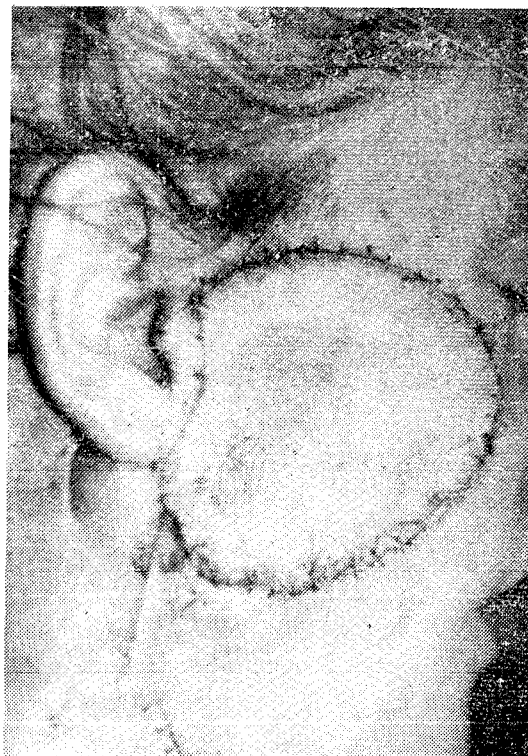


Fig. 5. Dorsalis Pedis Flap transfer, soon after operation.

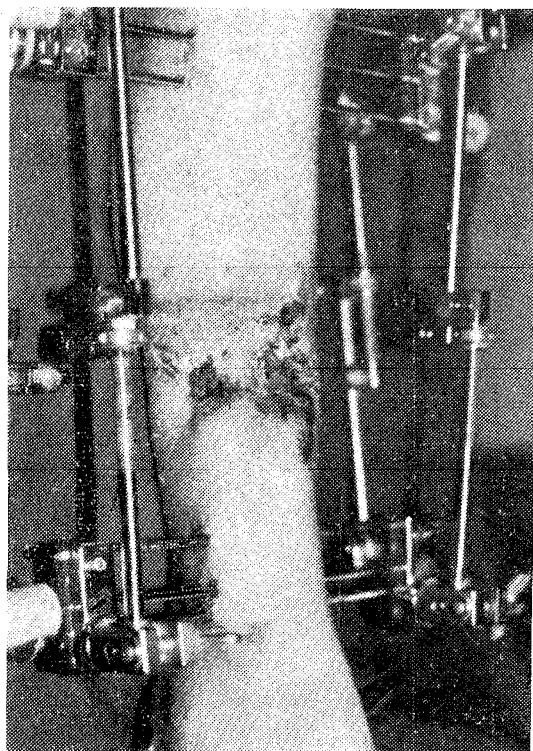


Fig. 6. Crush injury right leg after four weeks in Hoffmann's frame. There is bone loss of about an inch in the tibia, under the skin defect of middle third of leg.

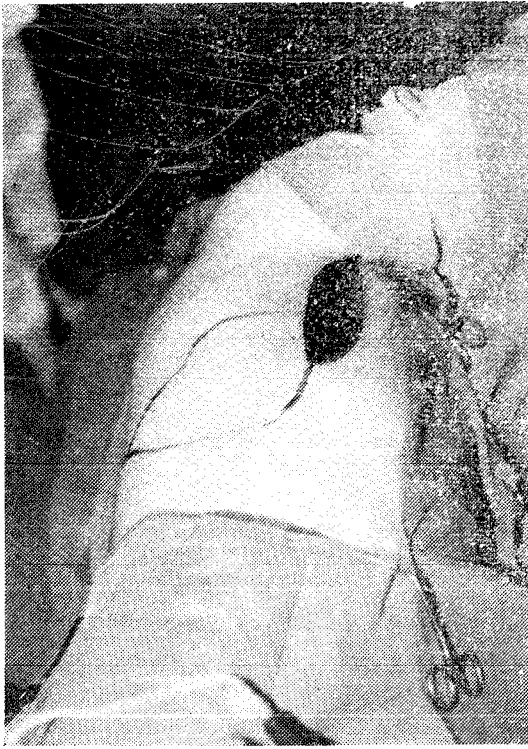

Fig. 7. Latissimus Dorsi flap marked on the left side.

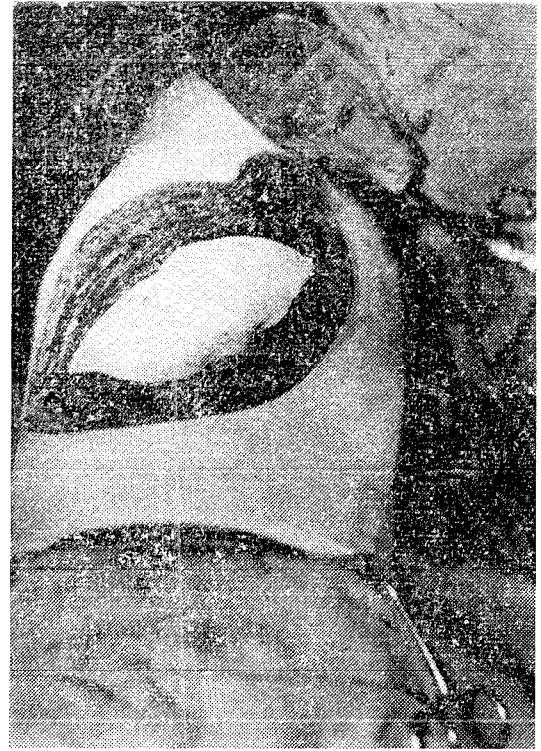


Fig. 8. Latissimus Dorsi flap cut all around.

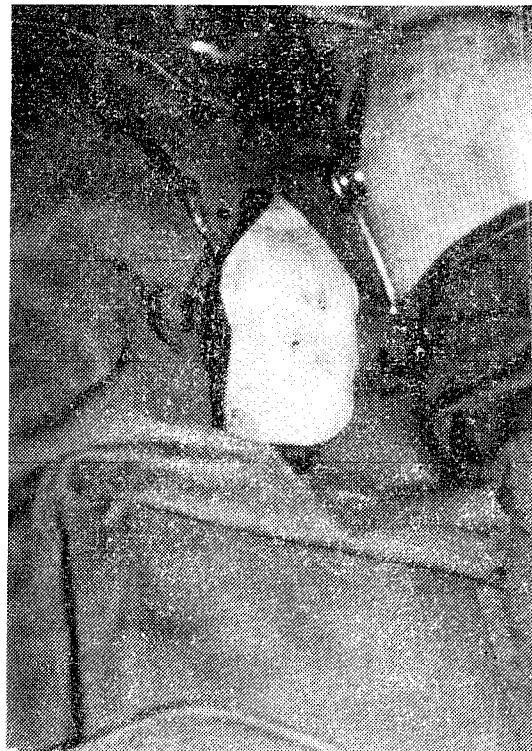

Fig. 9. Latissimus Dorsi free flap showing length of pedicle.

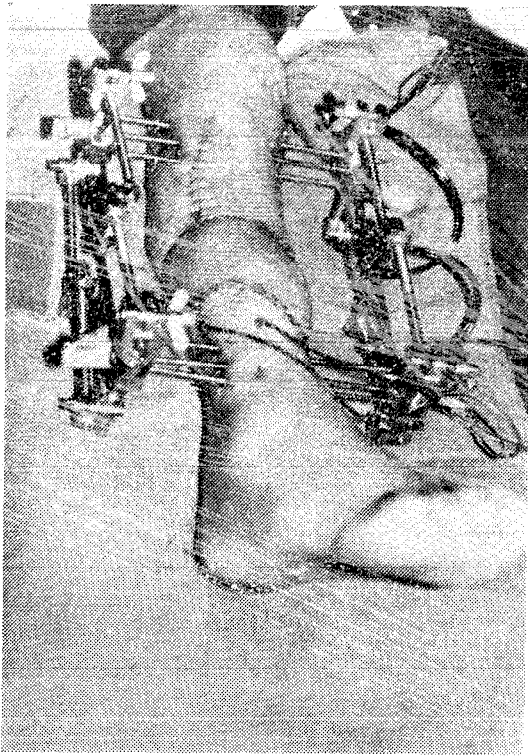


Fig. 10. Latissimus Dorsi free flap transferred. Three days post operatively.

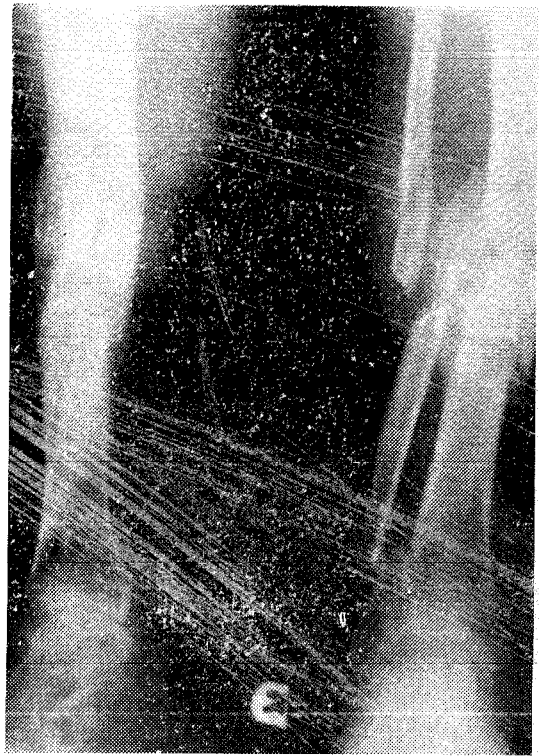


Fig. 11. X-ray picture after 10 months of chip bone grafting.

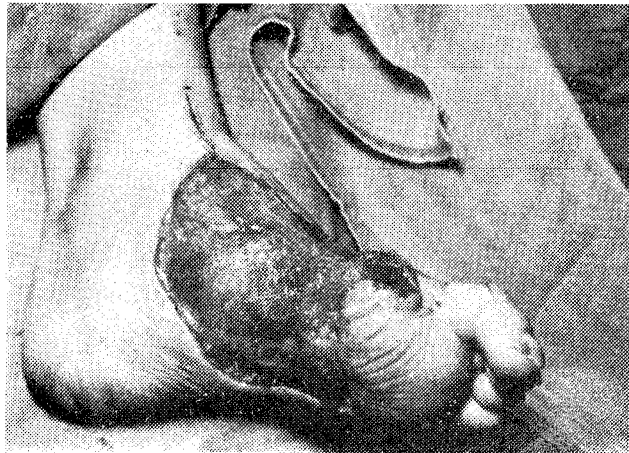


Fig. 12. Defect on left foot following crush injury.

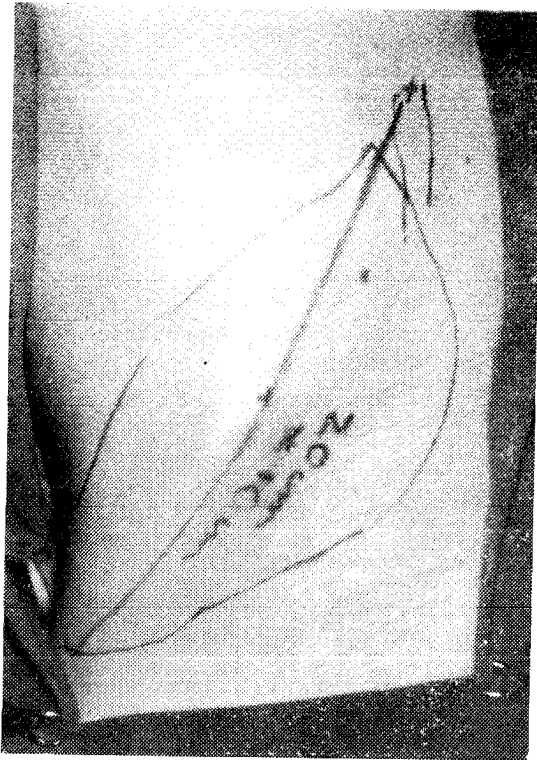


Fig. 13. Groin flap marked left side.

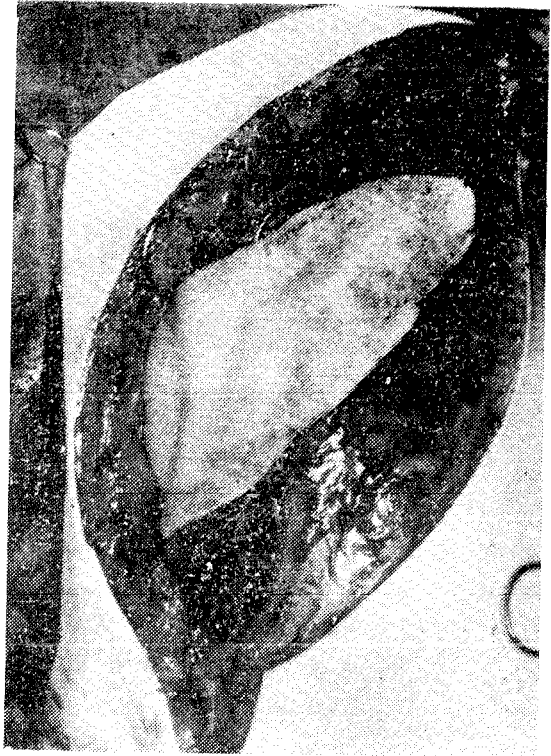

Fig. 14. Groin flap raised.

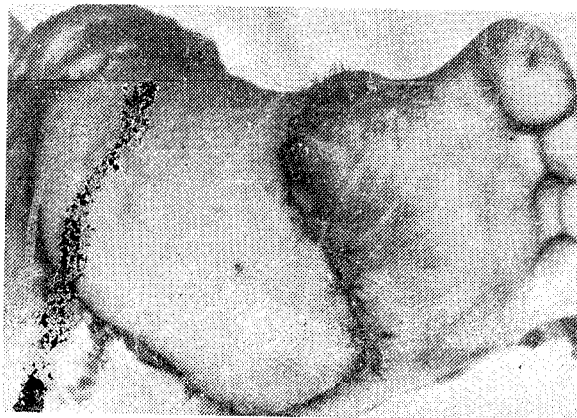


Fig. 15. Groin flap transferred on foot.