



## Letters to the Editor and Brief communication

This section will contain letters to the editor which deal with matters that are published in the journal and brief communications on all the aspects of plastic surgery. The views, opinions and conclusions expressed in this section represent the personal opinions of the writers and not those of the Editorial Board or the Association of the Plastic Surgeons of India.

### MODIFICATION OF THE ENDOTRACHEAL TUBE FOR CLEFT PALATE AND ORAL SURGERIES.

Sir,

Inadequate mouth opening could well be a problem during cleft palate surgery. Efforts to get good surgical exposure by excessive opening of the mouth gag could lead to kinking of the tube and increase the air way resistance. The kinking most often occurs at the alveolar margin. Oxford, RAY and Flexometallic tubes are preferred for cleft palate surgery to avoid this problem.

We are presenting a technique to prevent tube collapse when portex, silicon or red rubber tubes are used. With aseptic precautions, the tube is passed through a proper size, autoclaved Magill's metal connection and the connector is placed in such a way that it is protected at the alveolar margin. Two or three, different sized tubes are prepared prior to the induction of

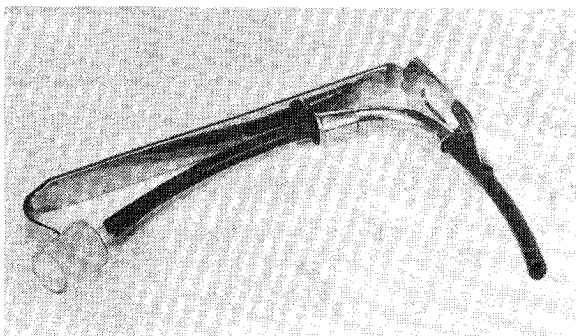
anaesthesia. Intubation is done in a normal way. After intubation, finer adjustment is made to bring the curved portion of connection at the alveolar margin, if required. When the mouth is opened with the help of a mouth gag, the tube under the metal protection does not kink even though excessive pressure is being given and mouth can be opened to its utmost capacity (Fig1).

The tube that has been described here is easy to assemble from different parts which are available in all operation theatres. The connector can be placed precisely at a desired level after intubation to match the curve of the blade. The mouth gag can be opened to its utmost capacity without kinking of the tube. This technique is also useful in adults with limited mouth opening. The tube and the connection can be autoclaved and reused. As both ends of the connector are blunt, there are no chances of injury to the soft tissues. We have used this tube in more than 100 cleft palate and other oral surgeries without any complication.

Hemant A Saraiya, MS, MCh

Paresh Mehta, MD

Saraiya Plastic Surgery & Burns Hospital,  
310, Sumeru Complex, Ahmedabad 380 006.



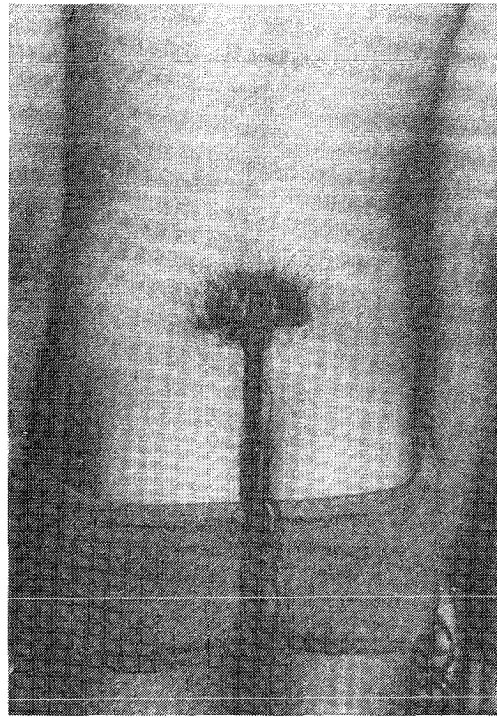
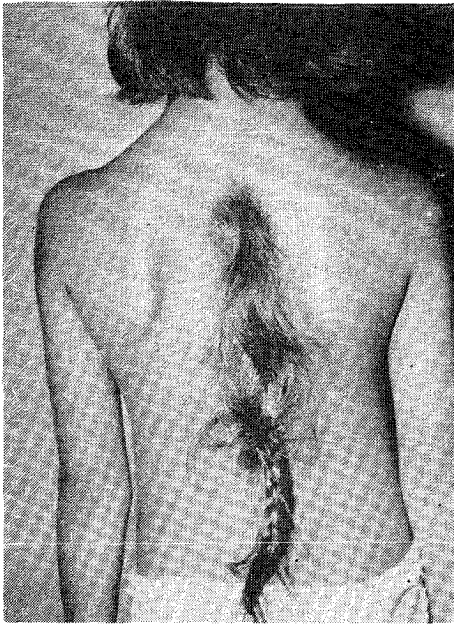
(Fig-1) The assembled endotracheal tube with the Magill connection with the blade of the mouth gag in position.

### ABNORMAL HAIRY GROWTH IN THE BACK SANS SPINAL DEFORMITY.

Sir,

Tufts of hair growth in the posterior midline of the body and pigmentary naevi are usually markers for defects of the spine or the spinal cord. I had the experience of treating two children who presented with abnormal growth of the hair in the back without any obvious anomaly.

The first case was a girl aged 8 years who presented with 18" long hair in the thoracic spine region. Radiological examination of the spine was normal. She had no other congenital anomaly (Fig1). Another girl aged 10 years



(Fig-1 & Fig-2) Photographs showing the abnormal hairy growth.

presented with 18" long hair in the lumbosacral region. Clinical and radiological examination did not reveal any congenital anomaly. (Fig 2) Both children did not have any pigmentation. The first child was treated by elliptical excision and primary closure while the second was lost to follow up.

Children born with hairy naevus on the back should be examined thoroughly for spinal anomalies. Diastematomyelia, a serious neurological problem is often associated with hairy naevus. This neurological problem should be diagnosed by MRI at the earliest since this is a surgically correctable anomaly and early diagnosis prevents irreversible neurological sequelae. The present cases are different from giant hairy naevus due to the absence of pigmentation and they were not associated with any spinal anomaly.

**Y N Iral, MS, FICS**  
Dr. Iral Hospital, Dharwad 580 008

#### **REPAIR OF LABIA MINORA PERFORATION BY LOCAL ROTATION FLAPS**

Sir,

Labia minora perforation is a very rare condition occurring in young unmarried females. It is difficult to close these perforations by a two layered repair because of the excessive fibrosis

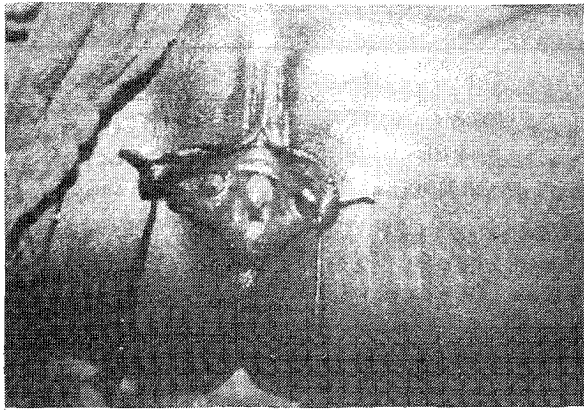
in the tissues after infection causing delayed healing or breakdown of suture line. We had the opportunity of undertaking such a repair in a young girl with labia minora perforation.

An 18 year old unmarried female presented with through and through perforation of both her labia minora. After ruling out fungal infection these perforations were repaired at another centre but eventually the repair gave way. On examination the patient had normal secondary sexual characters. The labia majora were normal. The labia minora showed a defect measuring 2.5 x 2cms on right side and 3.5 x 2.5 cms on the left side (Fig 1). A successful repair was performed in a single stage using double opposing local skin flaps, one each from the medial and lateral aspect of each labium minus (Fig 2). The wounds healed uneventfully (Fig 3).

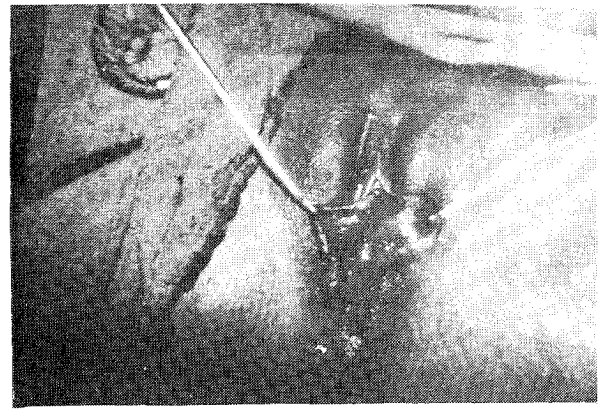
The case presented here had excessive fibrosis resulting from infection. The double opposing medial and lateral rotation flaps provided two different tension free seam lines and ensured healing without distorting the configuration of the labia minora.

**V.K. Tiwari, MS, MCh**  
**Sujata Pande, MS, MCh**

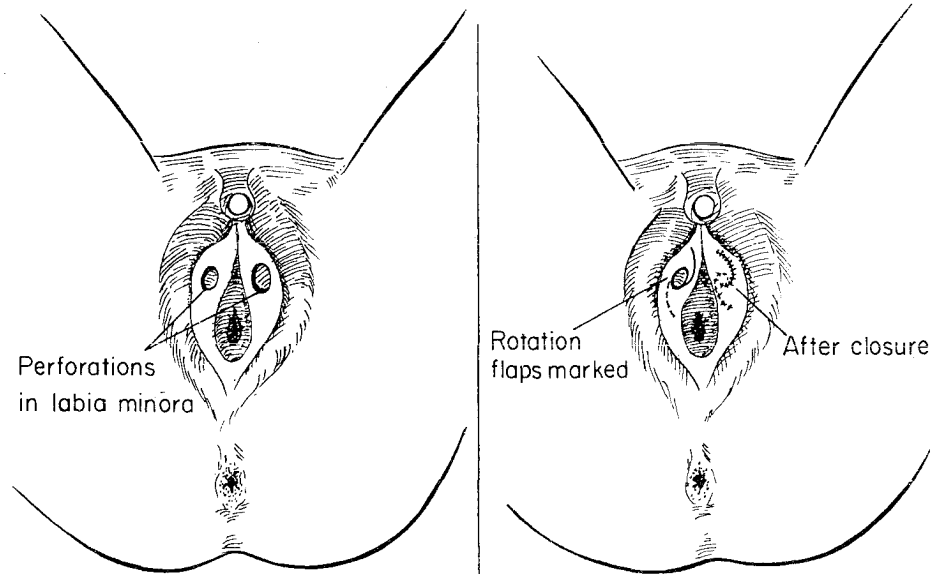
Department of Burns, Plastic and Maxillofacial Surgery, Safdarjung Hospital, New Delhi.



(Fig-1) Holes in the Labia Minora



(Fig-3) Post operative status



(Fig-2) Planning of the flap

**CLEFT LIP NASAL DEFORMITY IN THE ABSENCE OF CLEFT LIP**

Sir,

We report a case of a fifteen year old male student presenting with typical cleft lip nasal deformity with a clinically intact lip. History revealed impaired speech since childhood and on examination patient had a submucous cleft palate. The nostrils were asymmetrical with laterally displaced right alar base. The upper lip cupid bow was irregular on the right side and on palpation did not reveal any defect in the orbicularis oris muscle (Fig. 1&2).

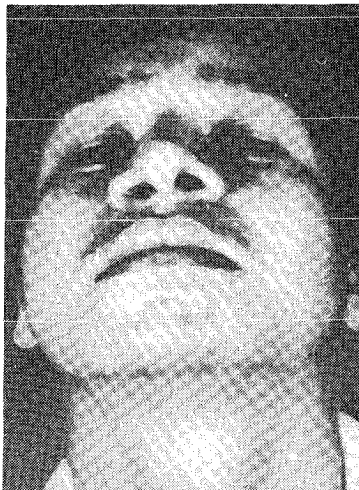He underwent palatoplasty for submucous cleft palate and his speech improved following

operation and post operative speech therapy. Since the patient was ignorant about his nasal deformity and unwilling for correction of the same, nasal deformity was not corrected.

In 1964 Brown<sup>1</sup> reported a single case of an isolated cleft lip nose. He suggested the nostril deformity may be an integral part of the cleft lip syndrome, and not secondary to it. Stenstrom in 1965<sup>2</sup> stated that the fundamental cause of the deformity was that the alar cartilage has glided out of place. He also noted that one of his patients had hypoplastic pits and opaque spots on the lateral incisor tooth. Five cases were reported by Khoo Boo-Chai<sup>3</sup> in 1968. In all his cases there were nothing abnormal in the size and shape of the alar cartilage. Therefore he did not support the view of Brown that the deformity



(Fig-1) Face – Front view of nose and lip deformity



(Fig-2) Face- Worm's eye view of the nose and lip deformity

was due to an intrinsic defect in the alar cartilage. Bard Cosman<sup>4</sup> in his report suggested that this spectrum of defects was entirely consonant with the mesodermal penetrance theory of cleft formation but difficult to explain by the concept of failure of fusion of facial segments. Our patient had a rotated incisor tooth denoting alveolar arch involvement.

This deformity should be differentiated from the more easily recognized minimal cleft lip<sup>4</sup> which is a more common condition. A history of trauma (operative or otherwise) and infection should be specifically excluded before making this diagnosis.

**Prakash P J, MS, M Ch**  
**Kingsly Paul, MS, (ENT)**

Dept. of Plastic Surgery,  
Christian Medical College, Vellore.

## References


1. **Brown RF.** A reappraisal of the cleft lip nose with the report of a case. *British J Plasti. Surg.* 1964; 17:168
2. **Stenstrom SJ and Thilander BL .** Cleft lip nasal deformity in the absence of cleft lip. *Plast. Reconst.Surg.* 1965;35:330
3. **Khoo Boo-Chai and Tange I.** The isolated cleft nose *Plast. Reconst. Surg.* 1968; 41:28
4. **Cosman B and Crikelair G F.** The minimal cleft lip. *Plast. Reconst. Surg.* 1966; 37:334.

## AN ELECTRIC OVEN FOR THERMAL THERAPY OF LYMPHOEDEMA


Sir,

Heat therapy has been advocated by the Chinese for the management of lymphedema. Both electric<sup>1,2</sup> and microwave<sup>3</sup> oven have been used for his purpose. Pani et al<sup>4</sup> have advocated heat therapy in a bucket of warm water.

A heat insulated electric oven has been devised for heating lymphedematous limb. In this device heat is produced by an electric heater placed inside the oven towards the rear. The walls are heat insulated. There is a thermostat to regulate the temperature and a circuit breaker to prevent the electric shock. A wooden platform is provided inside to support the limb. The device is kept in a slanting position with the rear end 20 cms higher. The patient lies down in the supine position and inserts the limb inside the oven through the opening in the front (Fig1&2).



(Fig-1) The electric oven



(Fig-2) Patient receiving heat therapy

The residual gap in the entrance around the limb is sealed by a piece of woolen blanket to prevent escape of heat. Seven patients, four with grade II and three with grade III (WHO Classification) lymphedema received heat therapy in this oven for one hour at 45 to 55 degrees centigrade. A session consisted of twenty consecutive days. A total of three such sessions were administered to each patient with 10 days interval in between sessions. Limb measurements were taken before and after the completion of therapy.

Six patients had reduction in size of the limb ranging from 14 to 33% the average being 23%. In one patient there was no reduction. None of them had any attack of lymphangitis during therapy and none sustained burn. All the patients subjectively felt better.

**Satyanarayan Mishra** MS, DNB, MCh

Lymphedema Treatment Centre  
338, Second Main Road,  
Mariappa Nagar, Annamalai Nagar 608 002.

#### References

1. Clodius L. Lymphedema In ; McCarthy JG ed. Plastic Surgery Vol.6. Philadelphia WB Saunders Company, 1990: 4093- 4120 .
2. Tambwekar SR. An electric oven for thermal therapy in lymphedema , presented in the II Annual Conference of Lymphology Association of India, Chennai.1997
3. Ohkuma M. Lymphedema treated by microwave and elastic dressing. Int. J. Dermatol 1992; 31: 660-663.
4. Pani SP, Yuvaraj J, Vijayalaxmi G, Reddy GS in : Management of Lymphatic Filariasis, Pondicherry Vector Control Research Station Misc Publ. 1997; 21:9

## LYMPHANGIOMA CIRCUMSCRIPTUM - A CASE REPORT

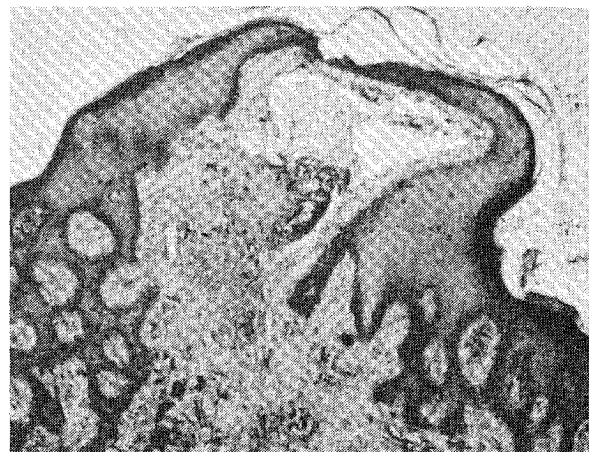
Sir,

Lymphangioma Circumscriptum is a rare disease involving lymphatic channels of skin and uncommonly of deeper tissues. Due to its rarity, the condition could be confused with other conditions of skin and soft tissues.

A 12 years old female patient was admitted with the complaints of swelling on the medial aspect of the right hand and wrist since birth. The father of the child informed that initially the swelling was of pea-size and steadily increased to the present size. On examination there was 12 cms x10cms swelling over the medial border of the right hand and wrist extending from the lower fourth of the forearm to metacarpophalangeal joints. It extended both on the dorsal and palmar aspects upto the midline. It was firm diffuse, non-tender with crops of vesicles at places. A provisional diagnosis of soft tissue sarcoma was made.

No bony involvement was made in the skiagrams.

Fine needle aspiration cytology of the swelling was suggestive of inflammatory lesion. An incisional biopsy of the swelling was done, which on histopathological examination revealed cystically dilated lymphatic vessels lying in papillary dermis with marked thinning of the overlying epidermis (Fig 1). Some of the dilated vessels appear to be enclosed in epidermis. Inflammatory cell infiltrates were seen in the dermis. The dilated lymphatic channels were



(Fig-1) Photomicrograph (100x) of section of the swelling showing dilated lymphatic channels in the papillary dermis with thinning of overlying epidermis and inflammatory cell infiltrate in the deeper dermis

seen to be filled with light pink staining lymph and lined by flattened epithelial cells. There was no evidence of malignancy anywhere in the sections. The diagnosis was infected lymphangioma circumscriptum. The whole of the swelling was excised and covered with full thickness skin grafts. The graft took well and at one year follow up there was no recurrence.

Lymphangioma circumscriptum is characterized clinically by presence of vesicles filled with clear fluid within a circumscribed area of skin. It is either congenital or appears in early childhood. Most common sites of involvement in descending order are the breast, thigh, buttocks, neck and axilla. It could also occur after surgery and radiation therapy. It is postulated that the lesions essentially consists of a collection of large muscular coated lymphatic cisterns, lying deep in the subcutaneous plane and communicating via dilated dermal lymphatics with superficial

vessels. It is suggested that it may be possible to treat these lesions more successfully and with better cosmetic results by excising the subcutaneous cistern and leaving the overlying skin intact<sup>1</sup>. Complications include rupture of the vesicles and secondary infection. No malignant change has been reported.

**Shakeel Akhtar**, MD, Lecturer, Pathology

**Syed Manazir Hasan**, MD, Senior Resident, Pathology,

**Rana Sherwani**, MD, Reader, Pathology,

**LM Bariar**, MS MCh, Professor, Plastic Surgery,

**Mahboob Hasan**, MD, Lecturer, Pathology.

J.N. Medical College Hospital, A.M.U,  
Aligarh-202 002.

#### Reference

**Whimster IW**. The Pathology of Lymphangioma Circumsriptum. Brit J Dermatol 1976; 94:973.