



## Review Article

### FLAPS IN LOWER LIMB TRAUMA: CURRENT STATUS

Kumar P, Bhaskara KG, Chittoria R, Thomas PC

Department of Plastic Surgery, Kasturba Medical College, Manipal-576 199, Karnatak, India

The importance of obtaining early definitive wound healing after lower extremity trauma cannot be over emphasized. The restoration of an intact covering is the primary surgical requisite following trauma of the lower extremity because deep healing can be no better than the surface covering<sup>1</sup>.

The history of plastic surgery in the lower extremity is predominantly that of lower extremity trauma, particularly inflicted during war time. Better understanding of muscular anatomy, cutaneous blood supply, and microsurgery have made tremendous advancement in the field of lower extremity reconstruction.

The concept of emergency free tissue transfer<sup>2</sup> was developed in 1980. Organisation of a continuous joint orthopedic - plastic surgery service is necessary to offer patients the option of a single stage operation that combines debridement and eventual final reconstruction. There will always be sporadic cases in which delayed primary reconstruction is preferred for medical reasons, but practicing it for convenience should be eliminated.

#### Anatomy

Following unique features of the lower limb makes the reconstruction different from that for the upper extremity<sup>2</sup>:

1) The lower extremity is almost always in a dependent position and more susceptible

for deep vein thrombosis, venous stasis and oedema.

2) Increased incidence of peripheral vascular diseases.

3) The subcutaneous location of the tibia, the main weight bearing bone of the leg, poses unique problems in the fracture healing.

#### Principles

I. **Vascularity of the limb** should be checked at the earliest.

II. **Assessment of the defect and structures exposed:** The defect is assessed for soft tissue and bony loss. The exposed structures like bare tendon and bone alters the management strategy.

The "Gustilo-Anderson" classification of open leg wounds<sup>3,4</sup> is as follows.

##### Grade I

Wound less than 1cm long, clean, little soft tissue damage, no crush injury.

##### Grade II

Laceration greater than 1cm, no extensive soft tissue damage; no flaps or skin avulsions and moderate skin crush.

##### Grade III

Extensive soft tissue damage, including skin, muscle and neurovascular structure; highly contaminated. Further divided into 3 groups:

- a) Large Laceration or skin flaps that nevertheless provide for adequate soft tissue coverage
- b) Extensive loss of soft tissue with periosteal stripping and exposed bone; massive contamination, severe comminution and loss of bone
- c) Open fracture associated with arterial injury requiring repair

The classic reconstruction ladder (primary closure, skin graft, flap) is helpful but is not the sole criterion used for planning reconstruction in cases of lower limb trauma.

**III. Assesment of the region involved:** Reconstruction of the lower extremity has traditionally been planned by dividing the leg in three parts. Flaps available in each third are then enumerated (eg. Gastrocnemius for the proximal third, soleus for the middle third, free tissue transfers or distally based flaps being reserved for the lower third of the leg). Although this traditional method can be useful, the surgeons must decide what is the optimal technique for the particular defect, not necessarily the most expeditious.

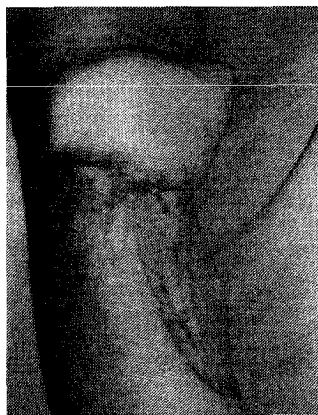


Fig 1. Defect over anterior aspect knee covered with Superiorly based fasciocutaneous flap. Donor area was skin grafted.

### I. SOFT TISSUE COVERAGE OF THE LEG DEFECTS

The time honoured concept of dividing the lower leg into three parts and deciding the type of pedicled flap required, remains useful, but must be subordinated by a more functional and aesthetic evaluation of the wound.

#### A) Skin grafts

Skin grafts are applicable only if there is a

healthy vascular recipient bed or if the periosteum over the bone is intact.

#### B) Skin flaps

Local skin flaps like transposition, rotation and local advancement flaps are suitable only for small defects. Islanded skin flap from dorsum of foot (based on dorsalis pedis vessels) may be used for defects around ankle joint including over malleoli and tendoachilles. Distant skin flaps like cross leg flap, abdominal tube pedicle flap and jump flap have become almost obsolete as they are staged procedures and are indicated for larger defects.

#### C) Fasciocutaneous flaps

Fasciocutaneous (FC) flaps (Fig 1) have been well investigated and tried out in the leg defect. As early as in 1901, Pouteau<sup>5</sup> reported the use of fasciocutaneous flaps in the lower leg. Taylor's work on the blood supply to the skin demonstrated that in the trunk it is usually musculocutaneous and in the limbs fasciocutaneous in nature. Ponten<sup>5</sup> had shown that the flaps in the leg can measure 8cm x 18cm and can be raised in a single stage without necrosis if the deep fascia is included. FC flap may be used locally in the ipsilateral limb or distally as a cross leg FC flap.

The blood supply to fasciocutaneous flaps can be from three sources<sup>6</sup>.

- 1) Musculocutaneous perforators: For example via gastrocnemius
- 2) Axial vessels: Sphenous artery and superficial sural arteries
- 3) Septocutaneous perforators: For each of anterior tibial, posterior vessels tibial and peroneal vessels

Numerous authors have attempted to study the location of septocutaneous perforators in relation to bony landmarks and leg lengths (Table 1).

#### Advantages of FC flaps

- 1) One stage procedure
- 2) Simple to execute
- 3) Gives a stable cover
- 4) If required, a portion of the flap can be deepethelized to obliterate a cavity
- 5) The flap can be islanded

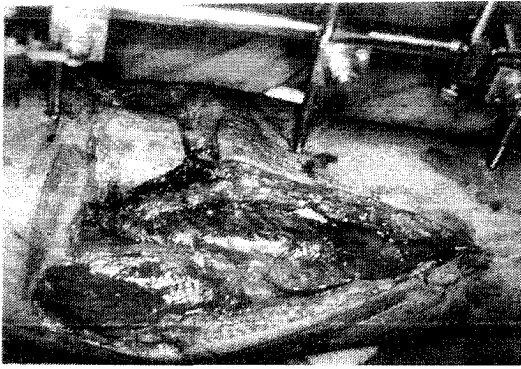


Fig 2a. Grade III compound fracture of upper 1/3 of tibia with exposed bone

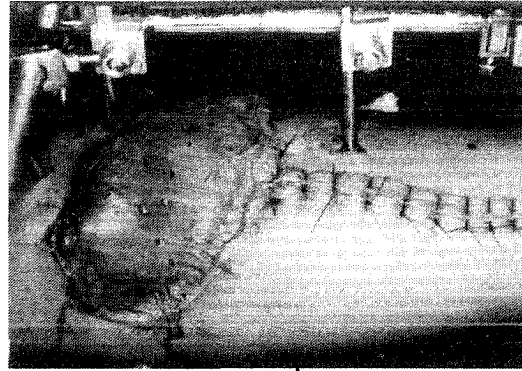


Fig 2b. Same patient treated with gastrocnemius muscle flaps. The exposed muscle surface was covered by skin graft

Table 1. Location of Septocutaneous perforators<sup>6,7</sup>

Vessels Location ↓	→	Posterior Tibial (Distance from MM*)	Peroneal Distance from LM* or FH*)	Anterior tibial
N 1	→	4.5cm.	4 -10cm (LM)	2-4cm from the origin of
N 2	→	6.0cm.	10 - 13cm** (LM)	Anterior tibial artery
N 3	→	9 - 12cm**	15 - 20cm** (LM)	
N 4	→	17 - 19cm**	5 - 6cm (FH)	
N 5	→	22 -24cm**		

\* LM = Lateral malleolus, FH = Fibular head, MM = Medial malleolus,

\*\* Constant locations of fasciocutaneous vessels.

### Disadvantages of FC flaps

- 1) Donor site needs to be skin grafted,
- 2) Unlike muscle flap, not suitable for filling infected cavities.

### Selection of fasciocutaneous flaps for leg defects

#### a) Knee and upper third leg

Proximally based fasciocutaneous flap based on the perforators of the post tibial, anterior tibial<sup>5,6,7</sup> or peroneal artery<sup>5,6</sup>

#### b) Middle third leg

Proximally based flaps on the posterior tibial or peroneal perforators<sup>5,6</sup> or a distally based flap on the lower posterior tibial perforators<sup>8</sup>.

#### c) Lower third leg

Distally based or cross leg fasciocutaneous flap may be used

- Flaps based on Lower perforators of the post tibial and peroneal arteries<sup>8,9</sup>
- Reverse sural artery flap<sup>10,11</sup>
- Posterolateral malleolar flap<sup>12</sup>
- Distally based fasciocutaneous flap

#### D) Adipofascial flaps

Adipofascial flaps have become extremely popular in the last decade in the reconstruction of lower leg defects. Adipofascial flaps are like fasciocutaneous flaps, as the vascular basis is same in both flaps. Gumener<sup>13</sup> described distally based fasciosubcutaneous flap to recon-

struct soft tissue defects of lower leg and foot. Lin et al<sup>14</sup> popularized the distally based medial adipofascial flaps to cover the exposed bones in the lower leg. These flaps are ideal for reconstruction of composite defects around the lower leg and ankle. Flaps are based on the posterior tibial, peroneal, anterior tibial vessels and their perforators. The flap once placed over the defect always needs to be covered with skin graft.

The basic advantage of adipofascial flap over fasciocutaneous flaps is that it carries least donor site morbidity as the donor site can be closed primarily.

#### **E) Muscle and musculocutaneous flaps**

In 1981 Mathes and Nahai<sup>15,16</sup> described the classification and clinical application of muscle and myocutaneous flaps. In the lower extremity, local (Gastrocnemius<sup>17,18,19</sup>, Soleus<sup>20</sup>) or distal (as microvascular transfer of gracilis<sup>21</sup>, Latissimus dorsi<sup>22,23,24,25</sup> rectus abdominis<sup>26</sup> muscle or musculocutaneous) flaps are available (Fig 2a, 2b).

The muscles useful for coverage of post traumatic leg defects and the region where their use is recommended include the following:

#### *Proximal third leg defects*

- Gastrocnemius<sup>17,18</sup>
- Skin fascial gastrocnemius

#### *Middle third leg defects*

- Soleus<sup>20</sup>
- Flexor digitorum longus<sup>15</sup>
- Peroneus longus<sup>15</sup>
- Tibialis anterior<sup>15</sup>
- Extensor digitorum longus<sup>15,16</sup>

#### *Distal third leg defects*

- Soleus<sup>20</sup>
- Tibialis anterior<sup>16</sup>
- Extensor hallucis longus<sup>16</sup>
- Peroneus brevis<sup>16</sup>

#### **F) Free flaps**

In 1973, Daniel and Taylor<sup>27,28</sup> reported the free transfer of groin skin and subcutaneous tissue by use of microvascular anastomoses. commonly used free fasciocutaneous flaps are radial artery forearm flap<sup>29</sup>, dorsalis pedis flap<sup>30</sup>, scapular<sup>31</sup>, parascapular<sup>32</sup>, lateral arm flap<sup>33</sup>, and posterior calf fasciocutaneous flap<sup>34</sup>. Muscle and myocutaneous free flaps commonly used for lower limb reconstruction are latissimus dorsi (Fig 3,4) gracilis<sup>21</sup>, tensor fascia lata<sup>35,36</sup> and rectus abdominis<sup>26</sup> (Fig 5) flaps.

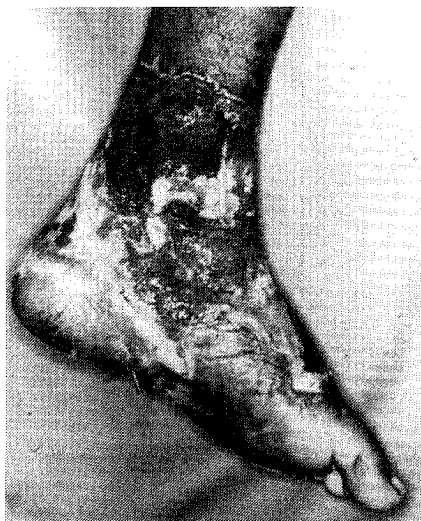

Fig 3a. Post traumatic defect over ankle and foot with exposed bone and joint.

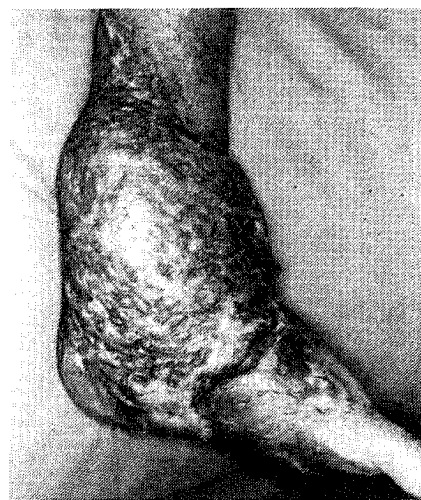

Fig 3b. The ankle defect covered with free latissimus dorsi muscle. The exposed muscle was covered by split skin graft.

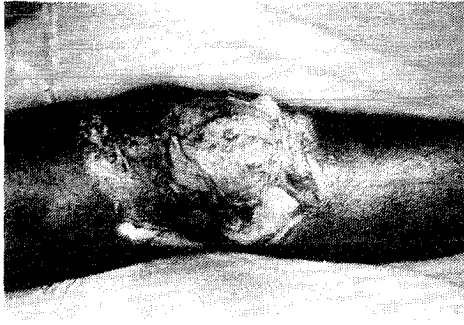

Fig 4a. Defect over anterior lateral aspects of knee with exposed joint following high voltage electrical injury.

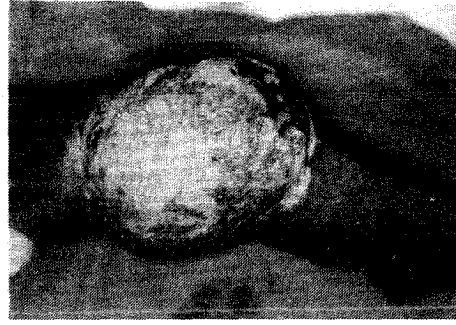

Fig 4b. The knee defect covered with latissimus dorsi muscle flap. The exposed muscle surface was covered with split skin graft.

Composite osteocutaneous free flaps<sup>37</sup> used for one stage reconstruction are radial artery osteocutaneous flap, fibula flap<sup>37</sup> and deep circumflex osteocutaneous free flap<sup>37</sup>. It is usually the Grade IIIb fractures of the legs, and the avulsion and crush injuries of the foot that need free flap cover. The basic objectives in these situations are:

- a) Good and early healing of bone
- b) Good movement of contiguous joints
- c) An aesthetically acceptable stable cover

## II. SOFT TISSUE COVERAGE OF THE FOOT DEFECTS

The unique anatomic and functional characteristics of the foot merit special consideration.

It is convenient to divide the foot in to the following regions:

1. Malleoli, achilles tendon and nonweight bearing posterior heel
2. The heel and mid plantar area
3. Distal plantar area
4. Dorsum of the foot

The choice of the procedure for soft tissue coverage largely depends on flaps available in that area and whether or not the area is weight bearing portion of the foot. To some extent it depends on factors like availability of trained personnel, facilities and overall general picture (general condition, age, other medical illness) of the patient.

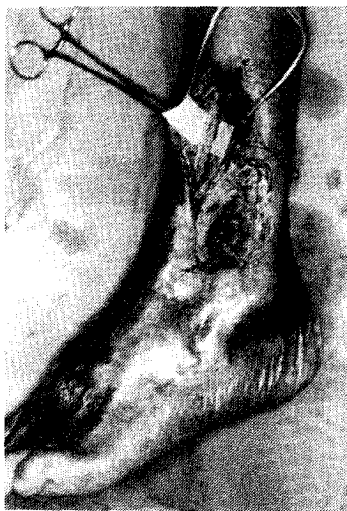

Fig 5a. Supramalleolar defect over the lateral aspect of leg with a cavity in the exposed bone.

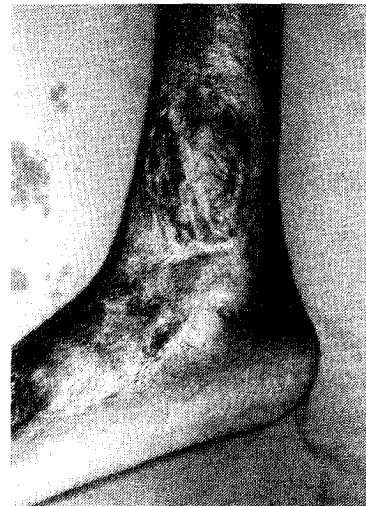

Fig 5b. The cavity was filled with free transverse abdominis muscle flap. The exposed muscle surface was covered with split skin graft.

## Types of Foot Injuries

Type I - Limited soft tissue injury; tendon and bone not exposed.

Type II - Major soft tissue loss over non weight bearing area or distal weight bearing area with exposed/damaged tendons, bones or forefoot/toe(s) amputation(s).

Type III - Major soft tissue loss over/extending over proximal weight bearing portion of foot (heel and proximal sole) with or without fracture of calcanium and talus.

The ideal reconstruction provides sensibility, stability and satisfactory appearance.

### Options for wound cover

#### A) Skin grafts

Skin graft is the method of choice when adequate soft tissue padding is present.

#### B) Skin flaps

Local skin flaps as rotation (Fig 6a, 6b), transposition or advancement flaps are suitable only for small defects. Axial innervated skin flaps are methods of choice for weight bearing areas<sup>38</sup>. Distant skin flaps as tube, cross leg, cross thigh or cross foot flaps are of only historical interest.

#### C) Fasciocutaneous flaps

For Larger defects, flaps that include the medial plantar artery either as axial pattern flap or fasciocutaneous flap are recommended<sup>38,39</sup>. The entire non weight bearing portion of the midfoot can be raised to reconstruct the soft tissue defects over heel.

The Lateral calcaneal artery fasciocutaneous flap can be employed either as a transposition flap or as an island flap to cover the achilles

tendon and posterior non weight bearing heel.

#### D) Muscle and myocutaneous flaps

Flexor digitorum brevis muscle<sup>38</sup> and skin graft is an alternate flap for heel coverage. Abductor hallucis muscle with skin graft is an alternate flap for defect below medial malleolus<sup>38</sup>.

Abductor digiti minimi muscle<sup>38</sup> with skin graft is used for defects below lateral malleolus.

#### E) Free Flaps

Free tissue transplantation can cover extensive defects of foot when a local innervated flap is not available.

The temporoparietal fascia free flap<sup>40</sup> provides thin cover over the achilles tendon. Other free fasciocutaneous flaps commonly employed are radial artery<sup>29</sup> forearm flap and dorsalis pedis<sup>30</sup> flap. Small free muscle flaps<sup>41</sup> are ideal for coverage of the malleoli; they are more reliable and involve less morbidity than attempts to stretch a local muscle flap from the sole of the foot to reach the malleoli.

It has been demonstrated that stable coverage is obtained with skin grafted free muscle flaps<sup>41</sup> (gracilis, latissimus dorsi) on the sole of the foot. The more mobile tissue that accompanies a muscutocutaneous or fasciocutaneous free flaps makes the skin island less stable and causes more problems than a skin grafted free muscle flap.

## Conclusion

First and foremost goal in the management of limb injuries should be to check and establish satisfactory circulation. Then, having assessed the defect in the context of the individual patient, the surgeon must project what the ulti-

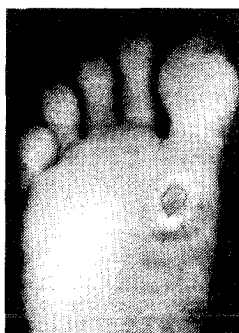

Fig 6a. Chronic ulcer over sole

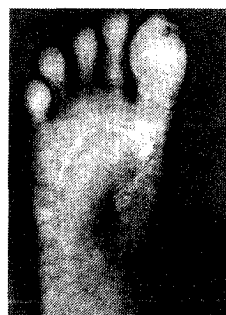


Fig 6b. Ulcer was excised and covered with a rotation flap.

mate function of that extremity will be and plan the sequence of therapeutic steps to yield that result. If such planning does not begin at the initial evaluation, multiple poorly organised procedures may result in an amputation that could have been performed safely after the patient was first seen, sparing the patient (and the surgeon) considerable frustration. The classic reconstruction ladder is useful but is not the sole criterion for planning a reconstructive procedures. A sensate flap for weight bearing areas is desirable.

## References

1. Thorne CHM, Siebert JW, Grotting JC. Reconstructive Surgery of the lower extremity. McCarthy JG (ed); Plastic Surgery; p 4029-4092. Philadelphia: W.B. Saunders Company 1990.
2. Godina M. Early microsurgical reconstruction of complex trauma of the extremities. *Plast Reconstr Surg* 1986;78:285-292.
3. Gustilo RB, Anderson JT. Prevention of infection in the treatment of one thousand and twenty five open fractures of long bones: Retrospective and prospective analysis. *J Bone Joint Surg* 1976; 58:453-458.
4. Gustilo RB, Mendoza RM, William DN. Problems in the management of type III open fractures: A new classification of type III open fractures. *J Trauma* 1984;24:742-746.
5. Ponten B. The fasciocutaneous flaps: its use in soft tissue defects of the leg. *Brit J Plast Surg* 1981;34:215-220.
6. Bhattacharya V. Fasciocutaneous flaps, plastic and Reconstructive Surgery: Current trends (proceedings of CME programme at National conference of APSI, Calcutta) 1998; p 36-40.
7. Recalde RJF, Gilbert A, Masquelct A et al. Anterior tibial artery flap: Anatomic study and clinical application. *Plast Reconstr Surg* 1987;79:396-404.
8. Barclay TL, Cardoso E, Sharpe DT, Crockett DJ. Repair of lower leg injuries with fasciocutaneous flaps. *Brit J Plast Surg* 1982;35:127-132.
9. Amarante J, Costa H, Reis J, Soares R. A new distally based Fasciocutaneous flap of the leg. *Brit J Plast Surg* 1986;39: 338-340.
10. Jobe fix RL, Vaseonez L. Fasciocutaneous flaps in Reconstruction of lower extremity. *Clinics in Plastic Surgery* 1991;18:571-582.
11. Yilmaz M, Karatas O, Barutcu A. The distally based superficial sural artery island flap: clinical experience and modifications. *Plast Reconstr Surg* 1998;102:2358-2367.
12. Masquelet AC, Beveridge J, Romana C, Gerber C. The lateral supramalleolar flap. *Plast Reconstr Surg* 1988;81:74-81.
13. Lin SD, Lai CS, Trai CC et al. Clinical application of the distally based medial adipofascial flap for soft tissue defects on the lower half of the leg. *J Trauma* 1995;38:623-629.
14. Lin SD, Lai CS, Chouck et al. Distally based posterior tibial arterial adipofascial flap. *Brit J plast surg* 1992;45:284-287.
15. Mathes SJ, Nahai F. Clinical applications of muscle and musculocutaneous flaps. Lower extremity Reconstruction; p 539-580. St. Louis: CV Mobsy 1982.
16. Mathes SJ, Nahai F. Muscle flap transposition with function preservation: Technical and clinical considerations. *Plast Reconstr Surg* 1980;66:242-248.
17. Ger R. The technique of muscle transposition and the operative treatment of traumatic and ulcerative lesions of the leg. *J Trauma* 1971;2:502-510.
18. Pers M, Medgyesi S. Pedicle flaps and their applications in the surgery of repair. *Brit J Plast Surg* 1973;26:313 -321.
19. Feldman JJ, Cohen BE, May JW. Medial gastrocnemius myocutaneous flap. *Plast Reconstr Surg* 1978;61:531-539.
20. Tobin GR. Hemisoleus and reversed hemi soleus flaps. *Plast Reconstr Surg* 1985;76:87-93.
21. Harii K, Ohmori K, Sekiguchi J. The free musculocutaneous flap. *Plast Reconstr Surg* 1976;57:294-303.
22. Bostwick J. Latissimus dorsi flap: current applications *Ann Plast Surg* 1982;9:377-383.

23. Baily BN, Godfrey AM. Latissimus dorsi muscle free flaps. *Brit J Plast Surg* 1982; 38: 47-52.
24. Maxwell G P, Stueber K, Hooper JE. Free latissimus dorsi myocutaneous flap. *Plast Reconstr Surg* 1978;62:462-466.
25. Elliot LF, Rafel B, Wade J. Segmental latissimus dorsi free flap: clinical applications. *Ann Plast Surg* 1989;91:103-112.
26. Pennington DG, Lai MF, Pelly AD. The rectus abdominis myocutaneous free flap. *Brit J Plast Surg* 1980;33:277-282.
27. Taylor GI, Daniel R K. The anatomy of several free flap donor sites. *Plast Reconstr Surg* 1975;56:243-251.
28. Daniel RK, Taylor GI. Distant transfer of an island flap by microvascular anastomosis. *Plast Reconstr Surg* 1973;52:111-119.
29. Goufan Y. Forearm skin flap transplantation (in chinese). *National Medical Journal of China* 1981;61:139-143.
30. Man D, Ackland R. The microarterial anatomy of dorsalis pedis flap and it's clinical applications. *Plast Reconstr Surg* 1980; 65:419-424.
31. Gilbert A, Teot L. The free scapular flap. *Plast Reconstr Surg* 1982;69:601-605.
32. Nassif T, Vidal L, Bovet JL, Baudet J. The parascapular flap: a new cutaneous microsurgical free flap. *Plast Reconstr Surg* 1982;69:591-594.
33. Katsaros J, Schusterman M, Beppu M etal. The lateral upperarm flap: anatomy and clinical applications. *Ann Plast Surg* 1984; 12:489-493.
34. Walton R L, Bunkis J. Posterior calf fascio cutaneous free flaps. *Plast Reconstr Surg* 1984;74:76-85.
35. Back SM. Two new cutaneous free flaps: the medial and lateral thigh flaps. *Plast Reconstr Surg* 1983;71:354-363.
36. Hill HL, Nahai F, Vasconez LO. Tensor fascia lata myocutaneous free flap. *Plast Reconstr Surg* 1978; 61:517-521.
37. Taylor GI. Composite tissue transfer of the lower limb. In: Jackson IT, Sommerland P (eds); *Recent advances in Plastic Surg*; p 83-109. London: Churchill livingstone 1985.
38. Hidalgo DA, Shaw WW. Reconstruction of foot injures. *Clin Plast Surg* 1986;13:663-671.
39. Colen LB, Buncke HJ. Neurovascular Island flap from the plantar vessels and nerves for foot reconstruction. *Ann Plast Surg* 1984; 12:327-331.
40. Stevenson TR, Mathes SJ. Management of foot injury with free muscle flaps. *Plast Reconstr Surg* 1986;78:665-669.
41. Upton J, Rogers C, Durhamsmith G, Swartz WM. Clinical application of temporoparietal flaps. *J Hand Surg* 1986;11:475-483.

#### Authors

Pramod Kumar MS,MCh,DNB. Professor  
 KG Bhaskara MS,MCh,DNB. Asst. Professor  
 Ravi Chittoria MS, DLB, MCh, Asst. Professor  
 Paul C Thomas MS,FRCS,MCh. Asst.Professor

#### Corresponding Author

Pramod Kumar  
 Professor and Head  
 Department of Plastic Surgery and Burns  
 Kasturba Medical College  
 Manipal - 576 119, Karnataka, India  
 Tel: (+91) (0) (8252) 71201 Ext 2135(O) 2286(R)  
 Fax: (+91) (0) (8252) 70062  
 Email: info@mahe.ernet.in